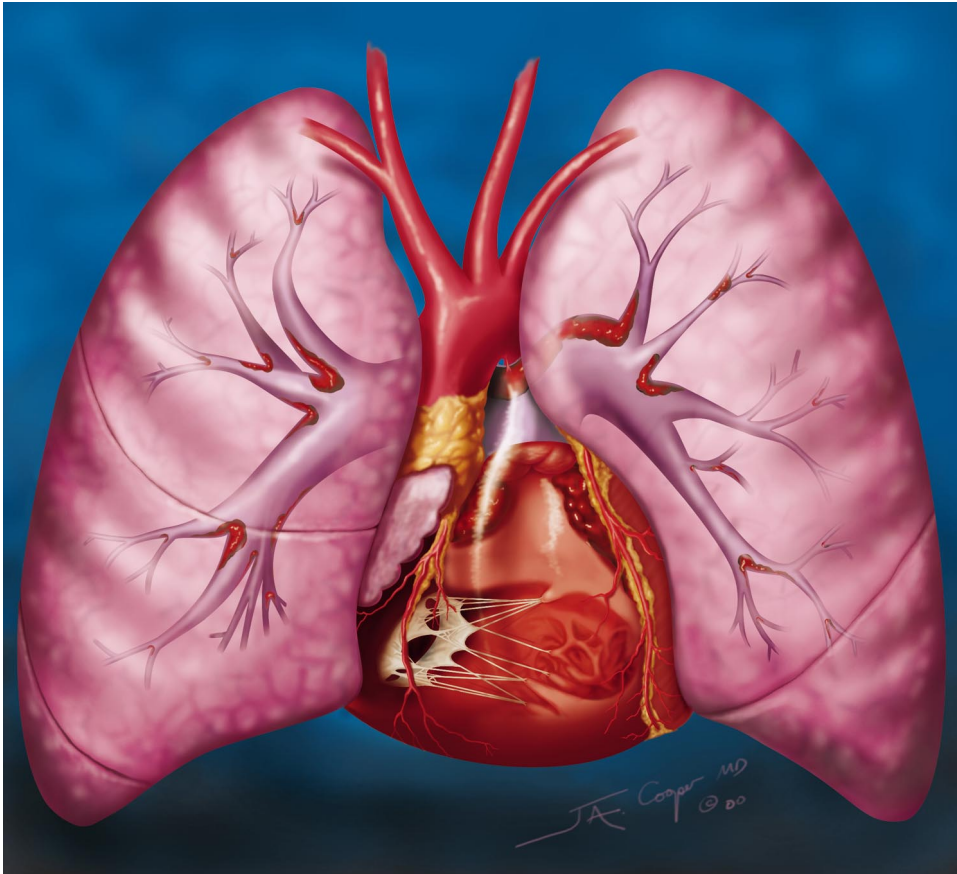


# Illuminations



## Chronic Pulmonary Embolism

Drawing illustrates the involvement of the lungs and heart by chronic pulmonary embolism. Enlarged pulmonary arteries, with distal pruning, and an enlarged right ventricle are seen.

**Medical illustration by James A. Cooper, MD, Radiology Medical Group, San Diego, California** ([jcooper3@san.rr.com](mailto:jcooper3@san.rr.com); [www.cooperspective.com](http://www.cooperspective.com))