Note: This copy is for your personal, non-commercial use only. To order presentation-ready copies for distribution to your colleagues or clients, contact us at *www.rsna.org/rsnarights*.

Intravenous Contrast Medium Administration and Scan Timing at CT: Considerations and Approaches[1]

Kyongtae T. Bae, MD, PhD

The continuing advances in computed tomographic (CT) technology in the past decades have provided ongoing opportunities to improve CT image quality and clinical practice and discover new clinical CT imaging applications. New CT technology, however, has introduced new challenges in clinical radiology practice. One of the challenges is with intravenous contrast medium administration and scan timing. In this article, contrast medium pharmacokinetics and patient, contrast medium, and CT scanning factors associated with contrast enhancement and scan timing are presented and discussed. Published data from clinical studies of contrast medium and physiology are reviewed and interpreted. Computer simulation data are analyzed to provide an in-depth analysis of various factors associated with contrast enhancement and scan timing. On the basis of basic principles and analysis of the factors, clinical considerations and modifications to protocol design that are necessary to optimize contrast enhancement for common clinical CT applications are proposed.

© RSNA, 2010

Supplemental material: *http://radiology.rsna.org/lookup/suppl/doi:10.1148/radiol.10090908/-/DC1*

[1] From the Department of Radiology, University of Pittsburgh School of Medicine, 3362 Fifth Ave, Pittsburgh, PA 15213. Received May 28, 2009; revision requested July 31; revision received September 2; accepted November 6; final version accepted December 10. Supported by an RSNA Research Resident Grant. **Address correspondence to** the author (e-mail: *baek@upmc.edu*).

© RSNA, 2010

Since its advent, there have been continuing advances in computed tomographic (CT) technology that have provided us with ongoing opportunities to improve the image quality and our clinical practice. In particular, during the past decade, the dramatically improved spatial and temporal resolution achievable at multidetector CT has allowed previously highly technically demanding clinical applications such as CT angiography and cardiac CT to be practiced routinely. Conventional catheter-based diagnostic angiographic examinations have been largely replaced with CT angiography. In many institutions, multidetector CT urography is performed instead of conventional intravenous urography. Functional CT imaging such as brain CT perfusion has become a routine clinical protocol.

New CT technology, however, has introduced new challenges in our practice. We must decide how best to standardize protocols, manage radiation dose, manage large image data sets, and ensure diagnostic efficacy. The opportunity of maximizing clinical benefit while overcoming technical challenges is equally applicable to the use of intravenous contrast medium. For instance, although multidetector CT allows more efficient and flexible use of contrast medium than single-detector CT, to fully reap the benefits of multidetector CT, certain technical challenges involving scan timing relative to maximum contrast enhancement and optimal contrast material delivery must be met.

While CT technology has evolved, the practice of CT intravenous contrast media administration has been continually debated and updated. The advent of new CT technology accompanied with its newly added technical complexity often frustrates users who, using old contrast material and scanning protocols, discover they cannot achieve a desired image quality and subsequently force a change in practice. For example, more than a decade ago, in the era of newly introduced spiral CT, a State of the Art article was published in *Radiology* (1) to address the required protocol revisions and considerations in contrast material administration for the liver. Since the publication of that article, multidetector CT technology has been adopted and presents new technical challenges. The new challenges and new CT clinical applications afforded by multidetector CT require us to reevaluate our current practice of contrast medium administration and scan timing. We are also obligated to improve our methods and explore new directions that will lead to enhanced diagnostic efficiency and improved patient care.

In this article, the current status of intravenous contrast medium administration and scan timing at CT is addressed. Contrast medium pharmacokinetics and factors of patient, contrast medium, and CT scanning associated with contrast enhancement and scan timing are presented and discussed. Published data from clinical studies of contrast medium and physiology are reviewed and interpreted. Computer simulation data are analyzed to provide an in-depth analysis of various factors associated with contrast enhancement and scan timing. On the basis of basic principles and analysis of the factors, we propose clinical considerations and modifications to protocol design that are necessary to optimize contrast enhancement for common clinical CT applications. A new paradigm for future technologic development to improve an automation of contrast medium administration is also presented.

Essentials

- Use of lower CT tube voltages (in peak kilovolts) yields stronger contrast enhancement for a given injection of contrast medium.
- The most important patient-related factor affecting the magnitude of vascular and parenchymal contrast enhancement is body weight.
- Injection duration is the most important injection-related factor affecting CT scan timing; scan delays should be determined with consideration of injection duration by using injection completion (not injection initiation) as the reference time variable.
- Contrast material arrival time should not be simply assumed to serve as the scan delay, particularly for fast multidetector CT; it should be used as a means of individualizing the scan delay: scan delay = contrast material arrival time + posttrigger delay (or diagnostic delay).
- We propose an empiric scheme for determining the scan delay (T_{DELAY}) calculated to be equal to the estimated peak enhancement time (T_{PEAK}) minus half the scan duration (T_{SD}): $T_{DELAY} = T_{PEAK} - (1/2) \cdot T_{SD}$.

Contrast Medium Pharmacokinetics and Mathematical Modeling

CT Attenuation, Iodine, and X-ray Energy

Iodine in a target organ or blood plasma causes greater absorption and scattering of x-ray radiation. This results in an increase in CT attenuation and contrast medium enhancement on the CT image. The degree of CT contrast enhancement is directly related to the amount of iodine within the system and the level of x-ray energy (ie, tube voltage). Contrast enhancement increases proportionally with iodine concentration. For a given voltage, the proportionality of contrast enhancement to iodine concentration is near constant (2) (Fig 1). For example, at 120 kVp, an increase in iodine concentration by 1 mg of iodine per milliliter yielded an approximately 26 HU proportional increase in contrast enhancement. At a lower voltage, however, this proportionality increases and results in stronger contrast enhancement per iodine concentration. The relationship between contrast enhancement and iodine concentration will also vary among scanners but is typically in the range of 25–30 HU per milligram of iodine per milliliter at 100–120 kVp.

Published online
10.1148/radiol.10090908

Radiology 2010; 256:32–61

Author has patent agreements with Covidien and Medrad.

Figure 1

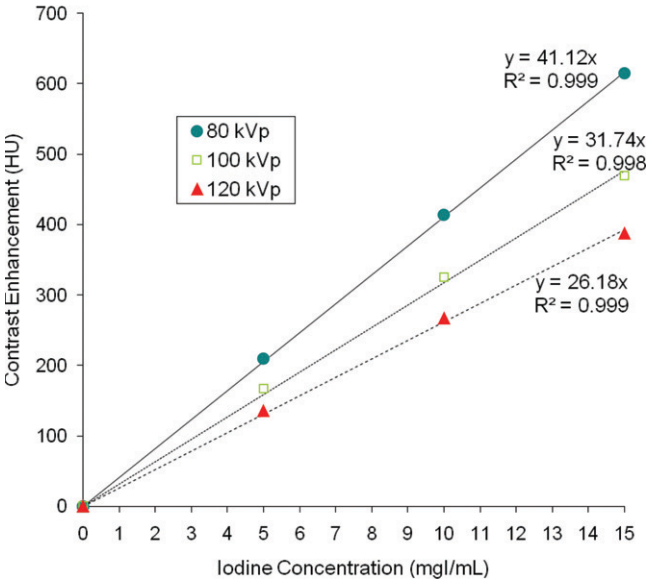

Figure 1: Graph shows the relationship between iodine concentration and CT enhancement at three voltage settings. For a given voltage, the proportionality of contrast enhancement to iodine concentration is near constant. An increase in concentration by 1 mg of iodine per milliliter yields contrast enhancement of 41.12 HU at 80 kVp, 31.74 HU at 100 kVp, and 26.18 HU at 120 kVp. Thus, use of lower voltage results in stronger contrast enhancement per iodine concentration.

Figure 2

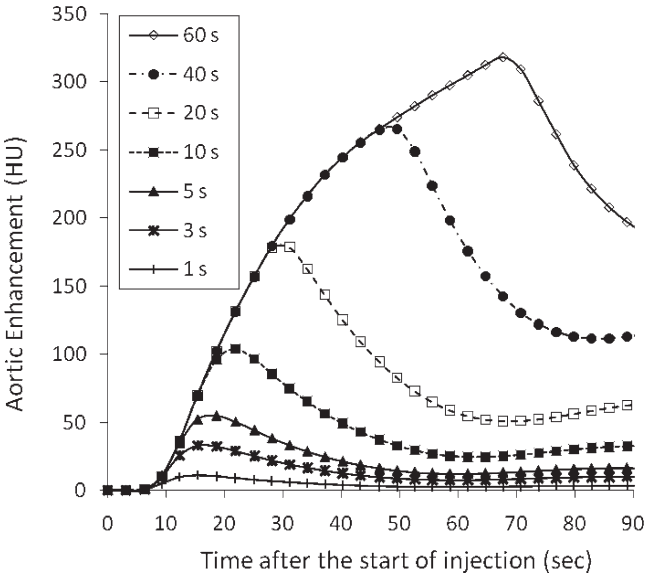

Figure 2: Simulated abdominal aortic enhancement curves based on a hypothetical adult male (30 years old; weight, 70 kg; height, 170 cm) subjected to varying injection durations (1, 3, 5, 10, 20, 40, and 60 seconds) of contrast medium (350 mg of iodine per milliliter) injected at 3 mL/sec. For a short injection (<15 seconds), the contribution of recirculated contrast medium to peak aortic enhancement is likely small. The aortic peak time-enhancement curve is similar to a Gaussian curve (a rapid initial rise followed by a short peak and rapid decline). However, as injection duration increases, new contrast media and recirculated contrast media already in the body mix and accumulate, resulting in a sloped aortic enhancement that rises steadily over time. Hence, an aortic enhancement profile for a long injection duration shows a rapid initial rise, gradual increase, peak, and gradual decline.

Use of low voltages such as 100 and 80 kVp results in higher CT attenuation than 120 kVp, because the x-ray output energy at these low voltages is closer to the iodine k edge of 33 keV (3,4); iodine concentration of 1 mg of iodine per milliliter corresponds to contrast enhancement of approximately 30 HU for 100 kVp and 40 HU for 80 kVp (2,5) (Fig 1). The increased attenuation per unit of iodine concentration due to low voltage helps improve vascular and parenchymal enhancement while simultaneously reducing radiation absorption as long as there is no substantial beam scatter or image degradation due to large soft-tissue or bone structures along the course of the x-ray beam (6,7). In particular, the benefits of the use of lower voltages have been recognized at pediatric CT (8–10) and with some adult CT applications (11,12). The amount of contrast medium required is substantially less with a tube voltage of 80 kVp than with that of 120 kVp to achieve an equivalent degree of contrast enhancement (12). Furthermore, this energy-dependent CT iodine-attenuation relationship can be used at dual-energy CT to differentiate iodine from high-attenuation tissues such as bone (13) and renal calculi (14–16). One must be aware, however, that when a lower tube voltage protocol is used without an increase in tube current, the image noise will increase, especially for larger patients.

Key point.—Use of lower CT tube voltages yields stronger contrast enhancement for a given injection of contrast medium, which may potentially help reduce the amount of contrast medium required to achieve the same degree of contrast enhancement.

Distribution of Concentration Medium within the Body

After peripheral intravenous injection, contrast medium travels to the right heart, the pulmonary circulation, and the left heart before reaching the central arterial system. Its circulation throughout the body is regulated by the cardiovascular system. Contrast medium rapidly redistributes from the vascular to the interstitial spaces of the organs. Because iodinated contrast media consist of relatively small molecules that are highly diffusible, the transport of contrast media is predominantly "flow limited" and far less "diffusion limited." In a flow-limited process, the delivery of contrast medium through the circulatory system to an organ is a crucial determinant of contrast enhancement (2). Well-perfused organs such as the kidney, the spleen, and the liver show high contrast enhancement during the initial circulation (first pass) of contrast medium to the organs.

As contrast medium circulates in the body, it is diluted by the blood, and the bolus disperses as it moves downstream through the circulatory system. The effect of dilution is greater in organs

Figure 3

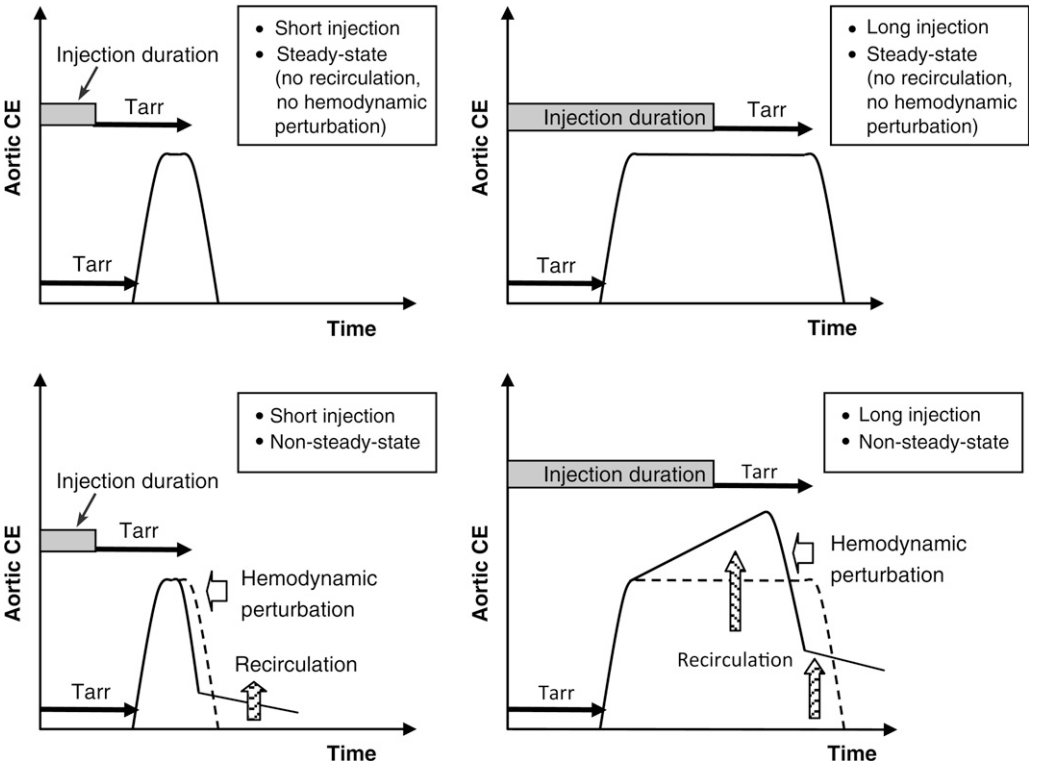

Figure 3: Time-enhancement curve diagrams illustrate the effect of the injection duration and recirculation on peak contrast enhancement. Top: In a theoretical physiologic model without recirculation or hemodynamic perturbation, aortic contrast enhancement *(CE)* would show a rapid rise and then a uniform steady-state plateau (a flat broad peak). The time to the end of the plateau enhancement corresponds to the sum of the injection duration plus contrast material arrival time *(Tarr)* (solid horizontal arrows). Bottom: In reality, however, a fast, large bolus of contrast medium affects and perturbs the hemodynamics of the cardiovascular system, particularly the slow peripheral venous blood flow. This will result in hastening contrast material arrival as the contrast material bolus increases. Because of recirculation (hatched vertical arrows) and hemodynamic perturbation (open horizontal arrows) effect, the steady-state plateau contrast enhancement cannot be sustained and becomes elevated and compressed, resulting in a higher and narrower peak contrast enhancement. The time to peak aortic enhancement becomes shorter than the sum of the injection duration plus contrast material arrival time.

more distal from the injection site (typically antecubital vein)—progressively broadened contrast enhancement profile with a more flattened peak. In addition, contrast material–enhanced blood recirculates and may contribute to the overall pattern of contrast enhancement achieved at CT imaging acquisition (2,17–19). For very long injections, the recirculation can even occur during the infusion of the contrast material. Recirculated contrast-enhanced blood does not reach a target organ simultaneously because of multiple circulatory pathways in the body. For example, blood in the cerebral circulation returns to the right heart and recirculates faster than blood in the portal circulation. The transit time for normal recirculation may range 15–40 seconds depending on circulatory paths (faster for shorter paths). The recirculated contrast medium is further diluted by intravascular and extracellular volume, and the bolus dispersion is largely governed by blood flow and tissue perfusion.

The fractional contribution of recirculation to the overall magnitude of enhancement depends on the duration of injection and the time course of enhancement. For a short injection (<15 seconds), the contribution of recirculated contrast medium to peak aortic enhancement is likely small. The aortic peak time-enhancement curve is similar to a Gaussian curve (a rapid initial rise followed by a short peak and rapid decline) (Fig 2). Conversely, when contrast medium is injected at a constant rate for a long injection, the new contrast media and the recirculated contrast media already in the body mix and accumulate, resulting in a more gradual increase in aortic enhancement over time. A typical aortic enhancement profile for long-injection duration then consists of a rapid initial rise, gradual increase, peak, and gradual decline. The contribution of recirculation to peak arterial enhancement is likely 10%–20% for a typical clinical injection (>15 seconds). In a theoretical physiologic model with no recirculation contribution, aortic contrast enhancement

Figure 4

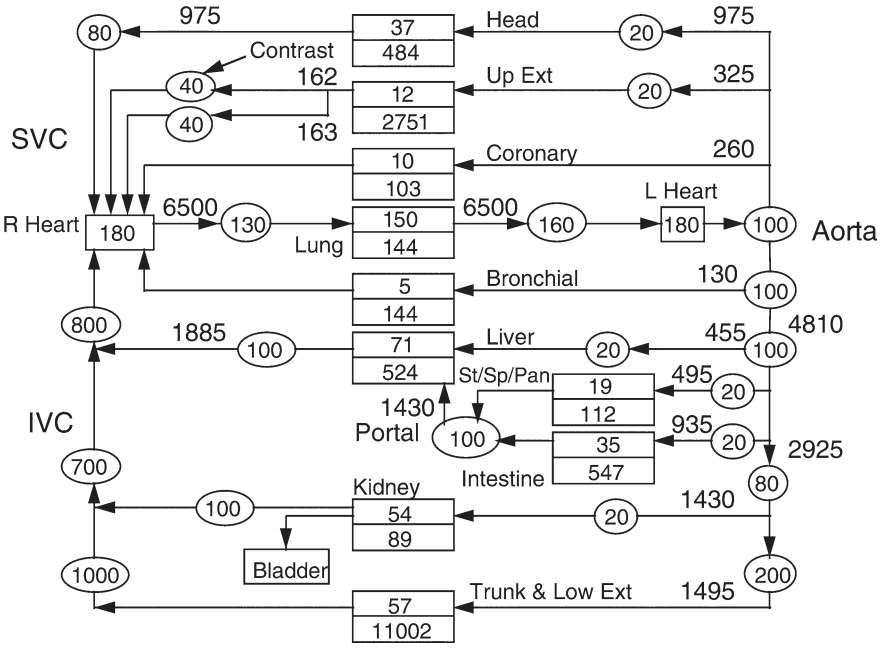

Figure 4: Physiologically based pharmacokinetic model used to simulate contrast enhancement in various organs. Contrast medium is introduced in the antecubital site, mixed in the right heart *(R Heart)*, distributed throughout the body, and excreted by the kidneys according to the glomerular filtration rate. Regional blood flow is expressed according to the magnitude (in milliliters per minute) and direction of the flow. A blood vessel is represented by a circle surrounding a number, which represents its volume (in milliliters). Each organ is described as a box split into two subcompartments, with the upper number denoting capillary volume and the lower number denoting extracellular fluid volume. *Ext* = extremities, *IVC* = inferior vena cava, *L Heart* = left heart, *Low* = lower, *St/Sp/Pan* = stomach, spleen, pancreas, *SVC* = superior vena cava, *Up* = upper. (Adapted and reprinted, with permission, from reference 2.)

would show a rapid rise and then a uniform steady-state plateau (a flat broad peak) as the rate of contrast medium clearance from the central blood compartment is equilibrated to the infusion rate of contrast medium (18) (Fig 3). The time to the end of the plateau corresponds to the sum of the injection duration plus contrast material arrival time.

While the circulation of contrast medium throughout the body is mainly governed by hemodynamic physiology, the injected contrast medium in turn may affect and perturb the hemodynamics of the cardiovascular system. A fast, large bolus of contrast medium injected with a power injector would accelerate the slow intrinsic peripheral venous blood flow. With increased peripheral venous flow, contrast medium will be delivered to the central blood compartment faster with a shorter delay. The hemodynamic perturbation effect is greater with a larger volume and a faster injection rate of contrast medium. Because of recirculation and the hemodynamic perturbation effect, the steady-state plateau contrast enhancement cannot be sustained and becomes elevated and compressed. This will result in a higher and narrower peak contrast enhancement and shortening of the contrast material arrival and peak contrast enhancement times (Fig 3). Consequently, the time to peak aortic enhancement becomes shorter than the sum of the injection duration plus contrast material arrival time.

Key point.—While the circulation of contrast medium throughout the body is mainly governed by hemodynamic physiology, the injected contrast medium in turn may affect and perturb the hemodynamics of the cardiovascular system.

Mathematical Modeling of Contrast Enhancement in Humans

The large body of physiologic data available for the human cardiovascular system allows us to estimate the propagation and distribution of contrast medium throughout the human body. The distribution of contrast medium in an organ depends on the perfusion rate, tissue volume, tissue composition of the organ and permeabilities throughout the organ microvasculature and cellular interfaces. When contrast medium is considered a pharmaceutical injected intravenously, its in vivo distribution can be predicted by using mathematical techniques developed in pharmacokinetics. A physiologically based computer model of whole-body contrast enhancement was generated (2) (Fig 4). This model was validated with clinical data (2) and different mechanical flow phantom experiments (20–23).

Computer-modeling of the human cardiovascular system has several potential clinical applications. It can be used to optimize the scan timing and the amount of contrast medium for a given patient's physical characteristics and clinical condition (2,20,21,24–30). A mathematical model of contrast material distribution may provide a theoretical basis for developing an automated system in which the CT scanner and injector communicate and intelligently assist the technologist and radiologist to ensure optimal contrast enhancement. Another way in which the computer model can be used is to predict an input injection pattern for a given output contrast enhancement profile (ie, solving the inverse problem). Thus, the model can assist us to design and compute the injection protocol required to yield a desired enhancement curve (more discussion in the injection bolus shaping section) (31,32). Finally, modeling and prediction expand our understanding of contrast medium pharmacokinetics by allowing us to simulate organ-specific contrast enhancement in a patient with a specific body habitus subjected to different contrast medium injection protocols (18,22,28,33–36). The simulated time-enhancement curves

presented in this article to illustrate the effect of various contrast enhancement factors were generated by using the physiologically based computer model in Figure 4 (34).

Key point.—Computer-modeling of contrast enhancement may help characterize the effect of various factors and provide a theoretical basis for contrast enhancement optimization.

Figure 5

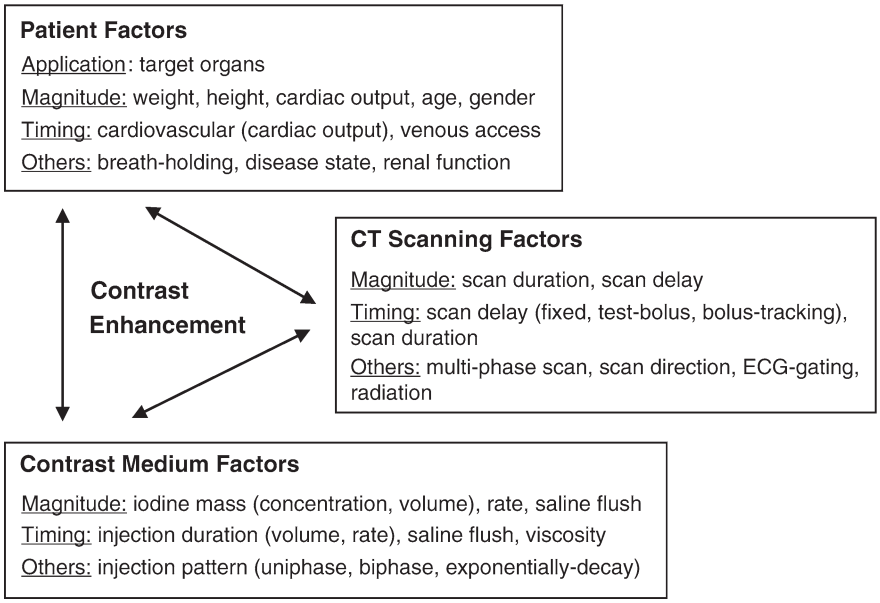

Figure 5: Factors involved in contrast medium enhancement. The factors can be divided into three categories: patient, contrast medium, and CT scan. In each category, the factors are further grouped according to affecting predominantly the magnitude or the timing of contrast enhancement. *ECG* = electrocardiographic.

Factors Affecting Contrast Enhancement and Scan Timing

Contrast enhancement at CT is affected by numerous interacting factors (1,2, 37–40). These factors may be divided into three categories: patient, contrast medium, and CT scanning (Fig 5). Contrast medium pharmacokinetics and contrast enhancement are determined solely by the patient and contrast medium factors and are independent from the CT scanning technique. Nevertheless, CT scanning factors play a critical role by allowing us to acquire contrast-enhanced images at a specific time point of contrast enhancement. The patient and contrast medium factors are highly interrelated, and all contribute to the distribution of contrast medium after injection and the resulting dynamics of contrast enhancement; some of the factors are more influential on the magnitude while others are more influential on the temporal pattern of contrast enhancement.

Patient Factors

The key patient-related factors affecting contrast enhancement are patient body size (weight and height) and cardiac

Figure 6

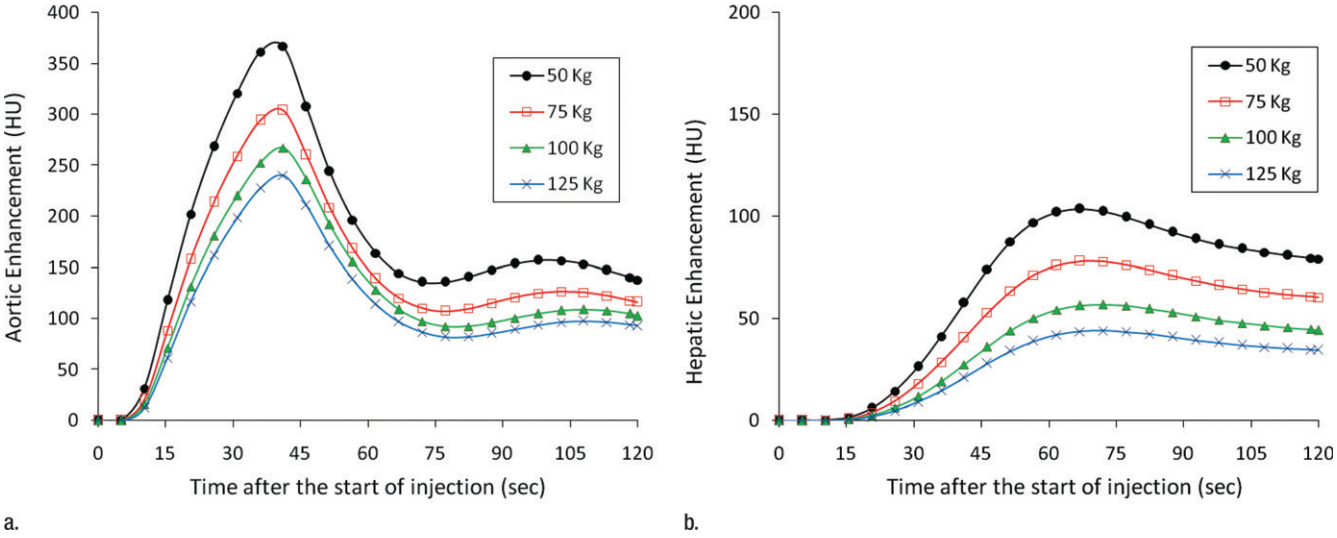

Figure 6: Simulated contrast enhancement curves of the **(a)** abdominal aorta and **(b)** liver based on a hypothetical adult male (30 years old; height, 170 cm) and varying body weights (50, 75, 100, and 125 kg) who underwent injection of 125 mL of contrast medium (350 mg of iodine per milliliter) at 4 mL/sec. Magnitudes of aortic and hepatic contrast enhancements are inversely proportional to body weight.

output (cardiovascular circulation time). Other patient factors that are important but considered to be less influential include age, sex, venous access, renal function, hepatic cirrhosis, portal hypertension, and various other pathologic conditions. Only limited data are available in the literature as for the effect of these seemingly less influential patient factors on contrast enhancement. Each patient factor and its effect on contrast enhancement are described in general in this section. Considerations associated with specific clinical multidetector CT applications are discussed in Appendix E1 (online).

Body Weight, Mass, Surface Area, and Mass Index

The most important patient-related factor affecting the magnitude of vascular and parenchymal contrast enhancement is body weight (35,40–43). Numerous studies have been conducted to investigate the effect of body weight on contrast enhancement (2,35, 41–53). This effect can be best described on the basis of the association of the body weight with the blood volume (Eqq [1, 2]). Because large patients have larger blood volumes than small patients, contrast medium administered into the blood compartment dilutes more in a large patient than in a small patient. The result is a reduced iodine concentration in the blood and lower contrast enhancement.

Blood volume and cardiac output are closely related to patient sex, weight (in kilograms), and height (in centimeters) in a regression formula which is based on the prediction of body surface area (54–56): for an adult male with weight (W) ranging from 45 to 141 kg (100 to 310 lbs) and height (H) ranging from 152 to 188 cm (60 to 74 inches), blood volume (BV) is estimated with the following:

$$\text{BV (mL)} = 23.6 \cdot H^{0.725} \cdot W^{0.425} - 1229. \quad (1)$$

For an adult female with weight (W) ranging from 36 to 132 kg (80 to 290 lbs) and height (H) ranging from 152 to 188 cm (60 to 74 inches), blood volume is estimated with the following:

$$\text{BV (mL)} = 24.8 \cdot H^{0.725} \cdot W^{0.425} - 1954. \quad (2)$$

For an adult female or male, cardiac output (CO) is estimated with the following:

$$\text{CO (mL/min)} = 25.3 \cdot H^{0.725} \cdot W^{0.425}. \quad (3)$$

For a given administration of contrast medium dose, the magnitude of contrast enhancement decreases proportionally with an increase in patient weight (Fig 6). Thus, when a consistent contrast enhancement is desired, the amount of iodine should be adjusted for the body weight. A large patient requires more iodine load than a small patient to achieve the same magnitude of enhancement.

The most commonly used scheme for adjusting the amount of iodine mass for the body weight is the use of a 1:1 linear scale (eg, doubling the iodine mass when the patient's body weight doubles) (42). This direct body-weight–based linearity may not, however, provide an accurate adjustment of the required contrast medium dose for body size, particularly in children and obese patients. This is because body fat is less vascular than visceral organs and muscles and has reduced contributions to dispersing and diluting the contrast medium in the blood. Thus, the 1:1 linear weight-based dosing may cause overestimation of the amount of contrast medium needed in obese patients. Nonlinear relationship between the body weight and required contrast medium volume is evident from Equations (1) and (2) in that blood volume is nonlinearly proportional to weight and height. The nonlinear relationship was suggested in several earlier clinical studies (1,41,46) and was explicitly investigated in later studies (50–53).

To overcome the limitation of the 1:1 linear weight-based iodine dosing, other body size parameters such as lean body weight (50,51,53) and body surface area (52) were proposed. Three studies (50,51,53) reported essentially the same conclusion that lean body weight is a better body-size adjustment index than total body weight because iodine dose calculated on the basis of the former resulted in more consistent contrast enhancement between the patients than that of the latter. In these studies, the lean body weight (or body fat percentage) was either measured by using a specialized scale (50,51) or estimated from a formula similar to that for blood volume (Eqq [1, 2]) (50,53). A recent study (52) reported that body surface area provides a better adjustment of iodine dose across a wide range of body sizes than body weight. Because body surface area is directly related to weight ($kg^{0.65}$) (57), this weight-scaling can be used as a proportionality to adjust the contrast medium dose for body size, instead of the linear 1:1 proportionality to body weight. This study proposed a contrast medium dosing scheme for which a reference dose was used for a standard body size to achieve a clinically desirable degree of contrast enhancement, and subsequent contrast medium doses were adjusted by using the two-thirds power of the weight.

The rationale for considering lean body weight and body surface area when prescribing a dose of contrast media is that an obese patient has a high proportion of body fat and a relatively small blood volume and proportionally a small well-perfused extracellular compartment. As a result, when the amount of iodine dose is estimated and increased linearly proportional to body weight with obese patients, the resulting contrast enhancement may be higher than that of patients who are not obese and who receive the iodine dose determined with the same linear body-weight proportionality. For imaging of markedly obese patients, however, other factors should be considered. Large subcutaneous and visceral fat in these patients may cause a profound x-ray beam scattering and deterioration of image quality and reduce the diagnostic capability of lesion detection and characterization, particularly in abdominal applications. Thus, the iodine dose administered may have to be greater for abdominal imaging than for thoracic imaging to achieve a higher degree of contrast enhancement to compensate for the loss of lesion

conspicuity in these obese patients. Every effort should also be made to select CT scanning parameters (tube current, section thickness, and reconstruction algorithm) appropriately to minimize image degradation.

Another important patient body factor associated with contrast enhancement is body mass index (weight in kilograms divided by height in meters squared). When patients are given a fixed iodine dose without adjustments for body weight, patients with higher body mass index tend to have reduced contrast enhancement (52,58). This is expected because patients with higher body mass index tended to be larger and more obese. Body mass index, however, is a measure of a person's fatness or thinness and is not an index for body size. A small baby with high body mass index would require less contrast material than a thin adult with low body mass index. Hence, body mass index cannot be used alone and should be incorporated with a body size parameter such as body weight and surface area to estimate iodine dose or delivery rate for a patient.

Although the magnitude of contrast enhancement is strongly affected by patient weight, the timing of enhancement is largely unaffected by this parameter (43,59–61). This can be explained by Equations (1)–(3) in that blood volume and cardiac output increase with body weight at the same rate and thus that contrast medium circulation time (proportional to the ratio of blood volume to cardiac output) is largely unaltered with and independent of patient weight.

Key points.—1. The most important patient-related factor affecting the magnitude of vascular and parenchymal contrast enhancement is body weight.

2. To maintain a consistent level of contrast enhancement in larger patients, one should consider increasing the overall iodine dose delivery by increasing contrast medium volume and/or concentration.

3. Iodine dose is commonly adjusted for body size on the basis of the 1:1 linear proportionality to body weight. This scheme may, however, cause overestimation of the required iodine dose in obese patients. Adjustment of iodine dose based on lean body weight or body surface area may be more appropriate in these patients.

Height

While numerous studies have been conducted on the effect of body weight on contrast enhancement, the effect of the patient's height on contrast enhancement has been rarely studied. One recent study (52) showed a moderately strong inverse correlation between aortic attenuation and height (ie, a lower aortic attenuation in a taller patient when all other variables remained fixed). This moderate correlation ($r = -0.47$), although weaker than that between aortic attenuation and weight ($r = -0.73$), is expected because blood volume increases with height (Eqq [1, 2]) and height and weight are correlated (ie, taller people are generally heavier than shorter people). The correlation between the height and weight is stronger for weights less than 80 kg but is weaker in heavier patients because weight tends to increase independently of height in patients with obesity (57). This nonlinear correlation and the range of height variation narrower than that of weight in adult patients likely explain why the effect of height on contrast enhancement is less than that of weight. Nevertheless, to precisely determine the required volume of contrast medium for a consistent enhancement, not only body weight but also height and body fat should be taken into consideration. A body size index that accounts for both weight and height variations is body surface area (52).

Just as with body weight, the time to peak enhancement is affected little by height (60,61) because both blood volume and cardiac output increase proportionally with height (Eqq [1–3]).

Cardiac Output and Cardiovascular Circulation

The most important patient-related factor affecting the timing of contrast enhancement is cardiac output and cardiovascular circulation (34). When cardiac output decreases, the circulation of contrast medium slows. Contrast material bolus arrives slowly and clears slowly, resulting in delayed contrast material bolus arrival and delayed peak arterial and parenchymal enhancement (Fig 7). The time of contrast material bolus arrival and the time to peak enhancement in all organs are highly correlated with, and linearly proportional to, the reduction in cardiac output (34,62). Thus, when scan timing is critical for CT imaging, scan delay should be individualized for each organ by using a test-bolus or bolus-tracking technique.

Slower clearance of contrast medium due to reduced cardiac output or circulation results in a higher, prolonged contrast enhancement profile. A dramatic, acute effect of reduced circulation on contrast enhancement can be observed in patients with hypovolemic shock and systemic hypotension. CT imaging in these patients would demonstrate an intense, persistent enhancement in the blood vessels and highly perfused organs such as the kidney and bowel wall. One study (63) showed that contrast enhancement in the coronary artery increased with a reduction of cardiac output and stroke volume but was not associated with the heart rate or ejection fraction. On the other hand, another study (64) reported that coronary artery contrast enhancement increased (by 10%) and was delayed (by 4 seconds) with a β-blocker that was used to reduce heart rate at cardiac CT. A recent study (65) noted that patients with cardiomyopathy showed prolonged contrast material arrival with no clearly defined peak in contrast enhancement compared with patients with normal left ventricular function. The prolonged, ill-defined peak enhancement resulted in progressively reduced distal coronary artery enhancement and a higher number of suboptimally enhanced arterial segments.

While reduced cardiac output increases the magnitude of peak aortic and parenchymal enhancements, the rate of the increase differs in the aorta and liver (Fig 7). Whereas the magnitude of peak aortic enhancement increases substantially in patients with reduced cardiac output, the magnitude

Figure 7

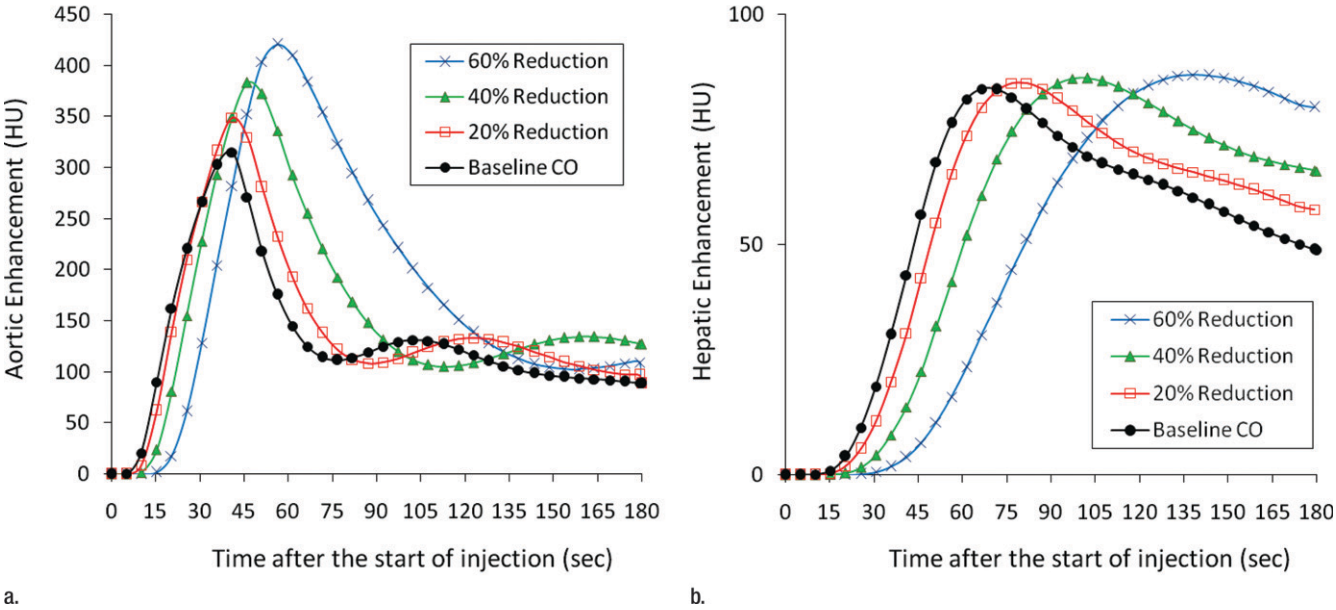

a. b.

Figure 7: Simulated contrast enhancement curves of the **(a)** abdominal aorta and **(b)** liver based on a hypothetical adult male (30 years old; weight, 70 kg; height, 170 cm) who underwent injection of 125 mL of contrast agent (350 mg of iodine per milliliter) at 4 mL/sec. A set of aortic and hepatic contrast enhancement curves was generated by reducing the baseline cardiac output *(CO)* by 20%, 40%, and 60%. With a reduced cardiac output, contrast material bolus arrives slowly and clears slowly, resulting in delayed contrast material bolus arrival and delayed and elevated peak arterial and hepatic parenchymal enhancement.

of peak hepatic enhancement increases only slightly. The kidney also enhances intensely with reduced cardiac output, because it has a high capillary density per organ volume and because excreted contrast medium is cleared slowly with reduced cardiac output.

In addition to the individual patient's variation in cardiac function, coexisting vascular disorders such as the presence of vascular stenosis or aneurysm may substantially affect the timing of contrast enhancement, particularly at peripheral (66,67) and cerebral CT angiography and CT perfusion (68,69). A wide range of contrast material bolus transit times from the injection site to the aorta (14–32 seconds; median, 18 seconds) and from the aorta to the pedal arteries (6–39 seconds; median, 15 seconds) have been reported (67). The large variations in downstream contrast material bolus flow make it challenging to determine a precise scan delay based on the contrast medium arrival in the upstream aorta. With a fast acquisition speed, the contrast material bolus may be outpaced by CT scanning and table movement, resulting in an inadequate enhancement of distal arteries. Strategies to prevent the occurrence of such situations at peripheral runoff CT angiography are discussed in Appendix E1 (online).

Key points.—1. The most important patient-related factor affecting the timing of contrast enhancement is cardiac output and cardiovascular circulation.

2. When cardiac output decreases, contrast material bolus arrives slowly and clears slowly, resulting in delayed contrast material bolus arrival and delayed but stronger peak arterial and parenchymal enhancement.

3. When scan timing is critical, CT scan delay should be individualized by using a test-bolus or a bolus-tracking technique to account for circulatory variations among patients.

Sex and Age

There are numerous miscellaneous patient-related factors or sources of biologic variations that may affect contrast enhancement. The effects of these factors are largely unknown with little published clinical data. Some of the effects may be inferred from the available physiologic data and contrast material pharmacokinetics. For example, the magnitude and timing of contrast enhancement are likely slightly different between men and women, in part because of their difference in blood volume (Eqq [1, 2]). Blood volumes in female patients are less than (by 5%–10% for an average-sized adult) those in male patients for a given weight and height. This difference may explain the clinical observation of higher contrast enhancement in female patients than male patients with the administration of a fixed iodine load per body weight (70). Furthermore, the decreased blood volume in female patients for a given cardiac output should affect the timing of contrast enhancement; contrast material bolus arrives slightly earlier in female patients than male patients (66,71,72). Some earlier studies, however, reported no significant difference between sex in contrast enhancement timing (43,60).

Age is likely related to a delayed contrast enhancement because cardiac output is reduced with age (2,73,74). Some studies reported a mild positive

correlation between age and delayed contrast material arrival (66,75,76), whereas other earlier studies showed little correlation between the two (43,60). A study (77) reported that contrast enhancement tended to be stronger in elderly patients (>60 years old) than younger patients for a given iodine load and suggested that iodine dose and injection rate could be reduced in elderly patients by 10% to achieve the same degree of enhancement.

Venous Access Site

The times to contrast material arrival and peak enhancement will be affected by the choice of intravenous access sites. The antecubital vein (preferably the basilic vein draining straight into the axillary and brachiocephalic veins) is the most commonly used and preferred venous access site for intravenous contrast medium administration. Central venous access has been increasingly used for the administration of chemotherapeutic agents or other long-term intravenous catheter medication.

While the safety and efficacy of central venous injection of CT contrast medium have been extensively investigated (78–81), the effect of different intravenous access sites on contrast enhancement has been scantly reported. One earlier study (82) showed that central venous injection of contrast medium, likely because of a shorter travel distance for the contrast material bolus, shortens the time to peak enhancement and improves vascular enhancement compared with peripheral injection. Another later study (83) described the benefit of the central venous injection in reduction of individual patient variability and improved mathematical prediction for contrast enhancement pattern. The potential benefit of a central venous injection on contrast enhancement, however, may not be attainable in practice because contrast medium is injected at much slower rates with the central injection than the peripheral injection because of safety concerns (80). Care should always be taken when injecting through a central venous catheter or a peripherally inserted central catheter by using a power injector. There are commercially available peripherally inserted central catheters that are power-injector rated (79), but most indwelling central catheters are not designed to accommodate the flow rates typical of contrast-enhanced multidetector CT (81).

Forearm or hand veins are occasionally used for the administration of contrast media. Because of their small size, however, these veins are not suitable for large-caliber intravenous catheters (sizes of 14–20 gauge) that are appropriate for CT angiography with an injection protocol with a high flow rate and a contrast medium with a high iodine concentration (84). Hence, injections through these sites more distal than the antecubital vein are usually performed at slower rates and are subjected to increased dispersion of contrast material bolus and a slower and lower enhancement. Compared with an antecubital vein injection, contrast enhancement may delay 2–4 seconds with a forearm injection but occur 4–6 seconds earlier with a central venous injection (85). In addition, the injection through the left arm may be subject to a higher dispersion and more delayed flow due to narrowing of the brachiocephalic vein in some patients than the right arm (86).

Hepatic Disease

Cirrhosis may be associated with decreased hepatic enhancement because of parenchymal fibrosis and decreased portal venous perfusion (1,87). Several studies (88–90) reported that the hepatic enhancement during the portal venous phase was delayed and reduced in patients with cirrhosis (likely because of increased hepatic resistance), whereas the hepatic enhancement during the arterial phase in these patients was either unaffected or even higher than average. Passive hepatic congestion from increased hepatic venous pressure or congestive heart failure affects the enhancement pattern (91,92). Other hepatic conditions such as hepatomegaly and diffuse hepatocellular disease may alter the hepatic parenchymal perfusion and thus the hepatic contrast enhancement profile.

Renal Function

The risk of contrast-induced nephropathy is closely associated with the dose of iodine used (93–97) and preexisting renal function (98–101). Thus, for patient safety, the amount of iodine dose at CT should be the minimum sufficient to achieve diagnostically appropriate contrast enhancement. Iodine dose can be adjusted in terms of contrast medium volume and concentration, and a wide range of concentrations are used in clinical practice. Despite a trend toward using less iodine dose with multidetector CT (notably at CT angiography), many clinical CT applications still require more than 100 mL of contrast medium for an average-sized adult patient. Use of less iodine is crucial, particularly in patients with preexisting renal dysfunction at high risk for developing contrast-induced nephropathy.

The incidence of contrast-induced nephropathy was studied by investigators in association with the contrast material volume adjusted for renal function (98,100). In these studies based on conventional cardiac angiography (not CT intravenous contrast material injection), contrast-induced nephropathy was reported to be infrequent if the contrast material volume adjusted for the body weight was less than 5 mL per kilogram of body weight divided by the serum creatinine level (in milligrams per deciliter), but the incidence of contrast-induced nephropathy increased if contrast material volume above this threshold was used. However, no threshold volume is likely safe from contrast-induced nephropathy, because even a small volume (eg, 30 mL) may cause contrast-induced nephropathy in high-risk patients (99). The Contrast-induced Nephropathy Consensus Working Panel recently suggested a guideline that a contrast material volume less than 100 mL is preferable in patients with an estimated glomerular filtration rate less than 60 mL/min per 1.73 m^2 (101).

Contrast Medium Factors

Key factors related to contrast medium to be considered in contrast enhancement include injection duration, injection

Figure 8

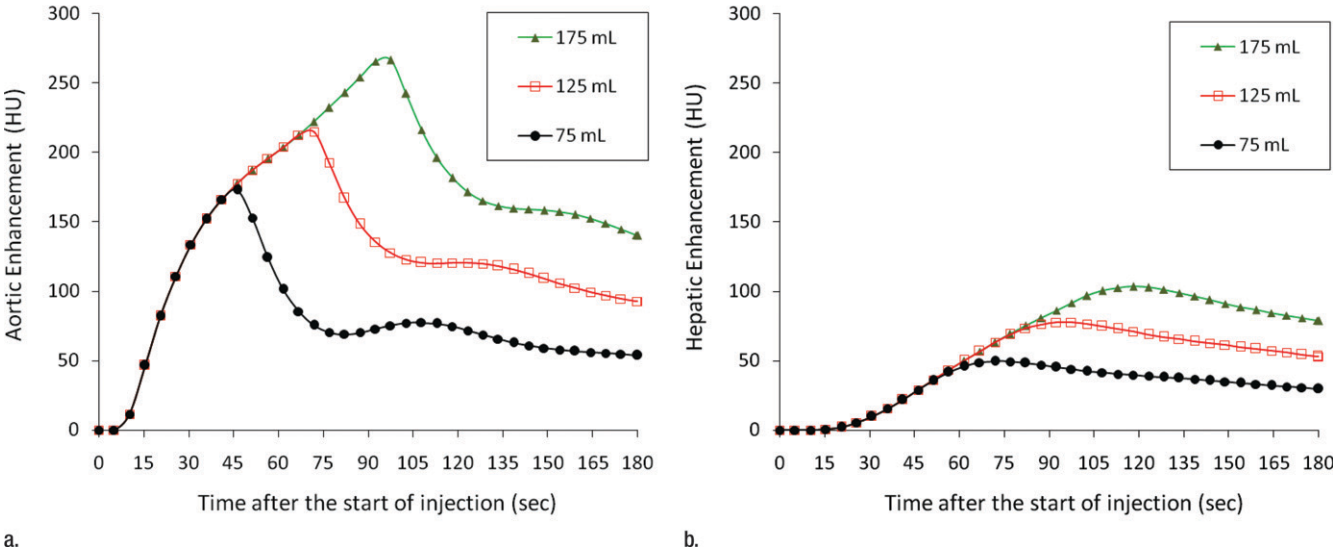

a. b.

Figure 8: Simulated contrast enhancement curves of the **(a)** abdominal aorta and **(b)** liver based on a hypothetical adult male (30 years old; weight, 70 kg; height, 170 cm) subjected to three volumes (75, 125, and 175 mL) of contrast medium (350 mg of iodine per milliliter) injected at the same rate of 2 mL/sec. A larger volume requires a longer duration to inject. Both the time to and the magnitude of the peaks of enhancement increase with the contrast medium volume (injection duration).

rate, injection bolus shape, contrast medium volume (injection duration × rate), concentration, physicochemistry, and use of a saline flush.

Injection Duration

Injection duration, defined as the time from the beginning to the completion of injection or alternatively defined by the contrast medium volume divided by the injection rate, critically affects both the magnitude and timing of contrast enhancement (18, 37, 48, 102–108). A longer injection (without lowering the injection rate) results in the administration of a larger contrast material volume into the body and thus proportionally increases the magnitude of vascular and parenchymal enhancement (Fig 8). The appropriate injection duration is determined by the scanning conditions and the clinical objectives of the examination. The injection duration should be prolonged for a long CT scan to maintain good enhancement throughout image acquisition. A prematurely terminated injection may result in insufficient contrast enhancement. An unnecessarily long injection, however, is a waste of contrast medium and may generate undesirable tissue and venous contrast enhancement.

The primary clinical factors considered for the determination of appropriate injection duration include body size, the vessel or organ of interest, and the desired level of enhancement (2). When a large dose of iodine is needed for CT but the injection rate and contrast material concentration cannot be increased (eg, a large patient with a limited vascular access), a longer injection administers more iodine dose into the body. Sometimes, the injection duration is intentionally shortened to increase the injection rate for a fixed amount of contrast material volume. High injection rate without increasing contrast material volume is particularly useful when attempting to achieve high arterial enhancement. A high injection rate, however, has limited influence on parenchymal or venous enhancement because this enhancement is principally determined by the total iodine dose administered into the body (18,35,44,103–106,109–112).

One scheme for determining injection duration for visceral parenchymal (eg, liver) enhancement is to *(a)* estimate a total amount of iodine mass required to achieve a desired level of enhancement for the patient's body size (1 mg of iodine per kilogram to generate 96 HU hepatic enhancement) (103), *(b)* choose a practical injection rate and contrast medium concentration, and *(c)* calculate the injection duration which corresponds to the iodine mass divided by the product of concentration and injection rate. This protocol results in a long injection duration for a large patient. Alternatively, when a fixed injection duration and concentration are used, a high injection rate should be used for a large patient to deliver a large amount of iodine. One advantage of using a fixed injection duration protocol over a fixed injection rate protocol is that scan timing can be more easily standardized (47).

Compared with visceral parenchymal enhancement, the determination of an optimal injection duration is more complicated for arterial or CT angiographic enhancement. This is because the degree of contrast enhancement is directly affected by the contrast medium delivery rate (see the injection rate section). For single-detector CT angiography or slow scans, the injection duration is usually set to be the same as the scan duration (113). This rule of thumb, however, may not be practical at multidetector CT because of markedly reduced scan durations. Contrast medium injected with its duration

matched to a short scan duration likely results in poor enhancement. One may be tempted to use a short, ultrafast injection to achieve a desired arterial enhancement level during image acquisition, particularly with ultrafast multidetector CT. This scheme does not work in practice because an injection rate higher than 8–10 mL/sec would not further elevate the magnitude of contrast enhancement (because of contrast medium dispersion and reflux from the right atrium, the pressure performance envelope of power injectors, and the risk of stressing the venous injection site at such high flow rates). Furthermore, the very short temporal window of diagnostically adequate enhancement resulting from a very short bolus makes precise scan timing highly challenging. Therefore, an injection with its duration less than 15 seconds is in general not recommended for diagnostic CT examinations in adults.

Our proposed scheme to estimate the injection duration for CT angiography is to add a constant duration (ie, "physiologic minimum" injection duration to account for dispersive effects of cardiopulmonary system on the contrast material bolus) to one-half of the scan duration. The physiologic minimum duration depends on the body size of the patients: It should be shorter in children than in adults; we may use 5, 10, 15, or 20 seconds for different body sizes. For example, given a patient with body weight of 60–80 kg who receives contrast material injected at 1.4 g of iodine per second (4 mL/sec of 350 mg of iodine per second), the estimated injection duration is 15 seconds plus one-half scan duration (ie, physiologic minimum duration = 15 seconds). Note that the physiologic minimum duration is determined empirically and is clinically meaningful only with the iodine delivery rate (contrast medium concentration and injection rate) adequate for body size. Thus, when we use a fixed physiologic minimum duration for various body sizes to achieve a consistent degree of enhancement, the injection rate or the concentration of contrast medium should be adjusted proportionally to the patient's body weight. A higher injection rate would be required for a large patient. With ultrafast CT (scan duration < 2 seconds) and fast injections, the physiologic minimum duration may be pushed to 10 seconds for adults. For these cases, we propose an alternative approach of determining the injection duration to be 10 seconds plus scan duration. Special care, however, should be taken to precisely determine scan timing as to avoid aggressive reduction of contrast medium below a physiologic minimum to achieve adequate contrast enhancement.

Injection duration is the most important injection factor to be considered for determining CT scan timing, because it directly affects the time to peak contrast enhancement in an organ or vessel. This was demonstrated in a number of contrast enhancement studies on the aorta (18,33,106,114,115), the pancreas (115,116), and the liver (1,18,33,115,117–121). When the injection duration increases, the time for the maximum deposit of contrast medium (the completion of the injection) is delayed and subsequently the time to peak contrast enhancement increases (Fig 8). Thus, a protocol with long injection duration (ie, high volume or low injection rate) requires a long scan delay to maximize contrast enhancement during the scanning. Conversely, a protocol with short injection duration (ie, low volume or high injection rate) results in an earlier arterial peak and parenchymal enhancement and necessitates a short scan delay. Therefore, when determining CT scanning time, it is more appropriate to use the completion of injection (the injection duration) as opposed to the start of injection as the reference time variable.

Key points.—1. Injection duration is the most important injection-related factor affecting CT scan timing. Scan delays should be determined with consideration of injection duration by using injection completion (not injection initiation) as the reference time variable.

2. One approach to estimate the injection duration for CT angiographic scan may be to add a constant duration (physiologic minimum duration) to the scan duration.

3. When contrast medium volume is tailored to the patient's body weight, a fixed injection duration protocol is advantageous over a fixed injection rate protocol because the scan timing can be more easily standardized and the iodine administration rate can be adjusted on the basis of patient size.

Injection Rate

The effect of injection rate on contrast enhancement has been studied by a number of investigators (33,44,82,103,106,108,109,115,116,120–131). When the duration of injection is fixed, a faster injection rate increases both the delivery rate and the total delivered amount of contrast medium. It also results in a higher magnitude of vascular and parenchymal enhancement. On the other hand, when the total amount of contrast medium is fixed, a faster injection increases the delivery rate but shortens the injection duration and the time to peak enhancement (Fig 9). This faster delivery of a fixed volume increases the magnitude of the aortic enhancement and, to a lesser degree, the magnitude of the hepatic or venous enhancement (Fig 10) (33,108,124,126). The difference in the magnitude increase between the aorta and liver can be explained by the aortic and hepatic circulatory transit time differences. While a faster delivery of contrast medium directly leads to a faster accumulation of contrast medium in the aorta and a higher aortic enhancement, hepatic enhancement is primarily influenced by the portal circulation after the first-pass effect of the fast delivery is diminished and the bolus is dispersed by the long circulation pathway. An increase in injection rate (up to <10 mL/sec) steeply increases the magnitude of peak aortic enhancement (Fig 10). On the other hand, the peak hepatic enhancement increases much more gradually and is apparent only at relatively low injection rates (<3 mL/sec) (33).

An increase in injection rate for a fixed volume of contrast medium results in a higher arterial enhancement but reduces the potential temporal window for CT scanning because of the shortened injection duration (Fig 9). The reduced temporal window would be suitable with fast arterial CT applications

Figure 9

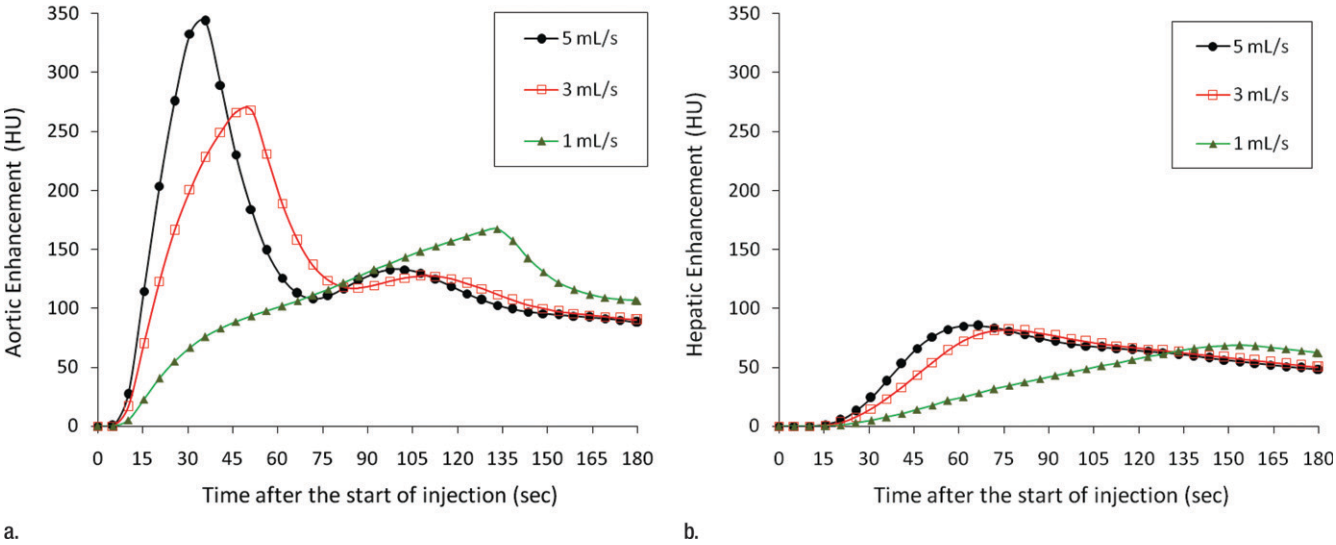

a. b.

Figure 9: Simulated contrast enhancement curves of the **(a)** abdominal aorta and **(b)** liver based on a hypothetical adult male (30 years old; weight, 70 kg; height, 170 cm) subjected to a fixed volume of 125 mL of contrast medium (350 mg of iodine per milliliter) injected at 1, 3, and 5 mL/sec. As the rate of injection increases, the magnitude of contrast enhancement increases, but the duration of high magnitude contrast enhancement decreases. This trend is far more pronounced in aortic than hepatic enhancement.

(eg, multidetector CT angiography) but requires more precise scan timing. Thus, a fast injection is beneficial for procedures with short scan durations. On the other hand, a slower but longer injection generating a prolonged vascular enhancement is more appropriate for procedures with long scan durations. A faster injection with shorter injection duration is preferred for multiphasic imaging of visceral organs, because it not only results in a greater temporal separation (because of a shorter injection duration) but also wider degrees of enhancement between the arterial and venous phases of the visceral parenchymal enhancement (because of a higher arterial enhancement). This greater separation of contrast enhancement phases at multiphasic imaging of the liver, pancreas, and kidney improves lesion detection and characterization.

Injection rates of 2–5 mL/sec through an antecubital vein are commonly used for clinical CT imaging. Although contrast material administration at higher rates of 3–5 mL/sec are reported to be feasible and safe with certain central venous catheters (80,81,83), low injection rates of 1.5–2.0 mL/sec are typically used with central venous catheters, peripherally inserted central catheters, and small-caliber catheters placed in forearm or hand veins because of safety concerns (79) and the pressure performance envelope of power injectors (84). High injection rates of 5–10 mL/sec are often used for CT perfusion imaging to generate high peak enhancement with a short peak time. An increase in the injection rate greater than 8–10 mL/sec is not likely to improve the enhancement further because the inherent mixing or dispersion of contrast medium in the central blood compartment dampens the effect of fast injections propagating to a target organ (71,82,118,132). Furthermore, a fast injection may result in a high retrograde reflux of contrast medium into the inferior vena cava and hepatic veins, even with the absence of right-sided heart disease (133).

Key points.—1. The magnitude of peak aortic enhancement increases steeply with the escalation of the injection rate (up to 8–10 mL/sec), while the peak visceral parenchymal (hepatic) enhancement increases much more gradually and is only apparent at relatively low injection rates (<3 mL/sec).

2. A fast injection would be better suited to a fast scan but requires more precise scan timing. When injection rates are increased with a fixed volume of contrast medium, the peaks of enhancement increase in magnitude and occur earlier, but the duration of high magnitude enhancement decreases.

Injection Bolus Shaping

Contrast medium is commonly administered at a constant injection rate (uniphasic-rate injection). The second most commonly used injection bolus shape is a biphasic-rate injection: a fast constant-rate injection followed by a slow constant-rate injection. The biphasic-rate injection protocol is useful to prolong injection duration and maintain contrast enhancement for a long CT scan duration without increasing the amount of contrast medium (1,67,103, 134–136). Thus, the biphasic-rate injection was widely practiced with slow CT scans, particularly during the prespiral CT era, and continues to be used with some multidetector CT applications that require long acquisition times, such as whole-body imaging (136) and peripheral CT angiography (67). Compared with the uniphasic-rate injection, however, the biphasic-rate injection may not yield a sufficiently high contrast enhancement for the duration of image acquisition in some applications (137,138).

Figure 10

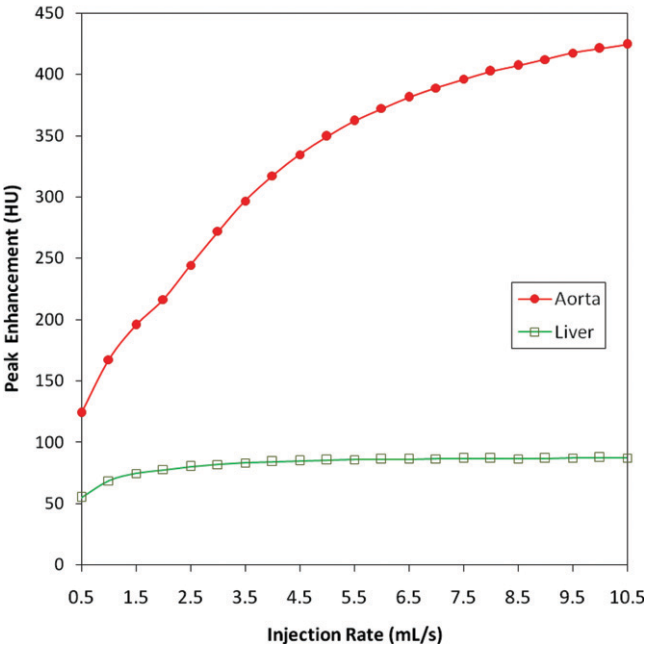

Figure 10: Graph shows the effect of contrast medium injection rate on the magnitude of peak aortic and hepatic contrast enhancement. The magnitude of peak abdominal aortic and hepatic contrast enhancement was computed from a simulation based on a hypothetical adult male (30 years old; weight, 70 kg; height, 170 cm) subjected to a fixed volume of 125 mL of contrast medium (350 mg of iodine per milliliter) injected at varying rates. A faster delivery of a fixed volume increases the magnitude of the peak aortic enhancement and, to a lesser degree, the magnitude of the peak hepatic enhancement. The increase in peak hepatic enhancement is apparent only at relatively low rates (<3 mL/sec).

A recent variation of the biphasic injection is the injection of two different concentrations: the injection of higher concentration (undiluted) contrast medium followed by a lower concentration (diluted) contrast medium. The lower concentration is typically achieved by simultaneously injecting the undiluted contrast material and saline, which are loaded separately in syringes of a dual-head injector. The biphasic-concentration injection technique has been reported to be useful in improving right ventricular chamber enhancement and reducing the artifact resulting from the dense, undiluted contrast medium in the superior vena cava (139–141).

The shape of contrast material bolus injection can be tailored to achieve a desired enhancement pattern. With uniphasic-rate injection, the time-enhancement response progressively increases and peaks shortly after the completion of the injection and is followed by a relatively rapid decline in enhancement. This enhancement pattern is referred as a "hump" or "peaked" enhancement which lacks a true plateau peak enhancement. A biphasic-rate injection typically results in a double-peaked arterial contrast enhancement pattern. This is because the contrast enhancement pattern in a vessel increases earlier (because of the fast first-phase injection) and declines before the contrast material in the slow second-phase injection reaches the area of interest. This pattern may not be observable in the parenchymal enhancement. To improve uniformity in the arterial enhancement while reducing double-peaking, the injection rates at the biphasic-rate injection can be customized algorithmically for an individual patient by using the information extracted from a test-bolus injection acquired prior to the biphasic-rate injection (83,142). A more refined approach was proposed in a later study by a different group (143). Another injection bolus-shaping technique that is more sophisticated than the uniphasic- and biphasic-rate injections is a multiphasic, exponentially decelerated injection (31,32). The basic premise of this technique is that uniform vascular enhancement occurs when contrast material accumulation achieves a steady state in vessels. This state can be achieved when the contrast medium administered into the central blood compartment, delivered with an exponentially decreasing rate, is balanced by the rate of contrast medium clearance from the same compartment. The injection bolus profile of this method was derived from a physiologically based pharmacokinetic model. According to this model prediction, a multiphasic-rate injection bolus with exponentially decreasing rate (eg, $4 \cdot \exp[-0.01t]$ mL/sec, where t is time) provides a uniform vascular enhancement (32).

Uniform contrast enhancement is desired at cardiac imaging to enhance both the left and right ventricular chambers while reducing streak artifacts in the superior vena cava and right atrium. Uniform enhancement at CT angiography facilitates image processing and display because three-dimensional image postprocessing techniques are often based on threshold CT attenuations (142,144) (eg, a threshold-based bone subtraction method to segment cerebral blood vessels) (145). For some CT angiographic applications, nonuniformly enhanced images may result in artifactual findings such as filling defects and perceived stenoses (146–148). Uniform enhancement is also crucial to achieve a steady-state plasma concentration of iodinated contrast medium during image acquisition for perfused blood volume CT (145,149). An additional advantage of uniform enhancement is that precise timing of image acquisition becomes less critical because of no requirement to target the acquisition at a specific peak enhancement time point. However, for a very short scan, contrast enhancement is likely uniform during the scan coverage,

Figure 11

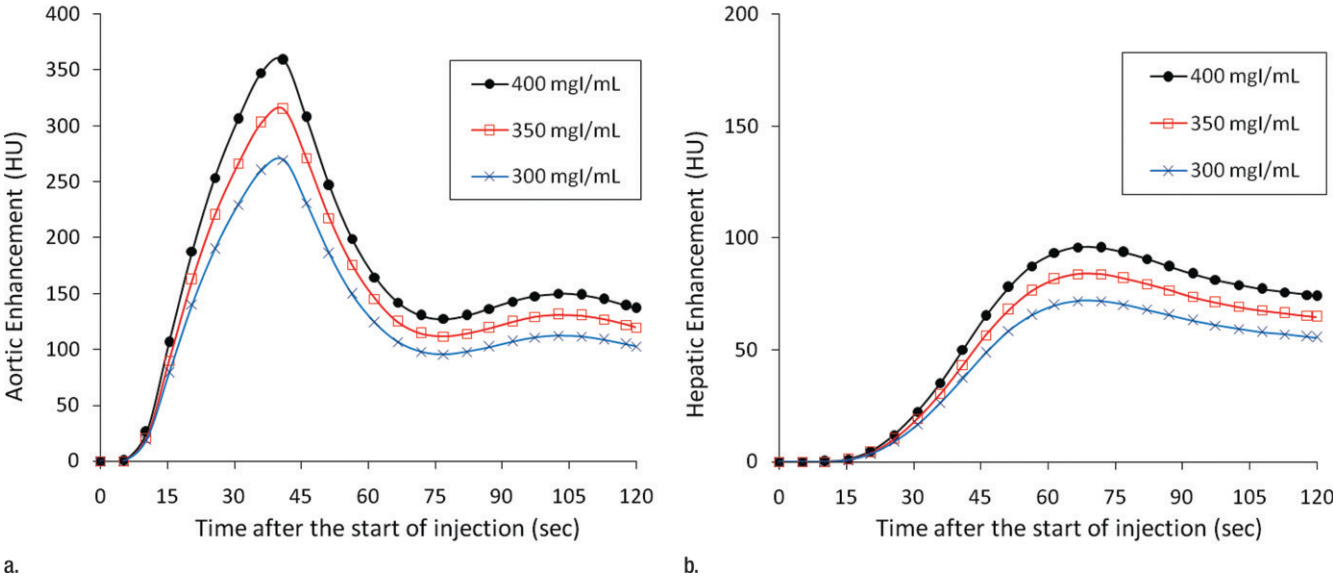

Figure 11: Simulated contrast enhancement curves with contrast media of a fixed volume but at three concentrations injected at a fixed rate. Simulated enhancement curves of the **(a)** abdominal aorta and **(b)** liver based on a hypothetical adult male (30 years old; weight, 70 kg; height, 170 cm) who underwent injection of 125 mL of contrast medium with varying concentrations (300, 350, and 400 mg of iodine per milliliter) at 4 mL/sec. Contrast medium with a higher concentration delivers a larger dose of iodine faster and results in a higher magnitude of peak contrast enhancement and a wider temporal window for CT imaging at a given level of enhancement.

even with a uniphasic injection protocol, unless a scan is performed during a rapid increase or decline of contrast enhancement.

Key point.—The shape of injected contrast material bolus can be tailored to bring about a desired enhancement pattern. Uniform prolonged arterial enhancement may be achieved with either an individually customized biphasic injection or with the exponentially decelerated multiphasic injection method.

Contrast Medium Concentration

Intravenous contrast media are commercially available in a wide range of concentrations (240–370 mg of iodine per milliliter). The selection of appropriate contrast medium concentration depends on multiple factors such as the availability of contrast medium, clinical objectives, CT scanner configuration, injector, and cost. The effect of contrast medium concentration on enhancement was investigated extensively in various studies with single-detector CT (42,110, 135,150–153). Contrast media with high iodine concentration (350 mg of iodine per milliliter and higher) were widely used and studied with multidetector CT (19,48,70,112,128–130,154–169). This trend reflects the fact that a high rate of iodine delivery is desired with fast multidetector CT to maximize the arterial enhancement at CT angiography and improve the depiction of hypervascular tumors. Furthermore, the use of a contrast medium with high iodine concentration is an alternative way other than increasing the injection rate to achieve a fast delivery of iodine dose.

When the volume, injection rate, and duration of injection of contrast medium are fixed, a higher-concentration contrast medium will deliver a larger dose of iodine faster. This results in a higher magnitude of peak contrast enhancement and a wider temporal window for CT imaging at a given level of enhancement (Fig 11). The time to peak enhancement is unaffected because the duration and rate of the injection remain unchanged. On the other hand, when the total iodine mass and injection rate are fixed, the injection volume and duration varies depending on the concentration; the bolus volume with a higher-concentration contrast medium is smaller than that of a lower iodine concentration. A small volume of contrast medium with a higher concentration injected at a fixed injection rate results in a faster delivery of iodine mass per unit time and thus results in arterial enhancement with an earlier peak and greater peak enhancement but a shorter duration of enhancement (164) (Fig 12). However, the magnitude of hepatic enhancement will not be substantially affected. This simulation result demonstrates that the injection of contrast medium with a higher concentration (at a fixed iodine dose) may have the same effect as the faster injection of contrast medium (at a fixed total volume) (Fig 9), because both procedures result in a faster rate of iodine delivery per unit time.

A number of studies (42,110,112, 129,130,135,150,151,153,154,159–163,165) on the effect of contrast material concentration on enhancement mainly focused on achieving greater contrast enhancement by using contrast media with a higher concentration and a fixed volume (ie, a higher total iodine dose). The outcomes of these studies are largely expected and similar to those demonstrated with the

Figure 12

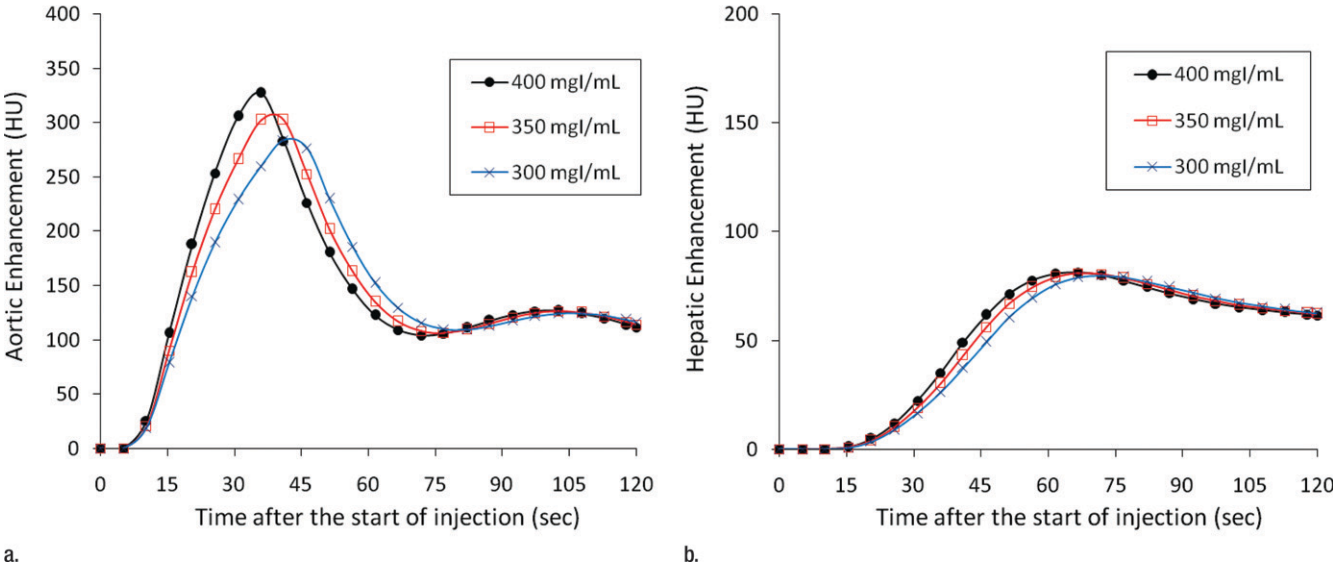

Figure 12: Simulated contrast enhancement curves with contrast media of a fixed iodine mass but at three concentrations injected at a fixed rate. Simulated enhancement curves of the **(a)** abdominal aorta and **(b)** liver based on a hypothetical adult male (30 years old; weight, 70 kg; height, 170 cm) subjected to 4-mL/sec injection of a fixed iodine mass (42 g) but at three concentrations and volumes: 300 mgI/mL at 140 mL, 350 mgI/mL at 120 mL, and 400 mgI/mL at 105 mL. The aortic time-enhancement curves demonstrate that the use of high-concentration contrast material is associated with earlier and greater peak aortic enhancement. The effect of high iodine concentration contrast material on liver enhancement is minimal if iodine mass is unchanged.

simulated contrast enhancement curves in Figure 11.

Less predictable contrast enhancement outcomes are obtained when contrast media of different concentrations are injected at a fixed iodine mass and fixed injection duration: for example, contrast medium of 400 mg of iodine per milliliter concentration injected at 3 mL/sec versus contrast medium of 300 mg of iodine per milliliter concentration injected at 4 mL/sec over the same injection duration. Although the rate of iodine mass delivered per unit time remains the same between the two concentrations, contrast medium with higher concentration is smaller in volume and injected at a lower volumetric injection rate than contrast medium with lower concentration. The results of comparison between the two contrast media of different concentrations are somewhat controversial (170); while some studies (37,158,171) demonstrated the advantage of using low concentration contrast material with a high volume improving contrast enhancement, other studies (70,128,162) showed no significant differences. Even within the same group of investigators, different findings and conclusions were published in different articles (166–169). From my personal experience and on the basis of unpublished data, a faster volumetric injection of contrast medium with lower concentration at a fixed delivery rate of iodine mass would yield earlier and higher aortic contrast enhancement. This is likely explained by the fact that an increase in the volume of contrast medium causes dilution volume effect and shortens the contrast material bolus transit time from the peripheral veins to the central blood compartment. The difference in enhancement associated with different concentrations may be more pronounced when low and high concentrations are compared (171) than when moderate and high concentrations are compared (70,128,162). Furthermore, the effect of different concentrations on hepatic enhancement may be smaller than that on aortic enhancement (Fig 12) (42).

Some clinical applications may favor the use of contrast media with low concentration, particularly when saline flush is not used. One study (171) reported that diluted contrast medium (150 mg of iodine per milliliter) injected faster at thoracic CT examinations resulted in less perivenous artifacts and higher aortic enhancement than undiluted contrast medium (300 mg of iodine per milliliter). An additional benefit of contrast medium with low concentration is low viscosity. High viscosity leads to the elevation of the injector pressure and thus may prohibit a fast delivery of iodine when a rapid peripheral intravenous injection is desired (84,172,173).

Key points.—1. Use of contrast medium with high iodine concentration is an alternative approach to using a high injection rate as a means to increase iodine delivery rate.

2. For fast multidetector CT, a high iodine delivery rate is desirable to maximize arterial enhancement at CT angiography and to depict hypervascular tumors.

Figure 13

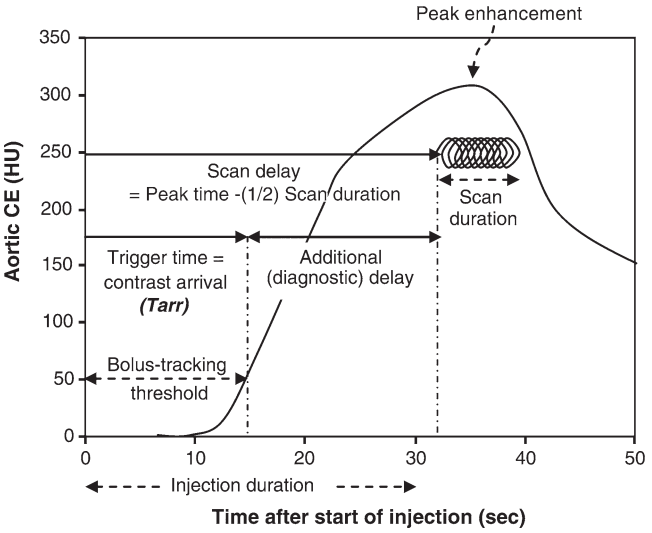

Figure 13: Graph of contrast medium injection, enhancement, and scan time variables illustrates the determination of scan delay from measured contrast material arrival time *(Tarr)* and additional diagnostic delay. Scan delay should be determined by considering contrast medium injection duration, contrast material arrival time, and scan duration. Contrast material arrival time can be measured with a test-bolus or bolus-tracking method. In the figure, when bolus-tracking is used, contrast material arrival time corresponds to the time for the aortic enhancement *(CE)* to reach a 50-HU threshold. The scan delay is determined as the sum of contrast material arrival time plus an additional (diagnostic) delay. The additional diagnostic delay should be formulated considering the injection duration and scan duration such that the peak enhancement is centered in the middle of CT scan (scan delay = peak time – (1/2) scan duration).

Figure 14

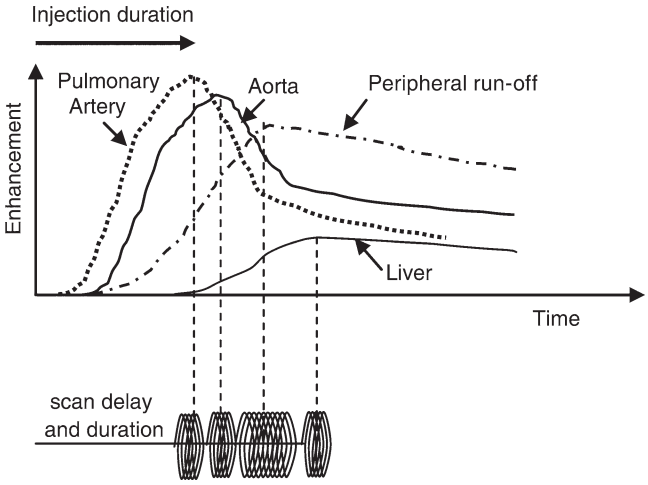

Figure 14: Time-enhancement curve and scan delay diagram for organs at different circulatory paths. To image each target organ at its peak contrast enhancement, CT should be delayed appropriately from the start or completion of contrast material injection. The time to peak enhancement at each target organ is determined as a function of the injection duration and contrast material arrival time from injection site to the target organ.

3. A potential disadvantage of contrast medium with high concentration is high viscosity.

Contrast Medium Physicochemistry

Aside from concentration (iodine content), two important physicochemical properties of contrast media affecting clinical practice are osmolality and viscosity. While the osmolality of contrast media is commonly discussed in association with adverse effects of contrast media (101), it is the viscosity of contrast media that plays an important role in the contrast medium delivery and enhancement (84,172–176). The viscosity increases with increased contrast medium concentration. Because of this, the use of a high-concentration contrast medium injected at high rates may not increase iodine delivery to the vessel of interest, resulting in a contrast enhancement weaker than expected (84,173). The viscosity of contrast media is affected by temperature and is lower at higher temperature (101,175,177). Hence, warming contrast medium reduces its viscosity and increases the efficiency of delivering high-viscosity contrast media through small-bore catheters (177). Contrast media warmed to the level of body temperature (35°C) before administration also helps improve patient compliance and tolerance (178). A recent study (176) showed that the use of warmed contrast medium yields a higher enhancement and a shorter time to reach maximum enhancement duration.

Saline Flush

A saline flush pushes the tail of the injected contrast medium bolus into the central blood volume and makes use of contrast medium that would otherwise remain unused in the injection tubing and peripheral veins. A saline flush therefore increases both the efficiency of contrast medium utilization and the level of contrast enhancement (82,179–188). Additional advantages of a saline flush include *(a)* improved bolus geometry due to reduced intravascular contrast medium dispersion, *(b)* reduced streak artifact from dense contrast medium in the brachiocephalic vein and superior vena cava on thoracic CT studies (179,181), *(c)* increased hydration to reduce contrast-induced nephrotoxicity, and *(d)* elimination of the need for injecting a small amount of saline at the end of CT scan to wash out any residual contrast medium which is highly viscous and may clog the vascular access catheter.

A saline flush is particularly beneficial when a small volume of contrast medium is used. For this reason, a saline flush is commonly used for gadolinium-enhanced magnetic resonance (MR) imaging but has not been widely used at routine CT examinations. An additional reason for the slow acceptance of saline usage at CT is the practical requirement of a double-barrel power injector for the injection of contrast

medium and saline. The benefit of saline chase at CT imaging was demonstrated in earlier studies by using injection of saline flush with a conventional single-barrel injector after layering saline on top of the contrast medium at thoracic CT imaging (82,179,180) or by using a system with two interconnected injectors for saline flush (82,181,182). Studies (140,183–187,189,190) showed a routine use of double-barrel power injectors. With the increasing use of multidetector CT and double-barrel CT contrast material injectors and the increasing clinical applications of CT angiography, saline flush is now widely accepted at CT imaging. Saline flush improves the efficiency of contrast medium utilization by pushing the underutilized contrast medium within the injection tubing and peripheral veins into the central blood volume and having it contribute to a stronger contrast enhancement. Alternatively, compared with no saline flush, use of saline flush can improve contrast medium utilization and reduce the iodine dose administered to patients without negatively affecting the level of contrast enhancement.

The volumes of contrast medium that can be substituted with a saline flush without compromising contrast enhancement have been reported to vary widely: 12 mL (182), 15 mL (181), 18 mL (36), 20 mL (183,185–187), 40 mL (184), and 50 mL (179,180). Among these studies, the study reporting the smallest saving of contrast medium was based on a systematic analysis of the magnitude and timing of enhancement associated with varying amounts of saline flush (182). The maximum amount of contrast medium that could be saved by using a saline flush corresponds to the volume of contrast medium retained in the injection tubing plus that in the peripheral venous space between the brachial vein and the superior vena cava. The peripheral venous space volume is related to patient size or weight. On the basis of the results of recently published data and factoring in the patient's peripheral venous size, in a typical clinical setting, we estimate that 12–20 mL of contrast medium could be replaced by a saline flush in the venous space. Therefore, considering about 10 mL of contrast medium in the tubing between the injector and venous access, an injection of more than 20–30 mL of saline flush would not save any more contrast medium nor would it contribute to further improvement of contrast enhancement. This amount of savings was supported by the results of a recent phantom experimental study (191).

For a fixed volume of contrast media and an application of a saline flush, there is a slight increase (5%–10%) in the magnitude of the peak arterial enhancement, and the time to peak arterial enhancement is prolonged (36,182, 187,188,190,191). Note that a saline flush does not affect the initial contrast material arrival time or initial rise in contrast enhancement. The extended duration of peak arterial enhancement depends on the injection duration (volume divided by injection rate) of contrast medium pushed by a saline flush and would range 3–10 seconds (longer with lower injection rate). This finding suggests that we may need to slightly increase the scan delay to optimize contrast enhancement when using a saline flush. With a saline flush, however, the contrast enhancement profile after the enhancement peak will more rapidly decline because there is no slow, late-flowing of contrast medium from the peripheral venous space. Scanning during this rapid decline may result in insufficient contrast enhancement (192). A too-aggressive reduction of contrast medium with the use of a saline flush may result in poor enhancement, particularly when using a small total amount of contrast medium and in a large patient.

The injection of a saline bolus while injecting the contrast medium, rather than after the completion of contrast medium injection, would result in a dilution of contrast medium, as demonstrated in the biphasic-concentration injection technique (139–141) (more discussion in the injection bolus shaping section). Furthermore, the saline flush may be injected at rates different from contrast medium to modify the level of enhancement during the late phase of contrast enhancement. In general, higher enhancement with a faster saline injection or a prolonged lower enhancement with a slower saline injection would be achieved (22,188,190,191). However, two recent studies (190,191) suggested that the injection of saline faster than that of contrast medium may not result in further increase in the degree of contrast enhancement.

Key points.—1. A saline flush improves contrast enhancement and the efficiency of contrast medium use, reduces artifacts, and is particularly beneficial when the total volume of contrast medium is small.

2. Twenty to 30 mL of saline flush may be sufficient; the injection of a larger quantity might not further improve contrast enhancement.

CT Scanning Factors

CT scanning factors play a critical role by allowing us to acquire contrast-enhanced images at a specific time point of contrast enhancement. Inadequately implemented CT acquisition parameters will result in a poorly enhanced study, even with perfectly determined patient and injection factors for contrast enhancement. Scanning parameters critically affecting contrast enhancement include scan duration, scan direction, multiphasic acquisitions during different phases of contrast enhancement, determination of the contrast material arrival time relative to the scan delay, and scan delay from the start (or completion) of contrast medium injection to the initiation of scan.

Scan Duration, Scan Direction, and Multiphasic Scanning

To achieve diagnostically adequate contrast enhancement during CT scanning, it is vital to know the duration of the scan acquisition. A long CT scan duration likely requires a long contrast medium injection. Therefore, the scan duration information directly affects the determination of injection duration and injection rate or contrast medium volume (injection duration × injection rate). Scan duration depends on the speed, type, and mode of CT scan and clinical application. With state-of-the-art multidetector CT, contrast-enhanced

clinical images are routinely acquired in less than 10 seconds. Clinical CT applications requiring long scans include *(a)* peripheral runoff CT angiography that involves large anatomic coverage and is often delayed intentionally to allow a slow contrast material bolus flow to transit into distal arteries, *(b)* cardiac CT angiography that may require a high degree of scan overlap, and *(c)* multiphasic and perfusion acquisitions that are obtained at different phases or time points of contrast enhancement.

As contrast medium distributes throughout body via the central blood circulation, contrast enhancement is reduced as the contrast material propagates downstream in the circulation. CT scanning following along this directional flow of contrast medium would improve contrast enhancement and makes efficient use of contrast medium. Thus, the maximal contrast enhancement may be achieved by starting the scan at the upstream peak enhancement and moving downstream at the same rate as the propagation of peak enhancement without outrunning or falling behind the peak enhancement of the contrast material bolus. Chasing the contrast material bolus may not be feasible with a slow CT scanner, and there may be a considerable craniocaudal difference in contrast enhancement depending on scan direction, even for a relatively small scanning volume such the liver (44,193,194). The differential contrast enhancement associated with scanning in the craniocaudal direction would be reduced by extending the injection duration, maintaining uniform contrast enhancement during the CT scan, or increasing the scan speed. However, scanning too fast may outpace the propagation of contrast enhancement and reach the downstream distal arteries before the transit of contrast medium, resulting in weak downstream enhancement (67).

While clinical contrast-enhanced CT scans are usually performed with the scan direction commensurate with the direction of contrast material bolus propagation, one notable exception is caudocranial scanning at pulmonary CT angiography for the detection of pulmonary emboli. Scanning the lower lobes first is beneficial because emboli are more frequently located in the lower lobes and, if the patient breathes during image acquisition, there is more excursion of the lower lobes than the upper lobes (195). A secondary benefit of caudocranial scanning is that artifact from dense contrast medium flowing in the superior vena cava is minimized when scanning later after the contrast medium has been flushed from the veins. A similar benefit in artifact reduction was observed at carotid artery CT angiography performed with use of a craniocaudal scan direction (196). However, when the scan direction is opposite to the flow of contrast medium for a long scan, contrast material injection duration may need to be increased to ensure adequate enhancement of the upstream structures.

Fast scan speed and coverage with multidetector CT facilitates acquisition at multiple precisely defined phases of contrast enhancement and may improve the detection and characterization of lesions in various organs including the liver, pancreas, kidney, and vessels. Optimization of phase-specific contrast enhancement in an organ is complex and requires consideration of multiple injection and scanning factors as well as individual patient's circulation time. This is discussed in detail in each corresponding clinical application in the clinical considerations section in Appendix E1 (online).

Key points.—1. Scan duration information is crucial for the calculation of the injection duration and scan timing. For a long scan, an extended injection is likely required.

2. While clinical contrast-enhanced CT is performed with the scan direction commensurate with the direction of contrast material bolus propagation, one notable exception is caudocranial scanning at pulmonary CT angiography for the detection of pulmonary emboli.

Determination of Contrast Material Arrival Time: Test Bolus versus Bolus-tracking Method

As discussed in the patient factors section, a patient's cardiovascular circulation critically affects contrast enhancement timing and should be considered when determining individualized CT scan timing. For this purpose, the contrast material bolus transit time (which is closely associated with an individual patient's circulation time) can be measured prior to diagnostic CT and factored into the determination of scan timing for diagnostic CT. Two methods, test bolus and bolus tracking, are commonly used to measure the transit time (ie, contrast material arrival time) (Fig 13).

The test-bolus method is predicated on injecting a small test bolus (10–20 mL) of contrast medium prior to performing diagnostic CT with a full bolus of contrast medium. The test bolus and full bolus are usually injected at the same rate. Immediately following the test-bolus injection, multiple low-radiation-dose sequential images are acquired at a fixed scan level (commonly at the starting level of diagnostic scan). A time-enhancement curve is obtained by measuring the enhancement within a region of interest placed over a target organ (commonly aorta or cardiac chamber). The time to peak test-bolus contrast enhancement (contrast material arrival time) is determined from the time to peak enhancement and is used to estimate scan delays for full-bolus diagnostic CT. For a single-detector CT angiographic scan, contrast material arrival time was commonly selected to be the diagnostic scan delay (113,197). Variations of this scheme were used by different investigators (18). With fast multidetector CT, a direct use of contrast material arrival time as a scan delay may result in scanning too early (198,199). Therefore, the scan delay should be calculated as the sum of contrast material arrival time plus an additional delay (also called diagnostic delay) such that the diagnostic CT scan is adequately delayed and centered at the maximum of contrast enhancement (18,156).

The bolus-tracking method is based on imaging and measuring temporal changes of contrast enhancement at a sampling site while a full diagnostic bolus of contrast medium is injected. No test injection of contrast medium is

Table 1

Key Contrast Material Injection and Scanning Parameters of Common Clinical Protocols

Examination	Typical Contrast Material Dose for 70-kg Patient*	Typical Injection Rate for 70-kg Patient†	Injection Duration	Scan Duration	Fixed (Constant) Scan Delay	Variable Scan Delay‡	Circulation-adjusted Scan Delay‡	Saline Flush
Brain parenchyma	80 mL of 300 mgI/mL (0.3–0.4 gI/kg)	1 mL/sec or hand injection	1–2 minutes	Variable	5 minutes	NA	NA	Not essential
Neck soft tissue	100 mL of 300 mgI/mL (0.4 gI/kg)	2 mL/sec	50 seconds	Variable	50–90 seconds (shorter with SDCT)§	ID + 10 − SD/2	ID + T_{ARR} − 2 − SD/2 (T_{ARR} at ascending aorta)	Not essential
Neck and brain CT angiography	100 mL of 350 mgI/mL at 16-detector CT; 75 mL at 64-detector CT	4 mL/sec (16-detector CT); 4.5 mL/sec (64-detector CT)	25 seconds (16-detector CT); 17 seconds (64-detector CT)	10–15 seconds (16-detector CT); 5–10 seconds (64-detector CT)	15 seconds (neck); 18–20 seconds (brain)	ID + 5 − SD/2 (neck); ID + 8 − SD/2 (brain)	ID + T_{ARR} − 7 − SD/2 (neck); ID + T_{ARR} − 4 − SD/2 (brain); T_{ARR} at ascending aorta	Essential
Brain perfusion	50 mL of 350 mgI/mL	4–10 mL/sec	<10 seconds	<60 seconds	5 seconds	5 seconds	5 seconds	Essential
Routine chest	70 mL of 300–350 mgI/mL	2–3 mL/sec	40 seconds (SDCT); 30–40 seconds (MDCT)§	Variable (SDCT); 5–20 seconds (MDCT)	30 seconds (SDCT); 40–60 seconds (MDCT)§	ID + 5 − SD/2 (SDCT and MDCT)	ID + T_{ARR} − 7 − SD/2 (T_{ARR} at ascending aorta)	Not essential
Pulmonary CT angiography	120 mL for venogram or four-detector CT; 100 mL of 350 mgI/mL at 16- or 64-detector CT	4–5 mL/sec	25–30 seconds (four-detector CT); 20–25 seconds (16- or 64-detector CT); or 15 seconds + SD	20–30 seconds (four-detector CT); 5–10 seconds (16- or 64-detector CT); 3–4 minutes (venogram)	15 seconds (4- or 16-detector CT); 20 seconds (64-detector CT)	ID + 5 − SD	ID + T_{ARR} − 5 − SD (T_{ARR} at main pulmonary artery)	Essential
Aortic and coronary CT angiography	130 mL of 350 mgI/mL at four-detector CT; 100 mL at 16-detector CT; 75 mL at 64-detector CT	3.5 mL/sec (four-detector CT); 4 mL/sec (16-detector CT); 4.5–5 mL/sec (64-detector CT)	40 seconds (four-detector CT); 25 seconds (16-detector CT); 15 seconds (64-detector CT); or 15 seconds + SD/2 or 10 seconds + SD	15–25 seconds (four-detector CT); 10–15 seconds (16-detector CT); 5–10 seconds (64-detector CT) (longer for coronary)	20 seconds	ID + 5 − SD/2 (thoracic aorta, coronary artery); ID + 10 − SD/2 (abdominal aorta)	ID + T_{ARR} − 7 − SD/2 (thoracic aorta, coronary artery; T_{ARR} at ascending aorta); ID + T_{ARR} − 5 − SD/2 (abdominal aorta; T_{ARR} at abdominal aorta)	Essential
Peripheral runoff CT angiography	145–160 mL of 350 mgI/mL at four-detector CT; 125–140 mL at 16- or 64-detector CT	3.5–4 mL/sec or biphasic or exponential decelerated	35 seconds (16- or 64-detector CT); or 15 seconds + SD/2	40 seconds (16- or 64-detector CT)	NA	NA	ID + T_{ARR} − 5 − SD/2 (abdominal aorta, T_{ARR} at abdominal aorta)	Useful
Liver and routine abdomen (hepatic only)	100 mL of 350 mgI/mL (0.5 gI/kg)	4 mL/sec (dual phase); 2–3 mL/sec (hepatic phase only)	25–30 seconds (dual phase); 35–50 seconds (hepatic only); 3–10 minutes (delayed)	20–25 seconds (four-detector CT); 10–15 seconds (16-detector CT); 5–10 seconds (64-detector CT)	30–35 seconds (arterial phase); 65–70 seconds (hepatic)	ID + 10 − SD/2 (arterial); ID + 40 − SD/2 (hepatic)	ID+ T_{ARR} − 5 − SD/2 (arterial, T_{ARR} at abdominal aorta); ID + T_{ARR} + 25 − SD/2 or ID + T_{ARR} × 2 + 10 − SD/2 (hepatic)	Essential (dual phase); not essential (hepatic only)

(Table 1 continues)

Table 1 (Continued)

Key Contrast Material Injection and Scanning Parameters of Common Clinical Protocols

Examination	Typical Contrast Material Dose for 70-kg Patient*	Typical Injection Rate for 70-kg Patient†	Injection Duration	Scan Duration	Fixed (Constant) Scan Delay	Variable Scan Delay‡	Circulation-adjusted Scan Delay‡	Saline Flush
Pancreas	100–120 mL of 350 mgI/mL for dual phase; 120–140 mL for single combined phase	4–5 mL/sec (dual phase); 2.5–3 mL/sec (single phase)	25–30 seconds (dual phase); 50 seconds (single phase)	20–25 seconds (four-detector CT); 10–15 seconds (16-detector CT); 5–10 seconds (64-detector CT)	35–40 seconds (pancreatic phase); 65–70 seconds (hepatic); 60 seconds (single phase)	ID + 15 − SD/2 (pancreatic phase); ID + 40 − SD/2 (hepatic)	ID + T_{ARR} − SD/2 (pancreatic; T_{ARR} at abdominal aorta); ID+ T_{ARR} + 25 − SD/2 or ID + T_{ARR} × 2 + 10 − SD/2 (hepatic)	Essential (dual phase); not essential (single phase)
Kidney	100–120 mL of 350 mgI/mL	4 mL/sec (CM phase); 2.5–3 mL/sec (no CM phase)	25–30 seconds (CM phase); 30–50 seconds (no CM phase)	20–25 seconds (four-detector CT); 10–15 seconds (16-detector CT); 5–10 seconds (64-detector CT)	35–45 seconds (CM phase); 75–90 seconds (NG phase); 10 minutes (UG phase)	ID + 15 − SD/2 (CM phase); ID + 55 − SD/2 (NG phase)	ID + T_{ARR} − SD/2 (CM, T_{ARR} at abdominal aorta); ID + T_{ARR} × 3 + 10 − SD/2 (NG phase)	Essential (CM phase)

Note.—Choice of contrast medium concentration is arbitrary. A variety of concentrations and volumes can be used to deliver the same amount of iodine. CM = corticomedullary, ID = injection duration, MDCT = multidetector CT, NA = not applicable, NG = nephrographic, SD = scan duration, SDCT = single-detector CT, T_{ARR} = contrast material arrival time, UG = urographic.

* Data in parentheses are weight-based doses. mgI/mL = milligrams of iodine per milliliter; gI/kg = grams of iodine per kilogram of body weight.

† For a fixed injection duration protocol, the injection rate should be increased for a large patient to deliver a large amount of iodine or decreased for a small patient to deliver a small amount of iodine.

‡ For the background and rationale for the determination of scan delays, please refer to Appendix E1 (online).

§ Given a wide range of fixed scan delays, the choice of scan delays depends on the diagnostic application, a shorter delay for arterial enhancement and a longer delay for soft-tissue and venous enhancement.

required. Bolus tracking begins with the acquisition of a precontrast image at a selected reference level in the topogram and the placement of a region of interest on a target vessel or organ on a reference image. At the beginning of the contrast medium injection, one technologist typically stays with the patient in the CT scanner room, checks the integrity of the injection site, and confirms the absence of contrast medium extravasation, or, alternatively, an automated sensing technology may be used. As soon as this technologist leaves the scanner room, the first low-radiation-dose monitoring acquisition of the bolus tracking is obtained 5–10 seconds after the start of injection. Then, sequential monitoring acquisitions are acquired every 1–3 seconds at a fixed scanning level. Contrast enhancement within the region of interest is measured automatically on each image and is graphically displayed on the CT scanner computer monitor. When contrast enhancement exceeds a predetermined threshold (eg, 50–150 HU), the monitoring acquisition terminates. The diagnostic CT scan begins after an additional trigger delay (or diagnostic delay), which is either preprogrammed prior to CT or determined by the technologist who initiates the diagnostic CT scan (Fig 13).

The bolus-tracking method permits more efficient use of contrast medium than the test-bolus method because the latter requires two separate contrast material injections and involves additional examination time (61,200–202). The bolus-tracking method is governed by two parameters, enhancement threshold and posttrigger delay. Commonly used enhancement threshold values are 50–150 HU. A threshold that is too low (<30 HU) may not be reliable because a low enhancement threshold may not be easily discernible from artifactual fluctuations in attenuation measurement. A threshold that is too high (eg, liver > 100 HU or aorta > 300 HU) is not practical; it may take too long to reach the threshold, resulting in a long scan delay and inappropriate diagnostic enhancement, or contrast enhancement may never reach the threshold (65,

Table 2

Key Contrast Material Injection and Scanning Parameters of Three Common CT Angiographic Protocols for Three Body Weight Groups

Variable	Single-Detector CT	Four-Detector CT	16-Detector CT	64-Detector CT
Pulmonary CT angiography				
Scan duration (sec)	Too slow to use	20–30	8–15	5–7
Injection duration (sec)*				
<60 kg		30 (4)	25 (4)	20 (4)
60–90 kg		30 (4.5)	25 (4.5)	20 (4.5)
>90 kg		30 (5)	25 (5)	20 (5.5)
Fixed scan delay (sec)		15	15–20	20
Adjusted scan delay (bolus tracking 100 HU at pulmonary artery; first scan at 10 seconds after start of injection)		T_{ARR} + 5 seconds	T_{ARR} + 5 seconds	T_{ARR} + 10 seconds
Aortic CT angiography				
Scan duration (sec)	30–40	15–20	5–10	3–5
Injection duration (sec)*				
<60 kg	35 (4)	25 (4)	20 (4)	15 (4.5)
60–90 kg	35 (4.5)	25 (4.5)	20 (4.5)	15 (5)
>90 kg	35 (5)	25 (5)	20 (5)	15 (5.5)
Fixed scan delay (sec)	20	20	20	20
Adjusted scan delay (bolus tracking 50–100 HU at aorta)	T_{ARR} + 5 seconds	T_{ARR} + 5 seconds	T_{ARR} + 5 seconds	T_{ARR} + 5 seconds
Peripheral runoff CT angiography†			Slow Circulation	Normal Circulation
Scan duration (sec)	Too slow to use	40–60	40	20–30
Injection duration (sec)*				
<60 kg		40 (4)	35 (3.5)	25 (4)
60–90 kg		40 (4.5)	35 (4)	25 (5)
90 kg		40 (5)	35 (4.5)	25 (6)
Fixed scan delay (sec)		NA	NA	NA
Adjusted scan delay (bolus tracking 50–100 HU at aorta)		T_{ARR} + 10 seconds	T_{ARR} + 10 seconds	T_{ARR} + 10 seconds

Note.—NA = not applicable, T_{ARR} = contrast material arrival time.

*Concentration is 350 mg/mL. Data in parentheses are injection rates in milliliters per second. mgI/mL = milligrams of iodine per milliliter.

†Data for peripheral runoff CT angiography in the 16- and 64-detector CT columns are for either 16- or 64-detector CT. Data in the 16-detector column are for patients with slow circulation and data in the 64-detector column are for patients with normal circulation.

203,204). When the bolus-tracking region of interest is monitored over a solid organ, the amount of administered contrast medium should be sufficiently high or adjusted to patient's body weight to reach a predetermined threshold enhancement. When the bolus-tracking region of interest is monitored over the artery for CT angiographic applications, thresholds of 50–150 HU should be consistently reached. A lower threshold will result in an earlier trigger, typically 2 seconds earlier with 50 HU than with 100 HU in the aorta. A common error when using a bolus-tracking technique is incorrect placement of a region of interest over a nontarget structure (eg, nonvascular structure for CT angiography).

Some radiologists prefer to use the test-bolus method instead of the bolus-tracking method, particularly for cardiac CT angiographic examinations. The test-bolus injection provides an additional opportunity to test the integrity of the venous access site and determine if the patient's heart rate remains steady or changes with breath holding during the contrast material injection prior to deciding on the use of β-blockers. Another situation in which the test bolus is more appropriate than the bolus tracking is when performing a very short injection (an injection duration < 10 seconds). A short injection results in narrowly peaked vascular enhancement. In this setting, there may not be sufficient time for the bolus tracking to trigger and scan during the peak enhancement. Finally, the test-bolus injection technique provides the time-enhancement information from the injection which is crucial for mathematical modeling of an individual patient's cardiovascular and contrast medium pharmacokinetic response, which can then be used to optimally adjust the diagnostic contrast material bolus shape at CT angiography (142,205,206).

The time determined by the test-bolus or bolus-tracking techniques simply represents the time of contrast material arrival or contrast material bolus transit (18,199). This time should not be simply assumed to serve as the scan delay but rather as a means of individualizing the scan delay relative to it by including an adequate posttrigger delay (or diagnostic delay) (18,156). This requirement of posttrigger delay for optimizing the scan delay is particularly critical for fast multidetector CT. Contrast material arrival time measured by

using bolus tracking with a 50-HU threshold of the aortic enhancement is likely equivalent to the time to peak test-bolus enhancement measured with the test-bolus technique. Then, the scan delay is determined to be the sum of contrast material arrival time plus the posttrigger delay. The posttrigger delay depends on several factors including the injection duration, scan duration, hemodynamics, and location of target organ, which will be discussed in the next sections. Note that, despite well-designed posttrigger delay, some older generation CT scanners are limited and require intrinsically long posttrigger delays that prevent the diagnostic acquisition from starting quickly during the appropriate early contrast enhancement.

Key points.—1. Contrast material arrival time can be estimated either by using a test-bolus or bolus-tracking method.

2. Contrast material arrival time should not be simply assumed to serve as the scan delay, particularly for fast multidetector CT. It should be used as a means of individualizing the scan delay (scan delay = contrast material arrival time + posttrigger delay).

3. Some multidetector CT applications may require long posttrigger delays that prevent the diagnostic acquisition from starting quickly during the appropriate early contrast enhancement. The magnitude of posttrigger delay depends on the injection duration, scan duration, and location of target organ.

Time to Peak Contrast Enhancement

The time to peak contrast enhancement (T_{PEAK}) can be empirically estimated as the sum of the injection duration (T_{ID}) plus contrast material transit time (T_{CTT}) from the injection to a target organ: $T_{PEAK} = T_{ID} + T_{CTT}$ (18). T_{CTT} in turn depends on T_{ID}, contrast material arrival time (T_{ARR}), and circulation path to the target organ. When cardiac output and circulation are within a normal range, T_{ARR} at a target organ from the injection can be predicted on the basis of normal circulation mean transit time (85); the normal T_{ARR} for a contrast material bolus to transit from an antecubital injection to a number of key organs ranges 7–10 seconds for the pulmonary artery, 12–15 seconds for the ascending aorta, 15–18 seconds for the abdominal aorta, and 30–40 seconds for hepatic parenchyma. T_{ARR} of the hepatic parenchyma (because of the portal circulation) is approximately twice that of the abdominal aorta (33,62). This is an important factor in the estimation of scan delay for hepatic phase enhancement at dual-phase hepatic CT imaging. T_{ARR} increases or decreases inversely proportional to the cardiac output, that is, higher T_{ARR} with lower cardiac output (34).

For a short injection of contrast medium (eg, a test bolus, injection duration < 15 seconds), T_{PEAK} is determined predominantly by T_{ARR} and with a fractional contribution of T_{ID}. This relationship may be expressed in a simple formula, $T_{PEAK} = T_{ARR} + T_{ID}/2$, which has been commonly used for the determination of scan delay for MR angiography (18). However, for a typical injection of contrast medium for diagnostic CT applications (injection duration ≥ 15 seconds), T_{PEAK} is dominated by T_{ID} and determinated with a fractional contribution of T_{ARR}: $T_{PEAK} = T_{ID}$ + fractional T_{ARR}. Furthermore, as T_{ID} increases, the T_{ARR} contribution is reduced because the long injection perturbs the hemodynamics and accelerates the delivery of contrast medium with shortened T_{ARR}, particularly in the upstream circulation before bolus dispersion is pronounced (ie, pulmonary artery and aorta) (more discussion in the distribution of contrast medium section). Hence, T_{PEAK} for pulmonary CT angiography may correspond to $T_{ID} + T_{ARR} - 5$ (T_{ARR} measured at the main pulmonary artery). T_{PEAK} for abdominal aortic CT angiography is also determined by the same equation, $T_{ID} + T_{ARR} - 5$ (at this time, T_{ARR} measured at the abdominal aorta). When dual-phase hepatic CT is performed with T_{ARR} measured at the abdominal aorta, T_{PEAK} for the arterial phase scan corresponds to $T_{ID} + T_{ARR} - 5$, while T_{PEAK} for the hepatic phase scan (accounting for portal circulatory delay) corresponds to $T_{ID} + T_{ARR} + 25$ or $T_{ID} + 2 \cdot T_{ARR} + 5$. More information on the application-specific peak enhancement timing and scan delays is presented in the clinical considerations section in Appendix E1 (online).

Scan Delay

To image each target organ at its peak contrast enhancement, the CT scan should be delayed appropriately (Fig 14). Scanning too early with a short scan delay would result in a subpeak enhancement, whereas scanning too late with a long scan delay would miss an appropriate peak enhancement. Scan delay should be determined by considering three key factors: *(a)* contrast medium injection duration, *(b)* contrast medium arrival time, and *(c)* scan duration. With a short-duration injection, contrast enhancement peaks early and requires a short delay for CT scanning (Fig 8). Contrast material arrival time should be computed to compensate for individual patients' variation in cardiovascular circulation time (Fig 7). Thus, the time to peak enhancement at each target organ is determined as a function of the injection duration and contrast material arrival time from injection site to the target organ (18). When the time-enhancement curve is modeled as a broadened Gaussian-curve shape, ideal scan timing ensures that the center of the scan is at the peak of contrast enhancement; scan delay is calculated to be equal to the time to peak enhancement minus half the scan duration (Fig 13).

Our proposed scheme for computing scan delay (T_{DELAY}) has two steps: *(a)* determine the time to peak contrast enhancement (T_{PEAK}) in a target organ as a function of injection duration (T_{ID}) and T_{ARR} and *(b)* set the scan delay equal to the estimated peak enhancement time minus half the scan duration (T_{SD}):

$$T_{DELAY} = T_{PEAK} - (1/2) \cdot T_{SD}. \qquad (4)$$

It is evident from Equation (4) that for a given time to peak enhancement, scan delay should increase for shorter scan durations (a longer delay with a faster scan). This empirical scheme of subtracting one-half of the scan

Figure 15

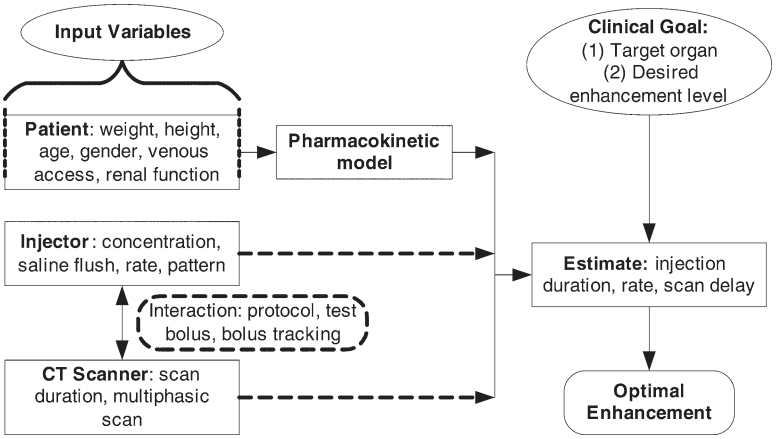

Figure 15: Flowchart illustrates a scheme to integrate various contrast medium injection and scan timing factors to optimize contrast enhancement. The use of computer modeling and intelligent software facilitates communication between the injector and the scanner and integrates patient demographic information from a clinical database, scanning parameters, and contrast medium injection parameters. The information obtained from a test-bolus or bolus-tracking technique may be also incorporated. The computerized system will assist to minimize errors or guesswork by a technologist, optimize the injection protocol or parameters, and achieve a desirable organ-specific contrast enhancement for a given patient and clinical application.

duration or positioning the scan midpoint at the peak enhancement seems reasonable and may work well with fast multidetector CT, particularly when the enhancement curve is largely symmetric in shape (eg, aortic enhancement obtained with a very short injection). The equation may require modification for a scan that is slow and is performed with a long injection of contrast medium. In this situation, T_{SD} and the time to peak enhancement increase, and the contrast enhancement curve broadens and becomes more asymmetric in shape. Thus, to achieve good enhancement throughout a long CT scanning, one may opt to start the scan early by subtracting more than one-half of scan duration (eg, $T_{DELAY} = T_{PEAK} - (2/3) \cdot T_{SD}$). Various formulations of scan delay have been proposed in the literature (18).

Key points.—1. Time to peak contrast enhancement is determined by relative contributions of the injection duration and the contrast material arrival time.

2. Scan delays should be determined by considering three factors: contrast material injection duration, contrast material arrival time, and scan duration.

3. Contrast material arrival time measured with the test-bolus or bolus-tracking method is used to compensate for individual patient's circulation variation in determining the scan delay.

4. We propose an empirical scheme for determining the scan delay (T_{DELAY}) calculated to be equal to the estimated peak enhancement time (T_{PEAK}) minus half the scan duration (T_{SD}): $T_{DELAY} = T_{PEAK} - (1/2) \cdot T_{SD}$.

Clinical Considerations

The clinical goal of contrast medium administration and CT scan timing is to achieve diagnostically adequate contrast enhancement in a target organ while using the lowest radiation exposure (the shortest scan duration) and the least amount of iodine mass injected at the lowest acceptable rate for a given patient's cardiovascular and renal function. In this section, on the basis of basic principles and analysis of the factors, we propose clinical considerations and modifications to protocol design that are necessary to optimize contrast enhancement in common clinical CT applications: CT imaging of brain parenchyma, CT imaging of neck soft tissue, neck and brain CT angiography, perfusion CT, routine chest CT imaging, pulmonary CT angiography, aortic and coronary CT angiography, peripheral CT angiography, and CT imaging of the liver, pancreas, and kidney. For each application, the current status is reviewed, and schemes for organ-specific contrast enhancement optimization are presented. Given limited printed space, the entire section is placed in Appendix E1 (online).

The key contrast material injection and scanning parameters of these protocols are summarized in Tables 1 and 2.

Future Technology Considerations

From the foregoing discussion, it is evident that multiple factors affect intravenous contrast medium enhancement and scan timing. With multidetector CT, contrast material administration and CT scan protocols have become more complex and challenging. We believe these technical challenges will be overcome through the use of computer modeling and intelligent software that facilitates communication between the injector and the scanner and that integrates the patient's demographic information from clinical database, scan parameters, and injection parameters. The information obtained from a test-bolus or bolus-tracking technique may be also incorporated. The computerized system will assist to minimize errors or guesswork by a technologist, optimize the injection protocol or parameters, and achieve a desirable organ-specific contrast enhancement for a given patient and clinical application. On the basis of the computer output, a radiologist may alter the protocol if necessary or ask the computer to determine the protocol of contrast medium administration needed to achieve a desired result.

We envision that the connectivity and information exchange between the scanner and injector will help store the contrast material injection and scan protocols and advance optimization and

automation of contrast enhancement and scan timing by means of a user-friendly, interactive operation (Fig 15). Successful implementation of this computerized operation will allow us to optimize the scan delay after the initiation of contrast medium injection, modify injection profile, start saline injection, and terminate injection seamlessly with minimum human intervention. We believe our continued endeavors to individualize contrast medium administration and scan timing for each patient undergoing CT will contribute to the improvement of patient care and to our practice of personalized medicine in radiology.

Summary

We have reviewed contrast medium pharmacokinetics and patient, contrast medium, and CT scanning factors associated with contrast enhancement and scan timing and discussed clinical considerations and modifications in protocols required to optimize contrast enhancement for common clinical CT applications. With its dramatically shorter image acquisition times, multidetector CT allows us to acquire images with high spatial resolution at multiple precisely defined phases of contrast enhancement. To achieve the full benefits of multidetector CT, however, we must be aware that contrast material administration and scan timing protocols need to be optimized by taking into consideration multiple interrelated factors affecting contrast enhancement and timing, as well as the specific objectives of each clinical imaging application.

Acknowledgments: I am grateful to the Radiological Society of North America for stimulating me to pursue research in this field. I thank John F. Kalafut, MS, who is currently working on his PhD dissertation in this field, for his scientific insight and in-depth discussion with me while I was preparing the manuscript. I thank Bumwoo Park, MS, for helping me polish the user interface of the computer modeling program.

References

1. Berland LL. Slip-ring and conventional dynamic hepatic CT: contrast material and timing considerations. Radiology 1995;195(1):1–8.
2. Bae KT, Heiken JP, Brink JA. Aortic and hepatic contrast medium enhancement at CT. I. Prediction with a computer model. Radiology 1998;207(3):647–655.
3. Huda W, Scalzetti EM, Levin G. Technique factors and image quality as functions of patient weight at abdominal CT. Radiology 2000;217(2):430–435.
4. McCollough CH, Bruesewitz MR, Vrtiska TJ, et al. Image quality and dose comparison among screen-film, computed, and CT scanned projection radiography: applications to CT urography. Radiology 2001;221(2):395–403.
5. Miles KA. Functional CT imaging in stroke and oncology. In: Marchal G, Vogl TJ, Heiken JP, Rubin GD, eds. Multidetector-row computed tomography: scanning and contrast protocols. New York, NY: Springer, 2005;109–112.
6. Wintersperger B, Jakobs T, Herzog P, et al. Aorto-iliac multidetector-row CT angiography with low kV settings: improved vessel enhancement and simultaneous reduction of radiation dose. Eur Radiol 2005;15(2):334–341.
7. Wintermark M, Maeder P, Verdun FR, et al. Using 80 kVp versus 120 kVp in perfusion CT measurement of regional cerebral blood flow. AJNR Am J Neuroradiol 2000;21(10):1881–1884.
8. Boone JM, Geraghty EM, Seibert JA, Wootton-Gorges SL. Dose reduction in pediatric CT: a rational approach. Radiology 2003;228(2):352–360.
9. Siegel MJ, Schmidt B, Bradley D, Suess C, Hildebolt C. Radiation dose and image quality in pediatric CT: effect of technical factors and phantom size and shape. Radiology 2004;233(2):515–522.
10. Ben Saad M, Rohnean A, Sigal-Cinqualbre A, Adler G, Paul JF. Evaluation of image quality and radiation dose of thoracic and coronary dual-source CT in 110 infants with congenital heart disease. Pediatr Radiol 2009;39(7):668–676.
11. Sigal-Cinqualbre AB, Hennequin R, Abada HT, Chen X, Paul JF. Low-kilovoltage multidetector row chest CT in adults: feasibility and effect on image quality and iodine dose. Radiology 2004;231(1):169–174.
12. Nakayama Y, Awai K, Funama Y, et al. Abdominal CT with low tube voltage: preliminary observations about radiation dose, contrast enhancement, image quality, and noise. Radiology 2005;237(3):945–951.
13. Meyer BC, Werncke T, Hopfenmüller W, Raatschen HJ, Wolf KJ, Albrecht T. Dual energy CT of peripheral arteries: effect of automatic bone and plaque removal on image quality and grading of stenoses. Eur J Radiol 2008;68(3):414–422.
14. Takahashi N, Hartman RP, Vrtiska TJ, et al. Dual-energy CT iodine-subtraction virtual unenhanced technique to detect urinary stones in an iodine-filled collecting system: a phantom study. AJR Am J Roentgenol 2008;190(5):1169–1173.
15. Grosjean R, Sauer B, Guerra RM, et al. Characterization of human renal stones with MDCT: advantage of dual energy and limitations due to respiratory motion. AJR Am J Roentgenol 2008;190(3):720–728.
16. Graser A, Johnson TR, Chandarana H, Macari M. Dual energy CT: preliminary observations and potential clinical applications in the abdomen. Eur Radiol 2009;19(1):13–23.
17. Yankelevitz DF, Shaham D, Shah A, Rademacker J, Henschke CI. Optimization of contrast delivery for pulmonary CT angiography. Clin Imaging 1998;22(6):398–403.
18. Bae KT. Peak contrast enhancement in CT and MR angiography: when does it occur and why? pharmacokinetic study in a porcine model. Radiology 2003;227(3):809–816.
19. Fleischmann D. Use of high-concentration contrast media in multiple-detector-row CT: principles and rationale. Eur Radiol 2003;13(suppl 5):M14–M20.
20. Awai K, Hatcho A, Nakayama Y, et al. Simulation of aortic peak enhancement on MDCT using a contrast material flow phantom: feasibility study. AJR Am J Roentgenol 2006;186(2):379–385.
21. Awai K, Nakayama Y, Nakaura T, et al. Prediction of aortic peak enhancement in monophasic contrast injection protocols at multidetector CT: phantom and patient studies. Radiat Med 2007;25(1):14–21.
22. Schindera ST, Nelson RC, Howle L, Nichols E, DeLong DM, Merkle EM. Effect of varying injection rates of a saline chaser on aortic enhancement in CT angiography: phantom study. Eur Radiol 2008;18(8):1683–1689.
23. Behrendt FF, Bruners P, Kalafut J, et al. Introduction of a dedicated circulation phantom for comprehensive in vitro analysis of intravascular contrast material application. Invest Radiol 2008;43(10):729–736.
24. Blomley MJ, Dawson P. Contrast agent pharmacokinetics revisited: II. Computer-aided analysis. Acad Radiol 1996;3(suppl 2):S264–S267.
25. Krause W. Application of pharmacokinetics to computed tomography: injection rates and schemes— mono-, bi-, or multiphasic? Invest Radiol 1996;31(2):91–100.

26. Krause W. Delivery of diagnostic agents in computed tomography. Adv Drug Deliv Rev 1999;37(1-3):159–173.

27. Kim S, Kim JH, Han JK, Lee KH, Min BG. Prediction of optimal injection protocol for tumor detection in contrast-enhanced dynamic hepatic CT using simulation of lesion-to-liver contrast difference. Comput Med Imaging Graph 2000;24(5):317–327.

28. Dawson P, Blomley M. The value of mathematical modelling in understanding contrast enhancement in CT with particular reference to the detection of hypovascular liver metastases. Eur J Radiol 2002;41(3):222–236.

29. Schöber W, Kopp A, Scherf C, et al. Clinical evaluation of a computer simulated prediction model of contrast enhancement of the liver in spiral CT. Eur J Radiol 2004; 51(1):19–26.

30. Yamaguchi I, Hayashi H, Suzuki M, Ichikawa K, Kidoya E, Kimura H. Operation of bolus tracking system for prediction of aortic peak enhancement at multidetector row computed tomography: pharmacokinetic analysis and clinical study. Radiat Med 2008;26(5): 278–286.

31. Bae KT, Tran HQ, Heiken JP. Multiphasic injection method for uniform prolonged vascular enhancement at CT angiography: pharmacokinetic analysis and experimental porcine model. Radiology 2000;216(3):872–880.

32. Bae KT, Tran HQ, Heiken JP. Uniform vascular contrast enhancement and reduced contrast medium volume achieved by using exponentially decelerated contrast material injection method. Radiology 2004;231(3): 732–736.

33. Bae KT, Heiken JP, Brink JA. Aortic and hepatic peak enhancement at CT: effect of contrast medium injection rate—pharmacokinetic analysis and experimental porcine model. Radiology 1998;206(2):455–464.

34. Bae KT, Heiken JP, Brink JA. Aortic and hepatic contrast medium enhancement at CT. II. Effect of reduced cardiac output in a porcine model. Radiology 1998;207(3):657–662.

35. Han JK, Choi BI, Kim AY, Kim SJ. Contrast media in abdominal computed tomography: optimization of delivery methods. Korean J Radiol 2001;2(1):28–36.

36. Yamaguchi I, Kidoya E, Suzuki M, Kimura H. Evaluation of required saline volume in dynamic contrast-enhanced computed tomography using saline flush technique. Comput Med Imaging Graph 2009;33(1): 23–28.

37. Han JK, Kim AY, Lee KY, et al. Factors influencing vascular and hepatic enhancement at CT: experimental study on injection protocol using a canine model. J Comput Assist Tomogr 2000;24(3):400–406.

38. Cademartiri F, van der Lugt A, Luccichenti G, Pavone P, Krestin GP. Parameters affecting bolus geometry in CTA: a review. J Comput Assist Tomogr 2002;26(4):598–607.

39. Hsu RM. Computed tomographic angiography: conceptual review of injection and acquisition parameters with a brief overview of rendering technique. Appl Radiol 2002;31 (6 suppl):33–39.

40. Bae KT. Technical aspects of contrast delivery in advanced CT. Appl Radiol 2003;32 (suppl):12–19.

41. Kormano M, Partanen K, Soimakallio S, Kivimäki T. Dynamic contrast enhancement of the upper abdomen: effect of contrast medium and body weight. Invest Radiol 1983;18(4):364–367.

42. Heiken JP, Brink JA, McClennan BL, Sagel SS, Crowe TM, Gaines MV. Dynamic incremental CT: effect of volume and concentration of contrast material and patient weight on hepatic enhancement. Radiology 1995; 195(2):353–357.

43. Platt JF, Reige KA, Ellis JH. Aortic enhancement during abdominal CT angiography: correlation with test injections, flow rates, and patient demographics. AJR Am J Roentgenol 1999;172(1):53–56.

44. Berland LL, Lee JY. Comparison of contrast media injection rates and volumes for hepatic dynamic incremented computed tomography. Invest Radiol 1988;23(12):918–922.

45. Yamashita Y, Komohara Y, Takahashi M, et al. Abdominal helical CT: evaluation of optimal doses of intravenous contrast material—a prospective randomized study. Radiology 2000;216(3):718–723.

46. Takeshita K. Prediction of maximum hepatic enhancement on computed tomography from dose of contrast material and patient weight: proposal of a new formula and evaluation of its accuracy. Radiat Med 2001; 19(2):75–79.

47. Awai K, Hori S. Effect of contrast injection protocol with dose tailored to patient weight and fixed injection duration on aortic and hepatic enhancement at multidetector-row helical CT. Eur Radiol 2003;13(9): 2155–2160.

48. Schoellnast H, Deutschmann HA, Berghold A, Fritz GA, Schaffler GJ, Tillich M. MDCT angiography of the pulmonary arteries: influence of body weight, body mass index, and scan length on arterial enhancement at different iodine flow rates. AJR Am J Roentgenol 2006;187(4):1074–1078.

49. Bae KT, Tao C, Gürel S, et al. Effect of patient weight and scanning duration on contrast enhancement during pulmonary multidetector CT angiography. Radiology 2007; 242(2):582–589.

50. Ho LM, Nelson RC, Delong DM. Determining contrast medium dose and rate on basis of lean body weight: does this strategy improve patient-to-patient uniformity of hepatic enhancement during multi-detector row CT? Radiology 2007;243(2):431–437.

51. Kondo H, Kanematsu M, Goshima S, et al. Abdominal multidetector CT in patients with varying body fat percentages: estimation of optimal contrast material dose. Radiology 2008;249(3):872–877.

52. Bae KT, Seeck BA, Hildebolt CF, et al. Contrast enhancement in cardiovascular MDCT: effect of body weight, height, body surface area, body mass index, and obesity. AJR Am J Roentgenol 2008;190(3):777–784.

53. Yanaga Y, Awai K, Nakaura T, et al. Effect of contrast injection protocols with dose adjusted to the estimated lean patient body weight on aortic enhancement at CT angiography. AJR Am J Roentgenol 2009; 192(4):1071–1078.

54. Guyton AC. Circulatory physiology: cardiac output and its regulation. Philadelphia, Pa: Saunders, 1963.

55. Milnor WR. Cardiovascular physiology. Oxford, England: Oxford University Press, 1990.

56. Nadler SB, Hidalgo JU. Blood volume. In: Sevelius G, ed. Radioisotopes and circulation. Boston, Mass: Little, Brown, 1965.

57. Livingston EH, Lee S. Body surface area prediction in normal-weight and obese patients. Am J Physiol Endocrinol Metab 2001;281(3):E586–E591.

58. Tatsugami F, Husmann L, Herzog BA, et al. Evaluation of a body mass index-adapted protocol for low-dose 64-MDCT coronary angiography with prospective ECG triggering. AJR Am J Roentgenol 2009;192(3):635–638.

59. van Hoe L, Marchal G, Baert AL, Gryspeerdt S, Mertens L. Determination of scan delay time in spiral CT-angiography: utility of a test bolus injection. J Comput Assist Tomogr 1995;19(2):216–220.

60. Puskás Z, Schuierer G. Determination of blood circulation time for optimizing contrast medium administration in CT angiography [in German]. Radiologe 1996;36(9): 750–757.

61. Kirchner J, Kickuth R, Laufer U, Noack M, Liermann D. Optimized enhancement in helical CT: experiences with a real-time bolus tracking system in 628 patients. Clin Radiol 2000;55(5):368–373.

62. Chu LL, Joe BN, Westphalen ACA, Webb EM, Coakley FV, Yeh BM. Patient-specific time to peak abdominal organ enhancement varies with time to peak aortic enhancement at MR imaging. Radiology 2007; 245(3):779–787.

63. Husmann L, Alkadhi H, Boehm T, et al. Influence of cardiac hemodynamic parameters on coronary artery opacification with 64-slice computed tomography. Eur Radiol 2006;16(5):1111–1116.

64. Becker CR. The use of contrast media in cardiac CT. Appl Radiol 2003;32(suppl): 50–56.

65. Manghat NE, Morgan-Hughes GJ, Shaw SR, Marshall AJ, Roobottom CA. Impaired left ventricular function has a detrimental effect on image quality in multi-detector row CT coronary angiography. Clin Radiol 2008; 63(4):415–423.

66. Prince MR, Chabra SG, Watts R, et al. Contrast material travel times in patients undergoing peripheral MR angiography. Radiology 2002;224(1):55–61.

67. Fleischmann D, Rubin GD. Quantification of intravenously administered contrast medium transit through the peripheral arteries: implications for CT angiography. Radiology 2005;236(3):1076–1082.

68. Turk AS, Grayev A, Rowley HA, et al. Variability of clinical CT perfusion measurements in patients with carotid stenosis. Neuroradiology 2007;49(11):955–961.

69. Waaijer A, van Leeuwen MS, van Osch MJ, et al. Changes in cerebral perfusion after revascularization of symptomatic carotid artery stenosis: CT measurement. Radiology 2007;245(2):541–548.

70. Suzuki H, Oshima H, Shiraki N, Ikeya C, Shibamoto Y. Comparison of two contrast materials with different iodine concentrations in enhancing the density of the the aorta, portal vein and liver at multi-detector row CT: a randomized study. Eur Radiol 2004;14(11):2099–2104.

71. Bader TR, Prokesch RW, Grabenwöger F. Timing of the hepatic arterial phase during contrast-enhanced computed tomography of the liver: assessment of normal values in 25 volunteers. Invest Radiol 2000;35(8): 486–492.

72. Kim MJ, Choi JY, Lim JS, et al. Optimal scan window for detection of hypervascular hepatocellular carcinomas during MDCT examination. AJR Am J Roentgenol 2006; 187(1):198–206.

73. Katori R. Normal cardiac output in relation to age and body size. Tohoku J Exp Med 1979;128(4):377–387.

74. Nakajima Y, Yoshimine T, Yoshida H, et al. Computerized tomography angiography of ruptured cerebral aneurysms: factors affecting time to maximum contrast concentration. J Neurosurg 1998;88(4):663–669.

75. Birnbaum BA, Jacobs JE, Langlotz CP, Ramchandani P. Assessment of a bolus-tracking technique in helical renal CT to optimize nephrographic phase imaging. Radiology 1999;211(1):87–94.

76. Sandstede JJ, Tschammler A, Beer M, Vogelsang C, Wittenberg G, Hahn D. Optimization of automatic bolus tracking for timing of the arterial phase of helical liver CT. Eur Radiol 2001;11(8):1396–1400.

77. Itoh S, Ikeda M, Satake H, Ota T, Ishigaki T. The effect of patient age on contrast enhancement during CT of the pancreatobiliary region. AJR Am J Roentgenol 2006; 187(2):505–510.

78. Ruess L, Bulas DI, Rivera O, Markle BM. In-line pressures generated in small-bore central venous catheters during power injection of CT contrast media. Radiology 1997;203(3):625–629.

79. Rivitz SM, Drucker EA. Power injection of peripherally inserted central catheters. J Vasc Interv Radiol 1997;8(5):857–863.

80. Herts BR, O'Malley CM, Wirth SL, Lieber ML, Pohlman B. Power injection of contrast media using central venous catheters: feasibility, safety, and efficacy. AJR Am J Roentgenol 2001;176(2):447–453.

81. Sanelli PC, Deshmukh M, Ougorets I, Caiati R, Heier LA. Safety and feasibility of using a central venous catheter for rapid contrast injection rates. AJR Am J Roentgenol 2004;183(6):1829–1834.

82. Claussen CD, Banzer D, Pfretzschner C, Kalender WA, Schörner W. Bolus geometry and dynamics after intravenous contrast medium injection. Radiology 1984;153(2): 365–368.

83. Hittmair K, Fleischmann D. Accuracy of predicting and controlling time-dependent aortic enhancement from a test bolus injection. J Comput Assist Tomogr 2001;25(2): 287–294.

84. Behrendt FF, Bruners P, Keil S, et al. Impact of different vein catheter sizes for mechanical power injection in CT: in vitro evaluation with use of a circulation phantom. Cardiovasc Intervent Radiol 2009;32(1):25–31.

85. Leggett RW, Williams LR. A proposed blood circulation model for Reference Man. Health Phys 1995;69(2):187–201.

86. Tanaka T, Uemura K, Takahashi M, et al. Compression of the left brachiocephalic vein: cause of high signal intensity of the left sigmoid sinus and internal jugular vein on MR images. Radiology 1993;188(2):355–361.

87. Ohtomo K, Baron RL, Dodd GD 3rd, et al. Confluent hepatic fibrosis in advanced cirrhosis: appearance at CT. Radiology 1993; 188(1):31–35.

88. Drop A, Rosińska-Bogusiewicz K, Zbańska-Klonowska K, Czekajska-Chehab E. Dynamic CT of hepatic cirrhosis. Ann Univ Mariae Curie Sklodowska [Med] 2002; 57(2):39–46.

89. Vignaux O, Legmann P, Coste J, Hoeffel C, Bonnin A. Cirrhotic liver enhancement on dual-phase helical CT: comparison with noncirrhotic livers in 146 patients. AJR Am J Roentgenol 1999;173(5):1193–1197.

90. Vignaux O, Gouya H, Augui J, et al. Hepatofugal portal flow in advanced liver cirrhosis with spontaneous portosystemic shunts: effects on parenchymal hepatic enhancement at dual-phase helical CT. Abdom Imaging 2002;27(5):536–540.

91. Holley HC, Koslin DB, Berland LL, Stanley RJ. Inhomogeneous enhancement of liver parenchyma secondary to passive congestion: contrast-enhanced CT. Radiology 1989; 170(3 pt 1):795–800.

92. Gore RM, Mathieu DG, White EM, Ghahremani GG, Panella JS, Rochester D. Passive hepatic congestion: cross-sectional imaging features. AJR Am J Roentgenol 1994;162(1):71–75.

93. McCullough PA, Wolyn R, Rocher LL, Levin RN, O'Neill WW. Acute renal failure after coronary intervention: incidence, risk factors, and relationship to mortality. Am J Med 1997;103(5):368–375.

94. Martin-Paredero V, Dixon SM, Baker JD, et al. Risk of renal failure after major angiography. Arch Surg 1983;118(12):1417–1420.

95. Gomes AS, Baker JD, Martin-Paredero V, et al. Acute renal dysfunction after major arteriography. AJR Am J Roentgenol 1985; 145(6):1249–1253.

96. Lang EK, Foreman J, Schlegel JU, Leslie C, List A, McCormick P. The incidence of contrast medium induced acute tubular necrosis following arteriography. Radiology 1981; 138(1):203–206.

97. Mehta M, Veith FJ, Lipsitz EC, et al. Is elevated creatinine level a contraindication to endovascular aneurysm repair? J Vasc Surg 2004;39(1):118–123.

98. Cigarroa RG, Lange RA, Williams RH, Hillis LD. Dosing of contrast material to prevent contrast nephropathy in patients with renal disease. Am J Med 1989;86(6 pt 1): 649–652.

99. Manske CL, Sprafka JM, Strony JT, Wang Y. Contrast nephropathy in azotemic diabetic patients undergoing coronary angiography. Am J Med 1990;89(5):615–620.

100. Vlietstra RE, Nunn CM, Narvarte J, Browne KF. Contrast nephropathy after coronary angioplasty in chronic renal insufficiency. Am Heart J 1996;132(5):1049–1050.

101. Davidson C, Stacul F, McCullough PA, et al. Contrast medium use. Am J Cardiol 2006; 98(6A):42K–58K.

102. Dean PB, Violante MR, Mahoney JA. Hepatic CT contrast enhancement: effect of dose, duration of infusion, and time elapsed following infusion. Invest Radiol 1980; 15(2):158–161.

103. Heiken JP, Brink JA, McClennan BL, Sagel SS, Forman HP, DiCroce J. Dynamic contrast-enhanced CT of the liver: comparison of contrast medium injection rates and uniphasic and biphasic injection protocols. Radiology 1993;187(2):327–331.

104. Chambers TP, Baron RL, Lush RM. Hepatic CT enhancement. I. Alterations in the volume of contrast material within the same patients. Radiology 1994;193(2):513–517.

105. Kopka L, Rodenwaldt J, Fischer U, Mueller DW, Oestmann JW, Grabbe E. Dual-phase helical CT of the liver: effects of bolus tracking and different volumes of contrast material. Radiology 1996;201(2):321–326.

106. Awai K, Hiraishi K, Hori S. Effect of contrast material injection duration and rate on aortic peak time and peak enhancement at dynamic CT involving injection protocol with dose tailored to patient weight. Radiology 2004;230(1):142–150.

107. Bae KT, Heiken JP. Scan and contrast administration principles of MDCT. Eur Radiol 2005;15(suppl 5):E46–E59.

108. Erturk SM, Ichikawa T, Sou H, Tsukamoto T, Motosugi U, Araki T. Effect of duration of contrast material injection on peak enhancement times and values of the aorta, main portal vein, and liver at dynamic MDCT with the dose of contrast medium tailored to patient weight. Clin Radiol 2008; 63(3):263–271.

109. Small WC, Nelson RC, Bernardino ME, Brummer LT. Contrast-enhanced spiral CT of the liver: effect of different amounts and injection rates of contrast material on early contrast enhancement. AJR Am J Roentgenol 1994;163(1):87–92.

110. Freeny PC, Gardner JC, vonIngersleben G, Heyano S, Nghiem HV, Winter TC. Hepatic helical CT: effect of reduction of iodine dose of intravenous contrast material on hepatic contrast enhancement. Radiology 1995;197(1):89–93.

111. Megibow AJ, Jacob G, Heiken JP, et al. Quantitative and qualitative evaluation of volume of low osmolality contrast medium needed for routine helical abdominal CT. AJR Am J Roentgenol 2001;176(3):583–589.

112. Roos JE, Desbiolles LM, Weishaupt D, et al. Multi-detector row CT: effect of iodine dose reduction on hepatic and vascular enhancement. Rofo 2004;176(4):556–563.

113. Rubin GD, Alfrey EJ, Dake MD, et al. Assessment of living renal donors with spiral CT. Radiology 1995;195(2):457–462.

114. Tello R, Seltzer S. Effects of injection rates of contrast material on arterial phase hepatic CT. AJR Am J Roentgenol 1999; 173(1):237–238.

115. Tublin ME, Tessler FN, Cheng SL, Peters TL, McGovern PC. Effect of injection rate of contrast medium on pancreatic and hepatic helical CT. Radiology 1999;210(1):97–101.

116. Kim T, Murakami T, Takahashi S, et al. Pancreatic CT imaging: effects of different injection rates and doses of contrast material. Radiology 1999;212(1):219–225.

117. Walkey MM. Dynamic hepatic CT: how many years will it take 'til we learn? Radiology 1991;181(1):17–18.

118. Irie T, Suzuki S, Yamauchi T, Kusano S. Prediction of the time to peak hepatic enhancement to optimize contrast-enhanced spiral CT. Acta Radiol 1995;36(2):154–158.

119. Irie T, Kusano S. Contrast-enhanced spiral CT of the liver: effect of injection time on time to peak hepatic enhancement. J Comput Assist Tomogr 1996;20(4):633–637.

120. Tello R, Seltzer SE, Polger M, Spaulding S, Savci G. A contrast agent delivery nomogram for hepatic spiral CT. J Comput Assist Tomogr 1997;21(2):236–245.

121. Kim T, Murakami T, Takahashi S, et al. Effects of injection rates of contrast material on arterial phase hepatic CT. AJR Am J Roentgenol 1998;171(2):429–432.

122. Harmon BH, Berland LL, Lee JY. Effect of varying rates of low-osmolarity contrast media injection for hepatic CT: correlation with indocyanine green transit time. Radiology 1992;184(2):379–382.

123. Chambers TP, Baron RL, Lush RM. Hepatic CT enhancement. Part II. Alterations in contrast material volume and rate of injection within the same patients. Radiology 1994;193(2):518–522.

124. Garcia PA, Bonaldi VM, Bret PM, Liang L, Reinhold C, Atri M. Effect of rate of contrast medium injection on hepatic enhancement at CT. Radiology 1996;199(1): 185–189.

125. Kopka L, Vosshenrich R, Rodenwaldt J, Grabbe E. Differences in injection rates on contrast-enhanced breath-hold three-dimensional MR angiography. AJR Am J Roentgenol 1998;170(2):345–348.

126. Garcia P, Genin G, Bret PM, Bonaldi VM, Reinhold C, Atri M. Hepatic CT enhancement: effect of the rate and volume of contrast medium injection in an animal model. Abdom Imaging 1999;24(6):597–603.

127. Shimizu T, Misaki T, Yamamoto K, Sueyoshi K, Narabayashi I. Helical CT of the liver with computer-assisted bolus-tracking technology: scan delay of arterial phase scanning and effect of flow rates. J Comput Assist Tomogr 2000;24(2):219–223.

128. Becker CR, Hong C, Knez A, et al. Optimal contrast application for cardiac 4-detector-row computed tomography. Invest Radiol 2003;38(11):690–694.

129. Shinagawa M, Uchida M, Ishibashi M, Nishimura H, Hayabuchi N. Assessment of pancreatic CT enhancement using a high concentration of contrast material. Radiat Med 2003;21(2):74–79.

130. Furuta A, Ito K, Fujita T, Koike S, Shimizu A, Matsunaga N. Hepatic enhancement in multiphasic contrast-enhanced MDCT: comparison of high- and low-iodine-concentration contrast medium in same patients with chronic liver disease. AJR Am J Roentgenol 2004; 183(1):157–162.

131. Hu CH, Wu QD, Hu XY, Fang XM, Zhang TH, Ding Y. Hemodynamic studies on brain CT perfusion imaging with varied injection rates. Clin Imaging 2007;31(3):151–154.

132. Miles KA. Perfusion CT for the assessment of tumour vascularity: which protocol? Br J Radiol 2003;76(spec no 1):S36–S42.

133. Yeh BM, Kurzman P, Foster E, Qayyum A, Joe B, Coakley F. Clinical relevance of retrograde inferior vena cava or hepatic vein opacification during contrast-enhanced CT. AJR Am J Roentgenol 2004;183(5):1227–1232.

134. Foley WD, Hoffmann RG, Quiroz FA, Kahn CE Jr, Perret RS. Hepatic helical CT: contrast material injection protocol. Radiology 1994;192(2):367–371.

135. Hänninen EL, Vogl TJ, Felfe R, et al. Detection of focal liver lesions at biphasic spiral CT: randomized double-blind study of the effect of iodine concentration in contrast materials. Radiology 2000;216(2):403–409.

136. Awai K, Imuta M, Utsunomiya D, et al. Contrast enhancement for whole-body screening using multidetector row helical CT: comparison between uniphasic and biphasic injection protocols. Radiat Med 2004; 22(5):303–309.

137. Brink JA, Heiken JP, Forman HP, Sagel SS, Molina PL, Brown PC. Hepatic spiral CT: reduction of dose of intravenous contrast material. Radiology 1995;197(1):83–88.

138. Cademartiri F, Luccichenti G, Marano R, Gualerzi M, Brambilla L, Coruzzi P. Comparison of monophasic vs biphasic administration of contrast material in non-invasive coronary angiography using a 16-row multislice computed tomography. Radiol Med (Torino) 2004;107(5-6):489–496.

139. Utsunomiya D, Awai K, Sakamoto T, et al. Cardiac 16-MDCT for anatomic and functional analysis: assessment of a biphasic contrast injection protocol. AJR Am J Roentgenol 2006;187(3):638–644.

140. Kerl JM, Ravenel JG, Nguyen SA, et al. Right heart: split-bolus injection of diluted contrast medium for visualization at coronary CT angiography. Radiology 2008;247(2):356–364.

141. Cao L, Du X, Li P, Liu Y, Li K. Multiphase contrast-saline mixture injection with dual-flow in 64-row MDCT coronary CTA. Eur J Radiol 2009;69(3):496–499.

142. Fleischmann D, Rubin GD, Bankier AA, Hittmair K. Improved uniformity of aortic enhancement with customized contrast medium injection protocols at CT angiography. Radiology 2000;214(2):363–371.

143. Numburi UD, Chatzimavroudis GP, Stillman AE, et al. Patient-specific contrast injection protocols for cardiovascular multidetector row computed tomography. J Comput Assist Tomogr 2007;31(2):281–289.

144. Rubin GD, Paik DS, Johnston PC, Napel S. Measurement of the aorta and its branches with helical CT. Radiology 1998;206(3):823–829.

145. Lev MH, Gonzalez RG. CT angiography and CT perfusion imaging. In: Toga AW, Mazziotta JC, eds. Brain mapping: the methods. 2nd ed. San Diego, Calif: Academic Press, 2002;427–478.

146. Claves JL, Wise SW, Hopper KD, Tully D, Ten Have TR, Weaver J. Evaluation of contrast densities in the diagnosis of carotid stenosis by CT angiography. AJR Am J Roentgenol 1997;169(2):569–573.

147. Liu Y, Hopper KD, Mauger DT, Addis KA. CT angiographic measurement of the carotid artery: optimizing visualization by manipulating window and level settings and contrast material attenuation. Radiology 2000;217(2):494–500.

148. Funabashi N, Kobayashi Y, Perlroth M, Rubin GD. Coronary artery: quantitative evaluation of normal diameter determined with electron-beam CT compared with cine coronary angiography initial experience. Radiology 2003;226(1):263–271.

149. Hunter GJ, Hamberg LM, Ponzo JA, et al. Assessment of cerebral perfusion and arterial anatomy in hyperacute stroke with three-dimensional functional CT: early clinical results. AJNR Am J Neuroradiol 1998;19(1):29–37.

150. Baker ME, Beam C, Leder R, Gulliver D, Paine SS, Dunnick NR. Contrast material for combined abdominal and pelvic CT: can cost be reduced by increasing the concentration and decreasing the volume? AJR Am J Roentgenol 1993;160(3):637–641.

151. Herts BR, Paushter DM, Einstein DM, Zepp R, Friedman RA, Obuchowski N. Use of contrast material for spiral CT of the abdomen: comparison of hepatic enhancement and vascular attenuation for three different contrast media at two different delay times. AJR Am J Roentgenol 1995;164(2):327–331.

152. Bluemke DA, Fishman EK, Anderson JH. Effect of contrast concentration on abdominal enhancement in the rabbit: spiral computed tomography evaluation. Acad Radiol 1995;2(3):226–231.

153. Loubeyre P, Debard I, Nemoz C, Minh VA. Using thoracic helical CT to assess iodine concentration in a small volume of nonionic contrast medium during vascular opacification: a prospective study. AJR Am J Roentgenol 2000;174(3):783–787.

154. Awai K, Takada K, Onishi H, Hori S. Aortic and hepatic enhancement and tumor-to-liver contrast: analysis of the effect of different concentrations of contrast material at multi-detector row helical CT. Radiology 2002;224(3):757–763.

155. Brink JA. Use of high concentration contrast media (HCCM): principles and rationale—body CT. Eur J Radiol 2003;45(suppl 1):S53–S58.

156. Fleischmann D. High-concentration contrast media in MDCT angiography: principles and rationale. Eur Radiol 2003;13(suppl 3):N39–N43.

157. Fleischmann D. Use of high concentration contrast media: principles and rationale-vascular district. Eur J Radiol 2003;45(suppl 1):S88–S93.

158. Awai K, Inoue M, Yagyu Y, et al. Moderate versus high concentration of contrast material for aortic and hepatic enhancement and tumor-to-liver contrast at multi-detector row CT. Radiology 2004;233(3):682–688.

159. Yagyu Y, Awai K, Inoue M, et al. MDCT of hypervascular hepatocellular carcinomas: a prospective study using contrast materials with different iodine concentrations. AJR Am J Roentgenol 2005;184(5):1535–1540.

160. Schoellnast H, Deutschmann HA, Fritz GA, Stessel U, Schaffler GJ, Tillich M. MDCT angiography of the pulmonary arteries: influence of iodine flow concentration on vessel attenuation and visualization. AJR Am J Roentgenol 2005;184(6):1935–1939.

161. Marchianò A, Spreafico C, Lanocita R, et al. Does iodine concentration affect the diagnostic efficacy of biphasic spiral CT in patients with hepatocellular carcinoma? Abdom Imaging 2005;30(3):274–280.

162. Itoh S, Ikeda M, Achiwa M, Satake H, Ota T, Ishigaki T. Multiphase contrast-enhanced CT of the liver with a multislice CT scanner: effects of iodine concentration and delivery rate. Radiat Med 2005;23(1):61–69.

163. Cademartiri F, Mollet NR, van der Lugt A, et al. Intravenous contrast material administration at helical 16-detector row CT coronary angiography: effect of iodine concentration on vascular attenuation. Radiology 2005;236(2):661–665.

164. Silvennoinen HM, Hamberg LM, Valanne L, Hunter GJ. Increasing contrast agent concentration improves enhancement in first-pass CT perfusion. AJNR Am J Neuroradiol 2007;28(7):1299–1303.

165. König M, Bültmann E, Bode-Schnurbus L, Koenen D, Mielke E, Heuser L. Image quality in CT perfusion imaging of the brain: the role of iodine concentration. Eur Radiol 2007;17(1):39–47.

166. Behrendt FF, Mahnken AH, Stanzel S, et al. Intraindividual comparison of contrast media concentrations for combined abdominal and thoracic MDCT. AJR Am J Roentgenol 2008;191(1):145–150.

167. Keil S, Plumhans C, Behrendt FF, et al. MDCT angiography of the pulmonary arteries: intravascular contrast enhancement does not depend on iodine concentration when injecting equal amounts of iodine at standardized iodine delivery rates. Eur Radiol 2008;18(8):1690–1695.

168. Mühlenbruch G, Behrendt FF, Eddahabi MA, et al. Which iodine concentration in chest CT?: a prospective study in 300 patients. Eur Radiol 2008;18(12):2826–2832.

169. Behrendt FF, Plumhans C, Keil S, et al. Contrast enhancement in chest multidetector computed tomography: intraindividual comparison of 300 mg/ml versus 400 mg/ml iodinated contrast medium. Acad Radiol 2009;16(2):144–149.

170. Bae KT. Comparison of moderate versus high concentration of contrast media injected at the same total iodine dose and fixed injection duration. Radiology 2005;236(2):740–741; author reply 741.

171. Rubin GD, Lane MJ, Bloch DA, Leung AN, Stark P. Optimization of thoracic spiral CT: effects of iodinated contrast medium concentration. Radiology 1996;201(3):785–791.

172. Kern MJ, Roth RA, Aguirre FV, Beauman G, Vogel R. Effect of viscosity and iodine concentration of nonionic radiographic contrast media on coronary arteriography in patients. Am Heart J 1992;123(1):160–165.

173. Knollmann F, Schimpf K, Felix R. Iodine delivery rate of different concentrations of iodine-containing contrast agents with rapid injection [in German]. Rofo 2004;176(6): 880–884.

174. Mitchell DG, Friedman AC. Viscosity of iodinated contrast agents: significance for peripheral venous injection. J Comput Tomogr 1985;9(1):77–78.

175. Brunette J, Mongrain R, Rodés-Cabau J, Larose E, Leask R, Bertrand OF. Comparative rheology of low- and iso-osmolarity contrast agents at different temperatures. Catheter Cardiovasc Interv 2008;71(1):78–83.

176. Hazirolan T, Turkbey B, Akpinar E, et al. The impact of warmed intravenous contrast material on the bolus geometry of coronary CT angiography applications. Korean J Radiol 2009;10(2):150–155.

177. Halsell RD. Heating contrast media: role in contemporary angiography. Radiology 1987; 164(1):276–278.

178. Vergara M, Seguel S. Adverse reactions to contrast media in CT: effects of temperature and ionic property. Radiology 1996;199(2): 363–366.

179. Hopper KD, Mosher TJ, Kasales CJ, TenHave TR, Tully DA, Weaver JS. Thoracic spiral CT: delivery of contrast material pushed with injectable saline solution in a power injector. Radiology 1997;205(1): 269–271.

180. Dorio PJ, Lee FT Jr, Henseler KP, et al. Using a saline chaser to decrease contrast media in abdominal CT. AJR Am J Roentgenol 2003;180(4):929–934.

181. Haage P, Schmitz-Rode T, Hübner D, Piroth W, Günther RW. Reduction of contrast material dose and artifacts by a saline flush using a double power injector in helical CT of the thorax. AJR Am J Roentgenol 2000; 174(4):1049–1053.

182. Irie T, Kajitani M, Yamaguchi M, Itai Y. Contrast-enhanced CT with saline flush technique using two automated injectors: how much contrast medium does it save? J Comput Assist Tomogr 2002;26(2):287–291.

183. Schoellnast H, Tillich M, Deutschmann HA, et al. Abdominal multidetector row computed tomography: reduction of cost and contrast material dose using saline flush. J Comput Assist Tomogr 2003;27(6):847–853.

184. Cademartiri F, Mollet N, van der Lugt A, et al. Non-invasive 16-row multislice CT coronary angiography: usefulness of saline chaser. Eur Radiol 2004;14(2):178–183.

185. Schoellnast H, Tillich M, Deutschmann MJ, Deutschmann HA, Schaffler GJ, Portugaller HR. Aortoiliac enhancement during computed tomography angiography with reduced contrast material dose and saline solution flush: influence on magnitude and uniformity of the contrast column. Invest Radiol 2004;39(1):20–26.

186. Schoellnast H, Tillich M, Deutschmann HA, et al. Improvement of parenchymal and vascular enhancement using saline flush and power injection for multiple-detector-row abdominal CT. Eur Radiol 2004;14(4):659–664.

187. Utsunomiya D, Awai K, Tamura Y, et al. 16-MDCT aortography with a low-dose contrast material protocol. AJR Am J Roentgenol 2006;186(2):374–378.

188. Lee CH, Goo JM, Bae KT, et al. CTA contrast enhancement of the aorta and pulmonary artery: the effect of saline chase injected at two different rates in a canine experimental model. Invest Radiol 2007; 42(7):486–490.

189. Lee CH, Goo JM, Lee HJ, et al. Determination of optimal timing window for pulmonary artery MDCT angiography. AJR Am J Roentgenol 2007;188(2):313–317.

190. Kim DJ, Kim TH, Kim SJ, et al. Saline flush effect for enhancement of aorta and coronary arteries at multidetector CT coronary angiography. Radiology 2008;246(1): 110–115.

191. Behrendt FF, Bruners P, Keil S, et al. Effect of different saline chaser volumes and flow rates on intravascular contrast enhancement in CT using a circulation phantom. Eur J Radiol 2010;73(3):688–693.

192. de Monyé C, Cademartiri F, de Weert TT, Siepman DA, Dippel DW, van Der Lugt A. Sixteen-detector row CT angiography of carotid arteries: comparison of different volumes of contrast material with and without a bolus chaser. Radiology 2005;237(2): 555–562.

193. Freeny PC. Hepatic CT: state of the art. Radiology 1988;168(2):319–323.

194. O'Riordan E, Craven CM, Wilson D, Robinson PJ. Dual phase hepatic CT: influence of scanning direction on liver attenuation. AJR Am J Roentgenol 2000;174(5):1417–1421.

195. Wittram C. How I do it: CT pulmonary angiography. AJR Am J Roentgenol 2007; 188(5):1255–1261.

196. de Monyé C, de Weert TT, Zaalberg W, et al. Optimization of CT angiography of the carotid artery with a 16-MDCT scanner: craniocaudal scan direction reduces contrast material-related perivenous artifacts. AJR Am J Roentgenol 2006;186(6): 1737–1745.

197. Sheiman RG, Raptopoulos V, Caruso P, Vrachliotis T, Pearlman J. Comparison of tailored and empiric scan delays for CT angiography of the abdomen. AJR Am J Roentgenol 1996;167(3):725–729.

198. Cademartiri F, Nieman K, van der Lugt A, et al. Intravenous contrast material administration at 16-detector row helical CT coronary angiography: test bolus versus bolus-tracking technique. Radiology 2004;233(3): 817–823.

199. Bae KT. Test-bolus versus bolus-tracking techniques for CT angiographic timing. Radiology 2005;236(1):369–370; author reply 370.

200. Silverman PM, Brown B, Wray H, et al. Optimal contrast enhancement of the liver using helical (spiral) CT: value of Smart-Prep. AJR Am J Roentgenol 1995;164(5): 1169–1171.

201. Silverman PM, Roberts S, Tefft MC, et al. Helical CT of the liver: clinical application of an automated computer technique, Smart-Prep, for obtaining images with optimal contrast enhancement. AJR Am J Roentgenol 1995;165(1):73–78.

202. Dinkel HP, Fieger M, Knüpffer J, Moll R, Schindler G. Optimizing liver contrast in helical liver CT: value of a real-time bolus-triggering technique. Eur Radiol 1998;8(9): 1608–1612.

203. Paulson EK, Fisher AJ, DeLong DM, Parker DD, Nelson RC. Helical liver CT with computer-assisted bolus-tracking technology: is it possible to predict which patients will not achieve a threshold of enhancement? Radiology 1998;209(3):787–792.

204. Mehnert F, Pereira PL, Trübenbach J, Kopp AF, Claussen CD. Automatic bolus tracking in monophasic spiral CT of the liver: liver-to-lesion conspicuity. Eur Radiol 2001;11(4): 580–584.

205. Rist C, Nikolaou K, Kirchin MA, et al. Contrast bolus optimization for cardiac 16-slice computed tomography: comparison of contrast medium formulations containing 300 and 400 milligrams of iodine per milliliter. Invest Radiol 2006;41(5):460–467.

206. Mahnken AH, Rauscher A, Klotz E, et al. Quantitative prediction of contrast enhancement from test bolus data in cardiac MSCT. Eur Radiol 2007;17(5):1310–1319.