Note: This copy is for your personal non-commercial use only. To order presentation-ready copies for distribution to your colleagues or clients, contact us at *www.rsna.org/rsnarights.*

Arterial Endofibrosis in Endurance Athletes: Angiographic Features and Classification[1]

Olivier Rouvière, MD, PhD
Patrick Feugier, MD, PhD
John Palma Gutiérrez, MD
Jean-Michel Chevalier, MD

Purpose: To describe the spectrum of angiographic features of arterial endofibrosis and to assess the patterns of associated lesions.

Materials and Methods: This retrospective study was compliant with the declaration of Helsinki principles. Files of patients who underwent surgery between January 1998 and December 2009 were retrospectively searched for histologic analysis–proven arterial endofibrosis. Preoperative angiograms were read in consensus by two radiologists. Abnormalities of the common iliac (CIA), external iliac (EIA), and femoral arteries were classified into five types, known as the CEF classification.

Results: This study assessed 180 patients (161 men, 19 women) with 195 symptomatic limbs (136 left-side limbs; $P < .001$). Angiography depicted 28 abnormalities in the CIA (27 stenoses, one dissection), 185 in the EIA (17 thromboses, 167 stenoses, one dissection), one in the common femoral artery (dissection), and 14 in the deep femoral artery (one thrombosis, 13 stenoses). CIA and EIA stenoses predominantly involved the distal and proximal third of the artery respectively. They were mild (CIA and EIA mean severity, 19% ± 7 and 26% ± 11, respectively) and long (45% ± 26 and 51% ± 26 of the artery, respectively). EIA stenoses were significantly longer in women ($P < .003$). Upon hip flexion, 23 CIA and 116 EIA stenoses showed kinking (mean amplitude, 76° ± 23 and 76° ± 30, respectively). All deep femoral artery stenoses were diaphragm-like and involved the lateral circumflex femoral artery. CIA, EIA, and femoral lesions were not randomly associated ($P < .001$).

Conclusion: Arterial endofibrosis mainly affects the central part of the iliac artery and the lateral circumflex femoral artery. The CIA, EIA, and femoral lesion classification may help to distinguish patterns of associated lesions.

©RSNA, 2014

[1] From the Department of Urinary and Vascular Radiology (O.R., J.P.G.) and Department of Vascular Surgery (P.F., J.M.C.), Hospices Civils de Lyon, Hôpital Edouard Herriot, Pavillon P Radio, 5 place d'Arsonval, Lyon 69003, France; Université de Lyon, Université Lyon 1, Faculté de Médecine Lyon Est, Lyon, France (O.R.); and Inserm, U1032, LabTau, Lyon, France (O.R.). Received June 1, 2013; revision requested July 22; revision received March 6, 2014; accepted March 29; final version accepted April 10. **Address correspondence to** O.R. (e-mail: *olivier.rouviere@netcourrier.com*).

©RSNA, 2014

Arterial endofibrosis affects highly-trained endurance athletes, mostly cyclists or long-distance runners (1–9). It usually occurs in the first centimeters of the external iliac artery (EIA); however, the common iliac artery (CIA) and/or the deep femoral artery can also be affected (3,10). It is characterized by arterial stenoses from focal intimal thickening made of loose connective tissue (11,12), and it causes claudication during maximal effort and reduced athletic performance (3,4).

Although pathophysiologic origins of arterial endofibrosis are unclear, it may be caused by vascular shear stress from multiple factors, such as increased cardiac output, supraphysiologic blood flow conditions, repeated arterial kinking during pedaling, or external compression by muscular hypertrophy (3,4,13–16). It is unclear whether the same pathophysiologic origins explain the lesions located on mobile arterial segments (eg, EIA) and on fixed arterial segments (eg, deep femoral artery). It is also unknown if there are patterns of association of lesions of the CIA, EIA, and deep femoral artery.

Because of its excellent spatial resolution, intra-arterial digital subtraction angiography (DSA) remains the best test to show endofibrosis lesions (3,4,13,17,18). However, qualitative and quantitative data on the angiographic appearance of arterial endofibrosis are not extensive because publications on the topic are limited to case reports or small series (1,2,10,13,14,19).

We retrospectively studied DSA images in patients treated for arterial endofibrosis proven by histologic analysis at our institution during a 12-year period to describe the spectrum of angiographic features of arterial endofibrosis and to assess the patterns of associated lesions.

Advances in Knowledge

- Arterial endofibrosis affected the common iliac artery (CIA; 14.4% of symptomatic limbs), the external iliac artery (EIA; 94.9% of symptomatic limbs), the common femoral artery (0.5% of symptomatic limbs), and the deep femoral artery and its branches (7.2% of symptomatic limbs), with a significant left-sided predominance ($P < .001$).
- Endofibrosis induced arterial stenoses (long, smooth, and mild in the iliac arteries; diaphragm-like in the branches of the deep femoral artery), dissections, or thromboses.
- Most endofibrotic stenoses of the CIA affected its distal third (88.9%), most stenoses of the EIA affected its proximal third (94.6%), and all stenoses of the deep femoral artery were located at the origin of the lateral circumflex femoral artery or of its descending branch.

Implications for Patient Care

- A better knowledge of the spectrum of endofibrosis angiographic features can allow a better recognition of the disease and a better preoperative assessment.
- The CIA, EIA, and femoral lesion classification can help to standardize the report of digital subtraction angiographic findings and assist to understand the pathophysiologic origins of the disease by identification of patterns of lesion association.

Materials and Methods

Patient Selection

We retrospectively searched our hospital information system database for patients who met the following inclusion criteria: patients underwent surgery between January 1998 and December 2009 because they were suspected of having arterial endofibrosis, and histopathologic findings were consistent with arterial endofibrosis (ie, subintimal paucicellular fibrosis with minimal or no atherosclerotic changes) (3,11,12). Our study is compliant with the principles of the declaration of Helsinki and with our national laws. Formal approval by an institutional review board is not required in our country for noninterventional retrospective studies.

DSA Protocol

The DSA protocol was standardized during the study period. We performed a femoral Seldinger approach contralateral to the symptoms while the patient underwent local anesthesia. First, angiograms of both iliac arteries were obtained in anteroposterior and right and left anterior oblique projections. The CIA of the symptomatic limb was then catheterized, and a selective arteriogram was obtained by using a contralateral anterior oblique projection with a straight hip and then with maximal hip flexion with the knee of the patient toward his chest, which was followed by a selective angiogram of the deep femoral artery of the symptomatic side obtained with a straight hip. Finally, a selective angiogram of the deep femoral artery of the asymptomatic side was obtained through the arterial sheath with a straight hip. No pressure measurements were obtained during DSA.

Surgical Protocol

All surgeries were performed by the same surgeon (J.M.C., with more than 30 years of experience). The first step of surgery was to perform angioscopy (ANG-080-D10K; Stryker, Kalamazoo, Mich) by using a common femoral

Published online before print
10.1148/radiol.14130882 **Content code:** VA

Radiology 2014; 273:294–303

Abbreviations:
CEF = CIA, EIA, and femoral artery
CIA = common iliac artery
DSA = digital subtraction angiography
EIA = external iliac artery

Author contributions:
Guarantors of integrity of entire study, O.R., P.F., J.P.G.; study concepts/study design or data acquisition or data analysis/interpretation, all authors; manuscript drafting or manuscript revision for important intellectual content, all authors; approval of final version of submitted manuscript, all authors; literature research, O.R., P.F., J.P.G.; clinical studies, all authors; experimental studies, J.P.G.; statistical analysis, O.R., J.P.G.; and manuscript editing, all authors

Conflicts of interest are listed at the end of this article.

approach in patients who were suspected of having iliac endofibrosis. Angioscopy was not performed in cases of femoral abnormality or iliac thrombosis. Arterial endofibrosis was usually treated by endofibrosectomy with a saphenous or arterial enlargement patch with or without shortening the artery, depending on its length (Fig 1). Resection reimplantation was usually performed in branches of the deep femoral artery. When these techniques were not possible (ie, because of long stenoses), a saphenous bypass was performed.

Data Recording and Imaging Analysis

Medical records were reviewed for age, sex, clinical features, DSA findings, and surgical report. Angiograms were retrospectively interpreted in consensus over the course of 1 year by two radiologists (O.R. and J.P.G., with 15 and 1 years of experience, respectively). The percentage of reduction in diameter and relative length (ie, length of stenosis divided by total length of artery ratio) of stenoses and the degree of arterial kinks were measured on plain films (Fig 2). Other abnormalities (eg, dissection or thrombosis) were also noted. Abnormalities depicted in the CIA, EIA, and femoral arteries were then respectively classified into five CIA, EIA, and femoral types, known as the CEF classification, which depended on their nature, location, and extent (Table 1).

Statistical Analysis

Statistical analysis was performed by using statistical software (R Statistical Package, version 3.0.2; R Foundation for Statistical Computing, Vienna, Austria). Qualitative characteristics were described by using numbers and percentages in each category. Quantitative characteristics were described by using the mean and the standard deviation. A Mann-Whitney test was used to compare quantitative characteristics. Fisher exact or χ^2 tests were used to compare the distribution of qualitative characteristics or to compare the observed distribution of CEF-classified lesion types to a theoretical distribution in which the associations of any CEF-classified lesions were equally likely.

Figure 1

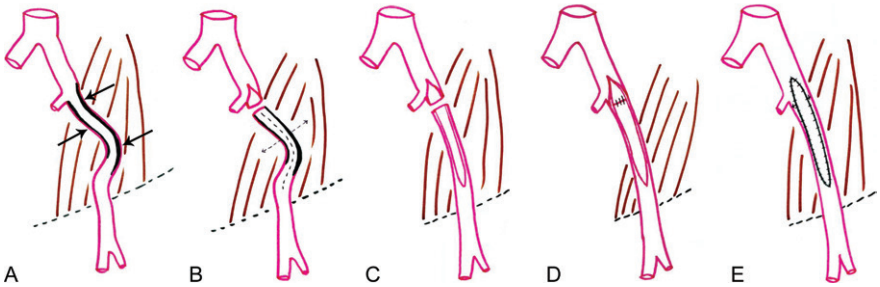

Figure 1: Schematic diagrams show the principle of endofibrosectomy. The thickening of the intima of the EIA (arrows, *A*) indicates the endofibrosis lesion. The surgeon performs first a longitudinal incision along the EIA (dotted line with arrows, *B*) and removes the endofibrosis lesion (endofibrosectomy). If necessary, a section of the EIA is obtained and an arterial segment is resected to treat the arterial excess of length (*C*). The origin of the EIA is then again anastomosed to the iliac bifurcation (*D*), and the diameter of the artery is restored by using a saphenous vein patch or an arterial patch taken from the resected portion of the artery (*E*).

Results

Study Population

A total of 214 patients met the inclusion criteria. Thirty-four patients were excluded because of history of previous surgery for arterial endofibrosis on the same limb (22 patients), incomplete medical file (three patients), or inappropriate DSA protocol (nine patients).

The study population was composed of 180 patients: 161 men (89.5%) and 19 women (10.5%). There were 157 racing cyclists (eight women), six long-distance runners (five women), and 17 triathletes (six women). Thirty-eight patients (four women) were professionals, 112 patients (nine women) were competitive amateurs, and 21 patients (four women) were recreational amateurs. The sporting level of nine patients (two women) was unknown. The proportion of patients with running activity (long-distance runners and triathletes) was significantly higher in women (11 of 19 [57.9%]) than in men (12 of 161 [7.5%]; $P < .001$). The distance cycled at onset of symptoms was significantly higher in men ($P < .006$; Table 2).

Fifteen patients (five women) had bilateral symptoms. There were 195 symptomatic limbs (59 right limbs and 136 left limbs; $P < .001$). The cause for referral in 190 limbs was pain of the thigh with sensation of swollen thigh, which appeared on high-intensity effort and disappeared after rest. Three patients had intermittent claudication of the thigh with minimal effort (ie, climbing stairs or walking rapidly) and two patients had critical ischemia of the limb.

DSA Findings

One DSA examination was considered normal. Focal abnormalities suggestive of endofibrosis ($n = 205$) were visible in the other 194 symptomatic limbs (Table 3).

EIA was abnormal in 185 of 195 symptomatic limbs (94.8%), which included 17 thromboses, one dissection of the proximal third of the artery, and 167 smooth, long, and slightly eccentric stenoses (Figs 2–4; Table 4).

CIA was abnormal in 28 of 195 symptomatic limbs (14.4%), which included one dissection of the distal third of the artery and 27 smooth stenoses (Table 4; Fig 5). In 23 limbs, CIA and EIA abnormalities (one dissection, 22 stenoses) were adjacent without discontinuity and were considered to be single lesions.

All CIA stenoses were less than 50%. Only one EIA stenosis was greater than 50%. The percentage of reduction in diameter of EIA stenoses was not significantly different in men and women ($P = .92$), but their length was significantly higher in women

Figure 2

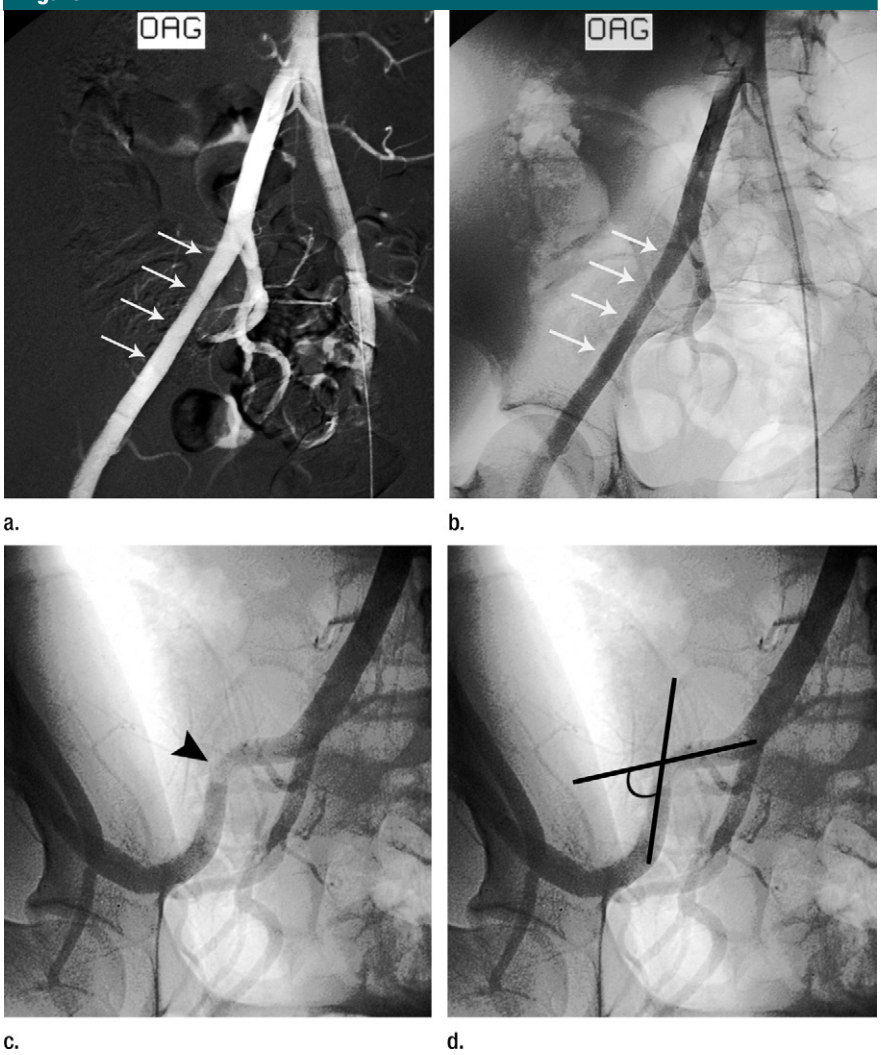

Figure 2: Selective angiographic images of the right iliac axis in left anterior oblique projection (*OAG*) in a 25-year-old professional racing cyclist with claudication of the right thigh at maximal effort. **(a)** Subtracted and **(b)** nonsubtracted native images show smooth stenosis of the proximal half of the right EIA reducing the arterial diameter by only 20% (arrows). **c, d** Upon hip flexion, nonsubtracted native images show a kink within the stenotic segment (arrowhead). In **d,** the methodologic measurement of the kink angular amplitude, which was 70° in this patient, is illustrated. No other abnormality was seen on the rest of the angiograms. The CEF classification of the right limb was C0E1F0. Intraoperative angioscopy was confirmatory. The patient underwent endofibrosectomy with shortening of the right EIA. Histologic analysis confirmed the endofibrosis. The final CEF classification of the left limb was pathologic C0E1F0.

($P < .003$; Table 4). CIA stenoses also tended to be longer in women, but the small number of patients precluded any statistical comparison (Table 4).

A permanent kink was visible within or at the extremities of 45 stenotic areas (Figs 4, 5). Upon hip flexion, most EIA and CIA stenoses showed a kink, either within the stenotic area or at its extremities (Table 4).

Six left limbs with typical EIA endofibrosis showed a permanent kink of the CIA (mean amplitude, 53° ± 23 [standard deviation]) with no associated stenosis suggestive of arterial endofibrosis. With hip flexion, a 108° ± 36 kink appeared on the ipsilateral stenotic EIA in four cases, but the CIA kinks did not change.

The common or deep femoral arteries were abnormal in 13 of 195 symptomatic limbs (6.7%; 11 men, two women), with one thrombosis of the deep femoral artery, one dissection of the common femoral artery, and 13 diaphragm-like stenoses located at the origin of the lateral circumflex femoral artery (eight stenoses) or at the origin of its descending branch (five stenoses). The percentage of reduction in diameter of these stenoses was impossible to calculate because of their diaphragm-like shape (Fig 6). Lesions that were CEF classified were not randomly associated but grouped into patterns ($P < .001$; Table 5).

Surgical Procedures

In all patients, CIA and EIA lesions were visible by using angioscopy that showed hemicircumferential plaques protruding within the arterial lumen (Fig 7).

Bilateral cases were treated by two interventions that were separated by a median delay of 8 months (range, 4 days to 44 months). Ten patients had two (nine patients) or three (one patient) noncontiguous arterial endofibrosis lesions in the same limb that were treated in either one intervention (nine patients) or two interventions (one intervention). Thus, the patients underwent 196 operations that found 206 noncontiguous lesions. Operations consisted of 122 endofibrosectomies with or without arterial shortening, three resection reimplantations, and 71 saphenous bypasses. The rate of bypass was significantly higher in women than in men (15 of 24 limbs [62.5%] vs 56 of 171 limbs [32.5%], respectively; $P < .01$). The rate of bypass was also significantly higher in limbs in which lesions were classified as E4–E5 vs limbs in which lesions were classified as E0–E3 (54 of 63 limbs [85.7%] vs 17 of 132 limbs [12.9%], respectively; $P < .001$).

Comparison between DSA and Surgical Findings

Surgery confirmed DSA findings in 184 of 195 limbs (94.4%). The six

Table 1

CEF Classification

Artery Class	Short Description	Full Description
CIA		
C1	Proximal	Stenoses (or dissections) that affect the proximal third of the artery, with possible extension in the middle third, but not in the distal third
C2	Middle	Stenoses (or dissections) located strictly within the middle third of the artery
C3	Distal	Stenoses (or dissections) that affect the distal third of the artery, with possible extension in the middle third, but not in the proximal third
C4	Total	Stenoses (or dissections) that affect the three thirds of the artery
C5	Thrombosis	Thrombosis of the artery
EIA		
E1	Proximal	Stenoses (or dissections) that affect the proximal third of the artery, with possible extension in the middle third, but not in the distal third
E2	Middle	Stenoses (or dissections) located strictly within the middle third of the artery
E3	Distal	Stenoses (or dissections) that affect the distal third of the artery, with possible extension in the middle third, but not in the proximal third
E4	Total	Stenoses (or dissections) that affect the three thirds of the artery
E5	Thrombosis	Thrombosis of the artery
Common and deep femoral arteries		
F1	Lateral circumflex artery	Stenoses (or dissections) of the origin of the lateral circumflex femoral artery
F2	Descending branch of lateral circumflex artery	Stenoses (or dissections) of the origin of the descending branch of the lateral circumflex femoral artery
F3	Other locations	Stenoses (or dissections) of other locations
F4	Multiple locations	Multiple separate lesions on common and/or deep femoral arteries
F5	Thrombosis	Thrombosis of common and/or deep femoral arteries

left-side CIAs with a permanent kink but no stenosis at DSA had no sign of endofibrosis at angioscopy.

The patient with normal DSA findings had, at surgery, a 2-cm long arterial endofibrosis lesion of the proximal third of the left EIA (erroneously classified by using the CEF classification system as C0E0F0 instead of C0E1F0).

In six limbs, the EIA lesion slightly extended into the distal third of the CIA, which had been overlooked at DSA (five limbs were erroneously classified as C0E1F0 instead of C3E1F0, and one limb was classified as C0E4F0 instead of C3E4F0). In one case, DSA showed a slight stenosis of the distal CIA and proximal EIA (C3E1F0) when surgery found only a lesion of the proximal EIA (C0E1F0).

In the three remaining limbs, DSA did not correctly assess the length of EIA lesions. In two cases, the lesion had been classified C0E1F0 when it in fact affected the whole EIA (C0E4F0).

Table 2

Patient Characteristics

Parameter	Men	Women	*P* Value
Age (y)	30.9 ± 9.9	35.9 ± 9.6	.02
Distance cycled at onset of symptoms (km)*	130 600 ± 81 800	7500 ± 61 700	.006
Distance ran at onset of symptoms (km)†	19 900 ± 14 800	26 700 ± 12 500	.27

Note.—Data are mean ± standard deviation.

* Cyclists and triathletes.

† Long-distance runners and triathletes.

Table 3

Location of Abnormalities Visible by Using DSA

Parameter	Right Side	Left Side
CIA and EIA	1	22
CIA	0	5
EIA	57	105
Common femoral artery	0	1
Deep femoral artery and branches	4	10

Note.—Data are number of abnormalities. There were 205 abnormalities.

Table 4

Characteristics of Iliac Stenoses Caused by Endofibrosis

Parameter	No. of Limbs	Percentage of Reduction in Diameter (%)*	Relative Length of Iliac Stenosis(%)*†	Involvement of Proximal Third of Artery	Involvement of Middle Third of Artery	Involvement of Distal Third of Artery	Permanent Kinks		Kinks at Hip Flexion	
							No. of Limbs	Amplitude (degrees)*	No. of Limbs	Amplitude (degrees)*
EIA										
Men	144	26 ± 10.8	48 ± 24	136	105	38	23	49 ± 23	104	76 ± 30
Women	23	26 ± 10	68 ±28	22	21	12	4	42 ± 6	12	78 ± 31
Total	167	26 ± 11	51 ± 26	158	126	50	27	48 ± 21	116	76 ± 29
CIA										
Men	25	19 ± 7	43 ± 27	4	15	23	16	44 ± 23	22	77 ± 23
Women	2	22 ± 3	60 ± 8	1	2	1	0	...	1	60
Total	27	19 ± 7	45 ± 26	5	17	24	16	44 ± 23	23	76 ± 23

Note.—Data are number of limbs except where otherwise indicated. Endofibrosis was proven by histologic analysis.

* Data are ± standard deviation.

† Length of stenosis/total length of artery ratio.

Figure 3

Figure 3: Angiographic image (right anterior oblique projection) in a 32-year-old amateur racing cyclist with claudication of the left thigh at maximal effort. The left EIA shows a marked reduction in diameter extended to more than two thirds of its length (arrows; CEF classification of C0E4F0). An endofibrosectomy with saphenous enlargement patch was performed. Histology confirmed arterial endofibrosis. The final CEF classification of the right limb was pathologic C0E4F0.

In one case, DSA classified a lesion as C0E4F0 when only the middle third of the EIA was involved at surgery (therefore, it should have been classified as C0E2F0).

Postsurgical Follow-up

Sixty-nine patients were followed longer than 1 year at our institution. For these patients, the median follow-up period was 49.6 months (range, 12–161 months). Sixty-two patients (89.9%) had no symptoms at maximal effort at the end of follow-up. One patient (classified as C0E4F0) had a thrombosis of a saphenous bypass 44 months after surgery and was treated by thrombectomy and refection of the femoral anastomosis. Six patients (four patients who were evaluated as C0E1F0 and two patients who were evaluated as C0E4F0) were still symptomatic at maximal effort after surgery, and two patients underwent transluminal angioplasty for a stenosis at the site of operation 12 and 24 months after surgery, with a good result.

Figure 4

Figure 4: Angiographic image in left anterior oblique projection in a 42-year-old amateur racing cyclist with claudication of the right thigh at maximal effort. Image obtained with a straight hip showns a 15% smooth stenosis involving at least 80% of the arterial length (arrows). Note a permanent 65° kinking of the right CIA (arrowhead) with no associated stenosis. There was no abnormality of the right femoral artery and its branches (not shown). The angiographic classification of the right limb was classified as C0E4F0. Angioscopy and intraoperative findings confirmed that arterial endofibrosis involved the entire length of the right external iliac artery. The patient underwent a saphenous bypass. There was no endofibrosis of the right CIA at angioscopy. Thus, the final CEF classification of the right limb was pathologic C0E4F0.

Figure 5

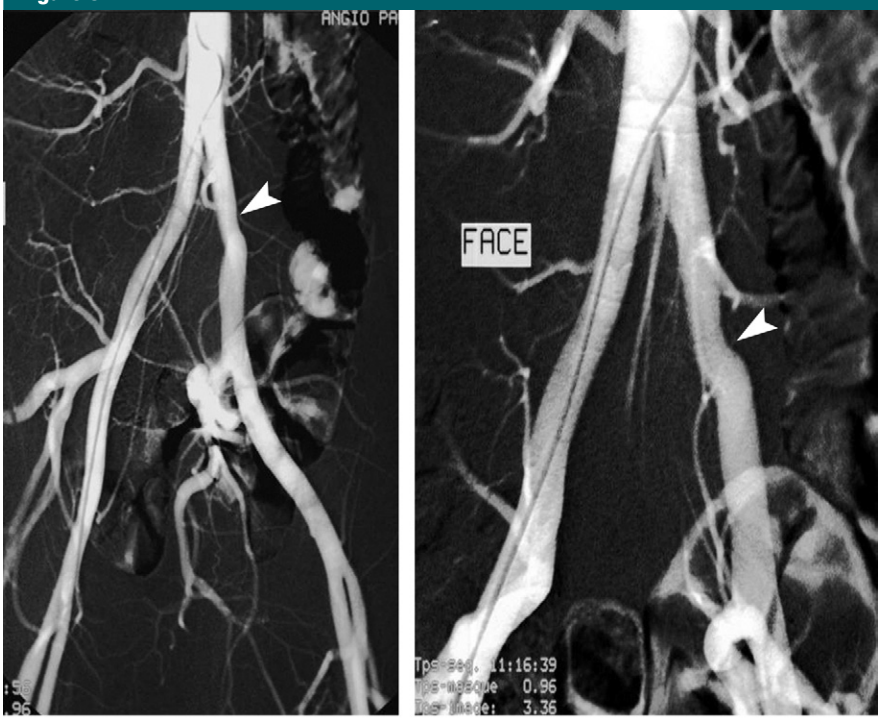

a. b.

Figure 5: Angiographic images in **(a)** right anterior oblique and **(b)** anteroposterior projection (*FACE*) in a 26-year-old professional racing cyclist with claudication of the left thigh at maximal effort. Images obtained with a straight hip show a 15% stenosis of the middle third of the left CIA (arrowhead in **a**) with an associated 30° permanent kinking (arrowhead in **b**). There was no clear abnormality of the left EIA or of the deep femoral artery. The angiographic classification of the left limb was C2E0F0. Angioscopy confirmed arterial endofibrosis of the middle third of the left CIA. The patient underwent an endofibrosectomy with an arterial shortening and a patch venous angioplasty. Histologic analysis confirmed the endofibrosis. The final classification of the left limb was pathologic C2E0F0.

Discussion

In our series, arterial segments affected by endofibrosis appeared mainly as a stenotic area by using DSA. However, there was a striking difference between iliac and femoral stenoses. CIA and EIA stenoses were smooth, moderate, and affected various lengths of the artery. EIA was the most frequently affected artery (185 of 195 limbs [94.8%]). When present (28 of 195 limbs [14.4%]), CIA lesions were most often an extension of EIA lesions. As a result, there was a mirror-like distribution of the involved portions of EIA and CIA, with a predominance on the central part of the iliac artery (ie, the CIA distal third and the EIA proximal two thirds). However, stenoses of the deep femoral artery were short, diaphragm-like lesions located at the origin of the lateral circumflex femoral artery or of its descending branch.

These different features may be related to different pathophysiologic processes. For most authors, arterial endofibrosis is believed to be caused by repeated deformation of the iliac artery during flexion and extension of the hip that induces arterial lengthening and kinking, which subsequently damages the arterial wall (3,5,13). This theory is supported by the fact that most CIA and EIA stenoses showed a kinking upon hip flexion and predominance on the central portion of the iliac artery. Interestingly, at pathologic analysis, the intimal thickening seems maximal in the greatest curve of the arterial bending (12). On the other hand, the lateral circumflex femoral artery and its descending branch are not mobile during pedaling. Other mechanisms, such as supraphysiologic blood flow conditions (that may also play a role in the development of iliac lesions) may be the predominant causal factor in these locations. This theory is supported because the lateral circumflex femoral artery vascularizes the quadriceps and stenoses appear at arterial bifurcations, where turbulences may be maximal under supraphysiologic blood flow conditions.

Nevertheless, other factors remain to be fully understood, such as the presence of permanent arterial kinks

Figure 6

a. b.

Figure 6: Angiographic images in left anterior oblique projection *(OAG)* in a 46-year-old amateur racing cyclist with claudication of the right thigh at maximal effort show **(a)** an EIA with reduced diameter on its whole length (arrows) and **(b)** a diaphragm-like stenosis of the origin of the lateral circumflex femoral artery (arrowhead). The CEF classification of the right limb was C0E4F1. The patient first underwent an endofibrosectomy of the lateral circumflex femoral artery. Histologic analysis confirmed arterial endofibrosis. The patient then underwent angioscopy of the right iliac axis that showed arterial endofibrosis of the EIA throughout its entire length, and a saphenous bypass was performed. Histologic analysis confirmed arterial endofibrosis. The final classification of the right limb was pathologic C0E4F1.

without associated endofibrosis or the marked left-sided predominance of iliac and femoral lesions.

Our series also showed a difference in the endofibrosis-related lesions among men and women; women had significantly longer EIA stenoses. In our study, the women group also consisted of a significantly higher proportion of runners. Therefore, whether the longer EIA stenoses observed in women reflect a higher susceptibility of women to endofibrosis or different physiopathologic processes between runners and cyclists remains to be clarified.

Endofibrosis can be complicated by focal dissections or thrombosis, which confirms previous case reports (20,21). The frequency of thrombosis may seem surprising given the low percentage of reduction in diameter of endofibrosis-related stenoses. However, all of our patients with thromboses reported acute worsening of their symptoms after a competition. It is possible that dehydration caused by intense effort may have played a role in the arterial occlusion.

We provided a classification of endofibrosis-related angiographic features that takes into account the possibility of multiple lesions on the same limb and allows the free association of the CIA, EIA, and femoral artery abnormalities. As a result, it may become a useful tool to identify patterns of lesions. We observed four main patterns: C0E1F0 (n = 88), C0E4F0 (n = 39), C0E5F0 (n = 17), and C3E1F0 (n = 16). Other interesting patterns could also be noted: all E2 types were grouped in a C0E2F0 pattern and all C4 types in a C4E1F0 pattern. Most femoral abnormalities were either isolated (C0E0F1–F5 patterns; n = 7) or associated to an endofibrosis of the whole EIA (C0E4F1–F4 pattern; n = 3). In the future, this pattern recognition may be useful to better understand arterial endofibrosis physiopathologic origins. Furthermore, the CEF lesion classification allows standardized reporting of the different arterial segments and of the length of stenoses. In our experience, these features are determinant to plan courses of treatment, and particularly to assess the risk of having to perform a saphenous bypass. As a result, the need for a saphenous bypass varied widely among the CIA, EIA, and femoral lesion patterns.

Unlike most classifications of atherosclerotic lesions, our classification did not assess the severity of stenosis. This can be explained by three reasons. First, the severity of diaphragm-like femoral stenoses was difficult to evaluate. Second, although all patients were symptomatic at maximal effort, all iliac stenoses but one were less than 50%, and therefore would have been judged as nonsignificant by standards used for atherosclerotic stenoses. Third, severity of stenosis did not change the type of surgical treatment in our practice.

Our classification did not evaluate the excessive length that is often associated to endofibrosis in iliac arteries (2,3,5). This is an important feature because an excessive length will cause arterial kinking that may further worsen the flow limitation during pedaling and will eventually worsen the endofibrosis itself (2,3,5). We therefore suggest that (other than the CIA, EIA, and femoral lesion pattern) the radiologist always report the angle of kinking of the EIA and/or the CIA upon hip flexion. Alternatively, the excessive vessel length could be estimated by the ratio of vessel length to straight line distance, as suggested by some authors (22).

Magnetic resonance (MR) angiography has been proposed as a noninvasive alternative to DSA (15,23). However, it is prone to beat-to-beat motion artifacts, and diaphragm-like stenoses of the deep femoral branches may be difficult to assess because of its low spatial resolution. Computed tomographic angiography may be another alternative to DSA. It has a higher spatial resolution than MR angiography, and beat-to-beat

Table 5

CEF Combinations Observed in Symptomatic Limbs

CEF Type	No. of Symptomatic Limbs in the Population	No. of Symptomatic Limbs with Venous Bypass
C0E0F0	1	0
C0E0F1	2	0
C0E0F2	3	0
C0E0F4	1	0
C0E0F5	1	1
C0E1F0	87 (9)	10 (2)
C0E1F1	1	0
C0E1F2	1	0
C0E2F0	6 (1)	2 (1)
C0E3F0	4	2
C0E4F0	40 (9)	32 (8)
C0E4F1	2 (1)	2 (1)
C0E4F4	1 (1)	1 (1)
C0E5F0	17 (1)	17 (1)
C1E4F0	1 (1)	0 (0)
C2E0F0	2	0
C2E1F0	1	0
C3E1F0	17 (1)	2 (1)
C3E1F2	1	0
C3E4F0	2	2
C4E1F0	4	0

Note.—Data in parentheses are the number of symptomatic limbs in the female group. There were 195 symptomatic limbs.

motion can be suppressed by cardiac gating. However, to our knowledge, its accuracy in patients with arterial endofibrosis has not been evaluated.

DSA may overlook or underestimate some lesions, especially in CIA. At our institution, an angioscopy is systematically performed before surgery of iliac lesions to confirm or adapt the treatment decided based on DSA findings. Intravascular ultrasonographic (US) imaging could be an alternative, but endofibrosis lesions seem poorly echogenic and difficult to characterize (24). It is of note, however, that neither angioscopy nor intravascular US can easily explore the branches of the deep femoral artery that require a careful assessment at DSA. Nevertheless, because DSA can be discordant with surgical and pathologic findings, we suggest the use of a pathologic CEF classification that summarizes the pathologic findings, just as the pathologic pTNM classification is used alongside the TNM classification in oncology.

Figure 7

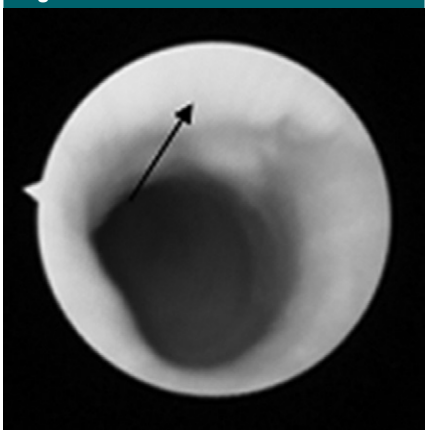

Figure 7: Angioscopic view shows an endofibrosis lesion, which appears as a slightly irregular plaque that protrudes within the arterial lumen (arrow).

Our study had some limitations. First, DSA features were assessed in consensus by two radiologists, and the interreader variability was not assessed. Second, asymptomatic limbs were not evaluated, and subtle endofibrosis-related lesions could have been missed on these limbs. Third, we evaluated only patients who underwent surgery inducing a selection bias. As a result, DSA may miss more arterial endofibrosis lesions than it appears in our series. Fourth, many treated patients lived far away from our institution and were not followed up on site. As a result, we could provide only limited follow-up data. Therefore, the prognostic value of the CEF classification remains to be determined. However, in our study, as in others (6,8), surgery yielded excellent medium-term results, and only 10.1% (seven of 69) of the patients who were followed up remained symptomatic after treatment. As a result, the assessment of the prognostic value of any classification of arterial endofibrosis will need a large series and long-term follow-up.

In conclusion, arterial endofibrosis affects CIAs and EIAs, and the common and deep femoral arteries, and it can induce arterial stenoses, thromboses, and dissections. Knowledge of the spectrum of angiographic features described in this article can allow a better preoperative assessment of endofibrosis. The CEF classification may also help to standardize reporting of DSA findings and to understand its pathophysiologic origins. However, its clinical utility remains to be confirmed by further studies.

Acknowledgment: The authors are deeply thankful to Muriel Rabilloud, MD, PhD, for her help with the statistical analysis of the results.

Disclosures of Conflicts of Interest: O.R. Activities related to the present article: disclosed no relevant relationships. Activities not related to the present article: author is a member of the Novartis France angiomyolipoma board; author provides lectures for Takeda. Other relationships: disclosed no relevant relationships. **P.F.** disclosed no relevant relationships. **J.P.G.** disclosed no relevant relationships. **J.M.C.** disclosed no relevant relationships.

References

1. Walder J, Mosimann F, Van Melle G, Mosimann R. Iliac endofibrosis in 2 cycling racers [in French]. Helv Chir Acta 1985;51(6):793–795.
2. Chevalier JM, Enon B, Walder J, et al. Endofibrosis of the external iliac artery in bicycle racers: an unrecognized pathological state. Ann Vasc Surg 1986;1(3):297–303.
3. Feugier P, Chevalier JM. Endofibrosis of the iliac arteries: an underestimated problem. Acta Chir Belg 2004;104(6):635–640.
4. Ehsan O, Darwish A, Edmundson C, Mills V, Al-Khaffaf H. Non-traumatic lower limb vascular complications in endurance athletes. Review of literature. Eur J Vasc Endovasc Surg 2004;28(1):1–8.
5. Peach G, Schep G, Palfreeman R, Beard JD, Thompson MM, Hinchliffe RJ. Endofibrosis and kinking of the iliac arteries in athletes: a systematic review. Eur J Vasc Endovasc Surg 2012;43(2):208–217.
6. Bender MH, Schep G, Bouts SW, Backx FJ, Moll FL. Endurance athletes with intermittent claudication caused by iliac artery stenosis treated by endarterectomy with vein patch—short- and mid-term results. Eur J Vasc Endovasc Surg 2012;43(4):472–477.
7. Speedy DB, Abraham P, Graham KJ, Charlesworth P. External iliac artery endofibrosis in a triathlete. Clin J Sport Med 2000;10(2):148–149.
8. Politano AD, Tracci MC, Gupta N, Hagspiel KD, Angle JF, Cherry KJ. Results of external iliac artery reconstruction in avid

cyclists. J Vasc Surg 2012;55(5):1338–1344; discussion 1344–1345.

9. Abraham P, Bouyé P, Quéré I, Chevalier JM, Saumet JL. Past, present and future of arterial endofibrosis in athletes: a point of view. Sports Med 2004;34(7):419–425.
10. Alimi YS, Accrocca F, Barthèlemy P, Hartung O, Dubuc M, Boufi M. Comparison between duplex scanning and angiographic findings in the evaluation of functional iliac obstruction in top endurance athletes. Eur J Vasc Endovasc Surg 2004;28(5):513–519.
11. Vink A, Bender MH, Schep G, et al. Histopathological comparison between endofibrosis of the high-performance cyclist and atherosclerosis in the external iliac artery. J Vasc Surg 2008;48(6):1458–1463.
12. Rousselet MC, Saint-Andre JP, L'Hoste P, Enon B, Megret A, Chevalier JM. Stenotic intimal thickening of the external iliac artery in competition cyclists. Hum Pathol 1990;21(5):524–529.
13. Ford SJ, Rehman A, Bradbury AW. External iliac endofibrosis in endurance athletes: a novel case in an endurance runner and a review of the literature. Eur J Vasc Endovasc Surg 2003;26(6):629–634.
14. Scavèe V, Stainier L, Deltombe T, et al. External iliac artery endofibrosis: a new possible predisposing factor. J Vasc Surg 2003;38(1):180–182.
15. Schep G, Bender MH, van de Tempel G, Wijn PF, de Vries WR, Eikelboom BC. Detection and treatment of claudication due to functional iliac obstruction in top endurance athletes: a prospective study. Lancet 2002;359(9305):466–473.
16. Maree AO, Ashequl Islam M, Snuderl M, et al. External iliac artery endofibrosis in an amateur runner: hemodynamic, angiographic, histopathological evaluation and percutaneous revascularization. Vasc Med 2007;12(3):203–206.
17. Korngold EC, Jaff MR. Unusual causes of intermittent claudication: popliteal artery entrapment syndrome, cystic adventitial disease, fibromuscular dysplasia, and endofibrosis. Curr Treat Options Cardiovasc Med 2009;11(2):156–166.
18. Flors L, Leiva-Salinas C, Bozlar U, et al. Imaging evaluation of flow limitations in the iliac arteries in endurance athletes: diagnosis and treatment follow-up. AJR Am J Roentgenol 2011;197(5):W948–W955.
19. Kral CA, Han DC, Edwards WD, Spittell PC, Tazelaar HD, Cherry KJ Jr. Obstructive external iliac arteriopathy in avid bicyclists: new and variable histopathologic features in four women. J Vasc Surg 2002;36(3):565–570.
20. Del Gallo G, Plissonnier D, Planet M, Peillon C, Testart J, Watelet J. Dissecting aneurysm of the external iliac artery. An unusual course of endofibrosis in an athlete [in French]. J Mal Vasc 1996;21(2):95–97.
21. Willson TD, Revesz E, Podbielski FJ, Blecha MJ. External iliac artery dissection secondary to endofibrosis in a cyclist. J Vasc Surg 2010;52(1):219–221.
22. Schep G, Kaandorp DW, Bender MH, et al. Excessive length of iliac arteries in athletes with flow limitations measured by magnetic resonance angiography. Med Sci Sports Exerc 2002;34(3):385–393.
23. Giannoukas AD, Berczi V, Anoop U, Cleveland TJ, Beard JD, Gaines PA. Endofibrosis of iliac arteries in high-performance athletes: diagnostic approach and minimally invasive endovascular treatment. Cardiovasc Intervent Radiol 2006;29(5):866–869.
24. Lomis NN, Miller FJ, Whiting JH, Giuliano AW, Yoon HC. Exercise-induced external iliac artery intimal fibrosis: confirmation with intravascular ultrasound. J Vasc Interv Radiol 2000;11(1):51–53.