Note: This copy is for your personal non-commercial use only. To order presentation-ready copies for distribution to your colleagues or clients, contact us at www.rsna.org/rsnarights.

Moderate Carotid Artery Stenosis: MR Imaging–depicted Intraplaque Hemorrhage Predicts Risk of Cerebrovascular Ischemic Events in Asymptomatic Men[1]

Navneet Singh, BHSc Hon
Alan R. Moody, FRCP, FRCR
David J. Gladstone, MD, PhD, FRCPC
General Leung, MSc
Radhakrishnan Ravikumar, MBBS, PhD, DNB
James Zhan, MD, PhD
Robert Maggisano, MD, FRCSC

Purpose: To investigate the association between magnetic resonance (MR) imaging–depicted intraplaque hemorrhage (IPH) in the carotid artery wall and the risk of future ipsilateral cerebrovascular events in men with asymptomatic moderate carotid stenosis by using a rapid three-dimensional T1-weighted fat-suppressed spoiled gradient-echo sequence.

Materials and Methods: The institutional ethics review board approved this retrospective chart review and waived the requirement for written informed consent. All patients gave informed verbal consent at follow-up telephone interviews. Ninety-one men (mean age, 74.8 years; range, 47–88 years) who attended a vascular clinic between 2003 and 2006, who had asymptomatic carotid stenosis (50%–70% at Doppler ultrasonography), and who had undergone MR imaging for IPH detection were retrospectively identified. Seventy-five men with 98 eligible carotid arteries were included in the study. Patients were followed for a minimum of 1 year (mean follow-up, 24.92 months; range, 12–43 months). Kaplan-Meier survival and univariate Cox regression analyses were conducted to compare future ipsilateral cerebrovascular event rates between carotid arteries with and those without MR-depicted IPH.

Results: Of the 98 carotid arteries included, 36 (36.7%) had MR-depicted IPH. Six cerebrovascular events (two strokes and four transient ischemic attacks) occurred in the carotid arteries with IPH, as compared with no clinical events in the carotid arteries without IPH. Univariate Cox regression analysis confirmed that MR-depicted IPH was associated with an increased risk of cerebrovascular events (hazard ratio, 3.59; 95% confidence interval: 2.48, 4.71; $P <$ .001). MR-depicted IPH negatively predicted outcomes (negative predictive value = 100%).

Conclusion: In this cohort with asymptomatic moderate carotid stenosis, MR-depicted IPH was associated with future ipsilateral cerebrovascular events. Conversely, patients without MR-depicted IPH remained asymptomatic during follow-up. The absence of IPH at MR imaging, therefore, may be a reassuring marker of plaque stability and of a lower risk of thromboembolism.

© RSNA, 2009

[1] From the Department of Diagnostic Imaging (N.S., A.R.M., G.L., R.R., J.Z.), Division of Neurology and Regional Stroke Centre (D.J.G.), and Department of Vascular Surgery (R.M.), Sunnybrook Health Sciences Centre, University of Toronto, 2075 Bayview St, Toronto, ON, Canada M4N 3M5. Received May 5, 2008; revision requested June 27; revision received October 20; accepted December 2; final version accepted February 24, 2009. N.S. supported by 2007 RSNA R&E Foundation Research Medical Student Grant, University of Toronto Distinction in Research CREMS Program and CREMS Scholar Program, and Department of Medical Imaging (Sunnybrook Health Sciences Centre). D.J.G. supported by Heart and Stroke Foundation of Ontario, Heart and Stroke Foundation Centre for Stroke Recovery, and Department of Medicine (Sunnybrook Health Sciences Centre). **Address correspondence to** A.R.M. (e-mail: *alan.moody@sunnybrook.ca*).

© RSNA, 2009

Mortality from ischemic stroke is predicted to rise from 139 000 people in 2002 to 275 000 in 2032 in the United States alone (1), and carotid artery disease is an important cause of stroke. Symptomatic high-grade stenosis is the main indication for carotid endarterectomy (CEA) (2). Clinical treatment decisions regarding asymptomatic patients with moderate carotid stenosis are more difficult (2,3). Patients with symptomatic peripheral vascular disease are among those incidentally found to have asymptomatic moderate carotid artery stenosis because it is recommended for that population to undergo routine carotid stenosis screening (4).

Intraplaque hemorrhage (IPH), a major characteristic of American Heart Association type 6b/c complicated plaque, is an emerging marker of plaque instability (5–7). IPH contributes to two features that synergistically increase the odds of plaque rupture: necrotic core size and plaque volume (7). IPH is known to occur more frequently in men than in women, suggesting that the progression of atherosclerosis varies by sex (8,9). Carotid artery vessel wall IPH may be detected noninvasively by using magnetic resonance (MR) imaging with a simple rapid (<5 minutes) three-dimensional (3D) T1-weighted gradient-echo sequence, which exploits the presence of T1 shortening species within IPH (10).

Given the relationship between IPH and plaque instability, sex differences in plaque progression, and a validated imaging technique for detecting IPH, we hypothesized that MR-depicted IPH in the carotid artery would be associated with future cerebrovascular events (defined as stroke or transient ischemic attack) in men. Thus, our purpose was to investigate the association between MR-depicted IPH and the risk of future ipsilateral cerebrovascular events in men with asymptomatic moderate carotid stenosis in the carotid artery wall by using a rapid 3D T1-weighted fat-suppressed spoiled gradient-echo sequence.

Advance in Knowledge

- Carotid intraplaque hemorrhage (IPH) is associated with future cerebrovascular events in asymptomatic men with moderate carotid stenosis.

Materials and Methods

Participants

The Sunnybrook Health Sciences research ethics review board approved this retrospective chart review and waived the requirement for informed consent because the MR images and follow-up data were obtained as part of routine clinical care. All patients gave informed verbal consent during follow-up telephone interviews used to confirm outcomes. To be included, patients had to be men who were being imaged for peripheral vascular disease at the vascular clinic of our academic tertiary center between February 1, 2003, and September 15, 2006, and who were found to have moderate (50%–70%) asymptomatic carotid stenosis in either carotid artery. Patients were defined as asymptomatic if they had not had any cerebrovascular symptoms in the past 6 months. All patients being investigated for peripheral vascular disease at the vascular clinic undergo Doppler ultrasonographic (US) examination of the carotid arteries performed by an accredited vascular US laboratory. At our institution, patients with carotid stenosis of greater than 50% routinely undergo MR imaging and MR angiography to confirm the degree of stenosis (11,12). Exclusion criteria were CEA before or after MR imaging, stenosis that was not moderate at Doppler US (ie, <50% or >70%), and unreadable MR images (eg, motion artifact).

Prior to MR imaging, study subjects' baseline information was collected at the vascular clinic by an academic vascular surgeon (R.M.). Patients were followed-up in the vascular clinic regularly (approximately every 6 months) with the same vascular surgeon. All patients were followed-up by the first author (N.S.) for this study by chart review and telephone interview 1 year or more after MR imaging to verify occurrences of strokes and transient ischemic attacks. Absence of CEA and any changes to baseline medications were also confirmed.

MR Protocol

MR imaging for detection of carotid vessel wall IPH, previously referred to as MR direct thrombus imaging, has been validated (10). Patients were examined by using a 1.5-T MR imager (GE Twin Speed; GE Healthcare, Milwaukee, Wis) and an eight-channel neurovascular phased-array coil (USA Instruments, Aurora, Ohio). A 3D T1-weighted fat-suppressed (Special [spectral inversion at lipids]; GE Healthcare) spoiled gradient-echo sequence (repetition time, 6.7 msec; echo time, 1.7 msec; flip angle, 15°; section thickness, 2 mm; field of view, 300 mm^2; matrix size, 320 × 320; interpolated effec-

Implications for Patient Care

- Carotid MR-depicted IPH may be useful for stratifying the risk of cerebrovascular events in patients with peripheral vascular disease who are found to have carotid stenosis at routine screening.
- Absence of carotid MR-depicted IPH may indicate that intervention is not immediately required owing to the high negative predictive value of MR-depicted IPH, but close follow-up is warranted.

Published online before print
10.1148/radiol.2522080792

Radiology 2009; 252:502–508

Abbreviations:
CEA = carotid endarterectomy
CI = confidence interval
IPH = intraplaque hemorrhage
3D = three-dimensional

Author contributions:
Guarantors of integrity of entire study, N.S., A.R.M., R.R., J.Z.; study concepts/study design or data acquisition or data analysis/interpretation, all authors; manuscript drafting or manuscript revision for important intellectual content, all authors; approval of final version of submitted manuscript, all authors; literature research, N.S., A.R.M., D.J.G., R.R.; clinical studies, N.S., A.R.M., R.R., J.Z., R.M.; statistical analysis, N.S., A.R.M., D.J.G., J.Z.; and manuscript editing, N.S., A.R.M., D.J.G., G.L., R.R., R.M.

Authors stated no financial relationship to disclose.

tive pixel size, 0.94 × 0.94 × 1 mm; number of signals acquired, 3) was used. Imaging time was 4 minutes 13 seconds.

Evaluation of MR-depicted IPH

MR-depicted IPH was defined as plaque signal intensity that exceeded the intensity of the adjacent skeletal muscle by 50% (subjectively assessed) (Fig 1, with variations depicted in Figs 2 and 3). The radiologist (R.R., with 16 years experience), blinded to all patient information, made a binary decision. Increased signal intensity was only considered to be carotid IPH if it was in the internal carotid artery wall; hyperintensities elsewhere were not considered (eg, thyroid cysts). Any case that could not be clearly dichotomized was reviewed with a second radiologist (A.R.M., with 19 years experience), who was also blinded to all patient information, to reach a consensus decision. The use of MR imaging to depict carotid IPH is reliable (interobserver agreement, $\kappa = 0.75$; intraobserver agreement, $\kappa = 0.9$) (10).

Statistical Analysis

Statistical analysis was performed by using software (SPSS, version 13.0; SPSS, Chicago, Ill). A P value of less than .05 was considered to indicate a significant difference. Between the patients with and those without MR-depicted IPH, the χ^2 and Mann-Whitney tests were used to evaluate difference in categorical and continuous baseline data, respectively. The specificity and negative predictive value of MR-depicted IPH for outcomes were calculated. Kaplan-Meier survival analysis and univariate Cox regression analysis were conducted to depict differences in future ipsilateral cerebrovascular events between the two groups. Multivariate Cox regression analysis, adjusted for risk factors, was performed to evaluate whether carotid IPH was an independent risk factor for future ipsilateral cerebrovascular events.

Results

Ninety-one asymptomatic men with moderate carotid stenosis (mean age, 74.8 years ± 7.93 [standard deviation];

Figure 1

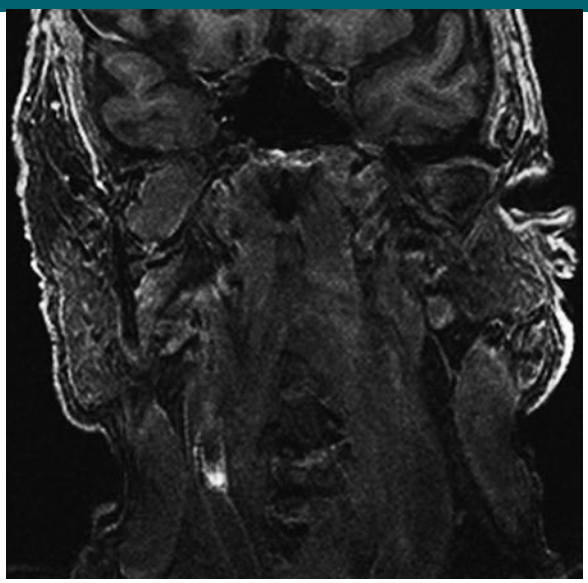

Figure 1: MR image shows idealized hyperintensity in right carotid artery vessel wall signifying presence of carotid MR-depicted IPH.

Figure 2

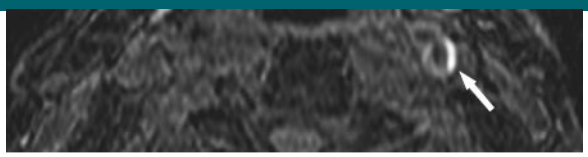

a.

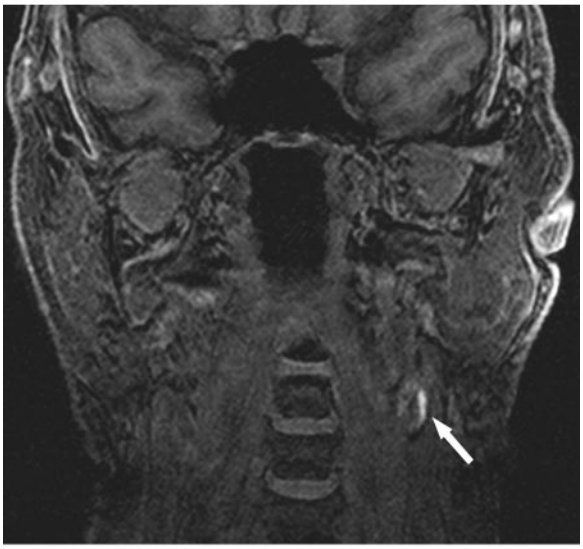

b.

Figure 2: **(a)** Axial and **(b)** coronal MR images of an 83-year-old man show a variation in hyperintensity of the left carotid artery vessel wall (arrows = MR-depicted IPH).

range, 47–88 years) qualified for study inclusion. Of the 182 vessels in these men, 14 (7.7%) arteries were excluded owing to CEA prior to MR imaging; 50 (27.5%), owing to mild or severe stenosis; 14 (7.7%), owing to CEA after MR imaging; and four (2.2%), owing to failed MR imaging. One patient with two eligible arteries refused to participate, resulting in a lost-to–follow-up rate of 2% (two of 100 eligible arteries). Of the remaining 98 carotid arteries in 75 men, 36 (36.7%) were found to contain MR-depicted IPH. No significant differences existed between arteries with and those without MR-depicted IPH for various risk factors (Table 1). With a per-patient design in which patients were grouped on the basis of whether they had any affected artery (ie, patients with one or two carotid arteries with IPH vs those with no arteries with IPH), smoking was the only significant difference ($P = .048$) between the groups (Table 2). No significant differences were found between men who experienced cerebrovascular events and those who did not.

Six cerebrovascular events (two strokes and four transient ischemic attacks in six different patients) occurred in the 36 carotid arteries with MR-depicted IPH, and no cerebrovascular events occurred in the 62 carotid arteries without MR-depicted IPH (specificity, 67.4%; negative predictive value, 100%). All events occurred in the anterior circulation. A Kaplan-Meier survival plot of the incidence of ipsilateral cerebrovascular events demonstrated that event-free survival was higher among patients without carotid MR-depicted IPH (Fig 4). The mean follow-up time was 24.92 months ± 10.45 (range, 12–43 months).

Univariate Cox analysis confirmed that ipsilateral carotid MR-depicted IPH was associated with an increased risk of cerebrovascular events (hazard ratio, 3.59; 95% confidence interval [CI]: 2.48, 4.71; $P < .001$). Meaningful multivariate Cox regression analysis, however, was not possible owing to the limited number of cerebrovascular events.

Figure 3

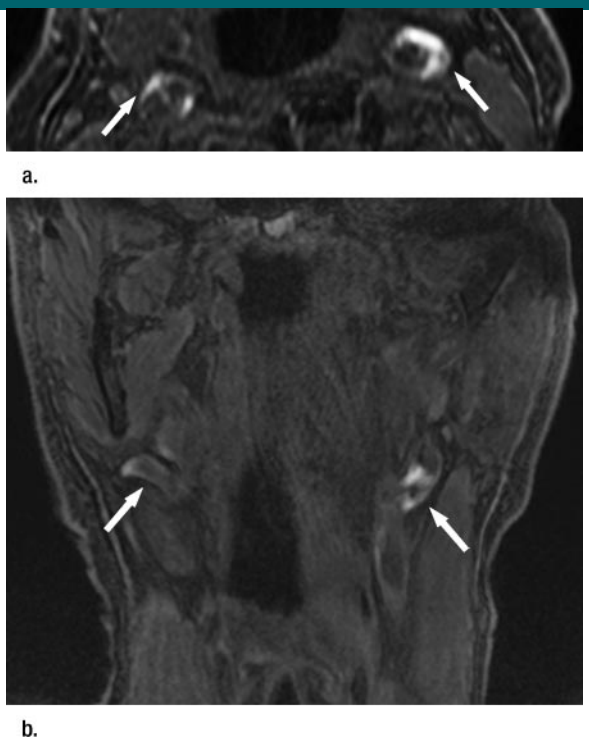

Figure 3: **(a)** Axial and **(b)** coronal MR images of a 77-year-old man with bilateral carotid artery vessel wall hyperintensities signifying MR-depicted IPH (arrows).

Discussion

Our study results show that, in men with asymptomatic moderate carotid stenosis, future ipsilateral cerebrovascular events are associated with carotid IPH detected by using a rapid 3D T1-weighted fat-suppressed spoiled gradient-echo MR sequence. To our knowledge, the use of a simple MR technique to dichotomize asymptomatic patients in a routine clinical setting has not previously appeared in the literature. IPH may be a potential means with which to stratify the risk of future cerebrovascular events in asymptomatic patients with moderate carotid artery stenosis. This information may be used to assist in intervention decisions for asymptomatic patients with moderate carotid artery stenosis, who are commonly found among those with peripheral vascular disease. Clinical guidelines (4) for symptomatic patients with peripheral vascular disease recommend routine screening for asymptomatic carotid artery stenosis since the prevalence of stenosis greater than 50% is known to be approximately 30% in this population (13–15). Asymptomatic moderate stenosis is an independent risk factor for cerebrovascular events in patients with arterial disease (16), although it is insufficient for identifying patients that may benefit from CEA. MR screening for IPH of asymptomatic patients with moderate stenosis and peripheral vascular disease may help to further stratify patients to more clearly identify the risk of future ischemic events and the potential need for CEA. Our findings require validation. Until the prognostic importance of MR-depicted IPH is better understood, surgical treatment decisions cannot be determined on the basis of MR-depicted IPH status alone. The absence of IPH on MR images, however, might provide added reassurance for patients who choose a nonsurgical approach.

The MR technique we used is applicable on many commercially available imagers. The technique was originally devel-

oped on a Siemens MR system (10), but we used a GE system, with special inversion at lipids (Special; GE Healthcare) as the method of fat suppression. Other vendors' techniques implement a water-excitation pulse with an inversion pulse timed to null blood. The imaging technique only requires a single acquisition that is rapid (4–5 minutes), robust, and allows binary interpretation of the results. The 3D nature of the technique allows multiplanar viewing of the image data.

Our inclusion criteria were highly selective (ie, asymptomatic, moderate stenosis, male) to allow clearly defined results (ie, MR-depicted IPH and future cerebrovascular events). Arteries with a history of CEA were excluded to ensure that there was no surgical interference with the natural plaque progression.

We have shown that IPH is associated with future ipsilateral cerebrovascular events with a hazard ratio of 3.59 (95% CI: 2.48, 4.71; $P < .001$), suggesting that IPH is a promising marker for patients at risk for future cerebrovascular events. Our findings are in line with those (hazard ratio, 5.2; $P = .005$) reported by Takaya et al (17) for the relationship between IPH and future ipsilateral cerebrovascular events. Their study used a population with asymptomatic moderate stenosis, as did we, but they employed a multicontrast-weighted MR sequence instead of the simple single rapid 3D T1-weighted gradient-echo sequence we used. The time-of-flight sequence used by Takaya et al demonstrated increased signal intensity and findings similar to those with our sequence. In a larger cohort of patients, they were able to demonstrate the occurrence of a few cerebrovascular events in patients without IPH. Takaya et al suggest a decreased need for intervention in the group without MR-depicted IPH, with a requirement of close surveillance in view of the small but persistent risk. While there were no events in our study in the group without MR-depicted IPH, likely owing to small sample size, judicious surveillance is certainly required.

Other studies (18,19) have assessed the relationship of carotid MR-depicted IPH in vessel walls and ipsilateral cerebrovascular events in symptomatic rather than asymptomatic patients. Our study is in agreement with two recent studies by Altaf et al that concluded that the presence of carotid MR-depicted IPH predicts the recurrence of ipsilateral cerebrovascular events in symptomatic patients with high-grade stenosis (hazard ratio, 4.8; 95% CI: 1.1, 20.9; $P < .05$) (18) and midgrade stenosis (hazard ratio, 9.8; 95% CI: 1.3, 75.1; $P = .03$) (19). As in our study, in which no cerebrovascular events occurred in patients without carotid MR-depicted IPH, a high negative predictive value of IPH for cerebrovascular events was noted (18). Thus, despite differences in the natural progression of plaque in asymptomatic and symptomatic patients, IPH may also be a useful predictive marker for determining cerebrovascular outcomes in asymptomatic patients.

Research suggests that IPH is a feature of plaque instability. In a study of 63 symptomatic patients (10), histologic findings confirmed that the MR technique we used depicts complicated plaque. Prevalence of MR-depicted IPH was significantly greater in vessels ipsilateral to neuroischemia, as compared with the contralateral asymptomatic side (60% vs 36%; $P < .001$ [χ^2 test]), particularly for vessels with only moderate stenosis (20). Similar findings were reported in a study of 370 arteries (21) in which previous ipsilateral ischemic events were associated with high signal intensity in vessels with 0%–29% (relative risk, 2.50; 95% CI: 0.96, 6.51), 30%–69% (relative risk, 7.55; 95% CI: 1.84, 31.04), and 70%–99% (relative risk, 1.98; 95% CI: 1.01, 3.90) stenosis. MR-depicted IPH also predicts embolization in patients with high-grade symptomatic stenosis during the dissection phase of CEA (22).

Table 1

Patient Characteristics for 98 Carotid Arteries by Presence of MR-depicted IPH

Characteristic	MR-depicted IPH		*P* Value
	Present ($n = 36$)	Absent ($n = 62$)	
Age (y)*	75.9 ± 6.06	74.1 ± 8.82	.092†
Follow-up (mo)*	23.9 ± 11.5	25.5 ± 9.84	.310†
Patient history‡			
Hypertension	25 (69.4)	50 (80.6)	.207§
Diabetes mellitus	8 (22.2)	11 (17.7)	.589§
Dyslipidemia	26 (72.2)	44 (71.0)	.895§
Myocardial infarction	3 (8.3)	11 (17.7)	.199§
Atrial fibrillation	4 (11.1)	6 (9.7)	.821§
Smoking	32 (88.9)	45 (72.6)	.058§
Baseline medication type‡			
Hypertension	25 (69.4)	48 (77.4)	.383§
Diabetes mellitus	7 (19.4)	10 (16.1)	.676§
Statin	24 (66.7)	44 (71.0)	.656§
Aspirin	26 (72.2)	43 (69.4)	.764§
Heparin or warfarin	3 (8.3)	7 (11.3)	.641§
Antiplatelet	6 (16.7)	11 (17.7)	.892§
Follow-up medication type‡			
Hypertension	27 (75.0)	49 (79.0)	.645§
Diabetes mellitus	7 (19.4)	14 (22.6)	.715§
Statin	23 (63.9)	45 (72.6)	.326§
Aspirin	29 (80.6)	48 (77.4)	.715§
Heparin or warfarin	7 (19.4)	8 (12.9)	.386§
Antiplatelet	9 (25.0)	20 (32.3)	.448§

* Unless otherwise noted, data are means ± standard deviations.

† Mann-Whitney test.

‡ Unless otherwise noted, data are numbers of arteries, with percentages in parentheses.

§ Two-sided χ^2 test.

Table 2

Characteristics of 75 Patients Grouped by using a Per-Patient Design

Characteristic	MR-depicted IPH		*P* Value
	Present (n = 31)	Absent (n = 44)	
Age (y)*	75.9 ± 6.20	74.2 ± 8.91	.110†
Follow-up (mo)*	23.3 ± 11.8	26.2 ± 9.7	.168†
Patient history‡			
Hypertension	21 (67.7)	35 (79.5)	.288§
Diabetes mellitus	6 (19.4)	7 (15.9)	.762§
Dyslipidemia	23 (74.2)	31 (70.5)	.798§
Myocardial infarction	3 (9.7)	9 (20.5)	.338§
Atrial fibrillation	3 (9.7)	3 (6.8)	.687§
Smoking	28 (90.3)	31 (70.5)	.048§
Baseline medication type‡			
Hypertension	21 (67.7)	33 (75.0)	.603§
Diabetes mellitus	5 (16.1)	7 (15.9)	>.99§
Statin	21 (67.7)	32 (72.7)	.797§
Aspirin	23 (74.2)	31 (70.5)	.798§
Heparin or warfarin	2 (6.5)	5 (11.4)	.693§
Antiplatelet	5 (16.1)	10 (22.7)	.567§
Follow-up medication type‡			
Hypertension	23 (74.2)	35 (79.5)	.590§
Diabetes mellitus	5 (16.1)	9 (20.5)	.767§
Statin	21 (67.7)	33 (75.0)	.435§
Aspirin	25 (80.6)	34 (77.3)	.782§
Heparin or warfarin	5 (16.1)	5 (11.4)	.732§
Antiplatelet	9 (29.0)	16 (36.4)	.621§

* Unless otherwise noted, data are means ± standard deviations.

† Mann-Whitney test.

‡ Unless otherwise noted, data are numbers of patients, with percentages in parentheses.

§ Two-sided χ^2 test.

Figure 4

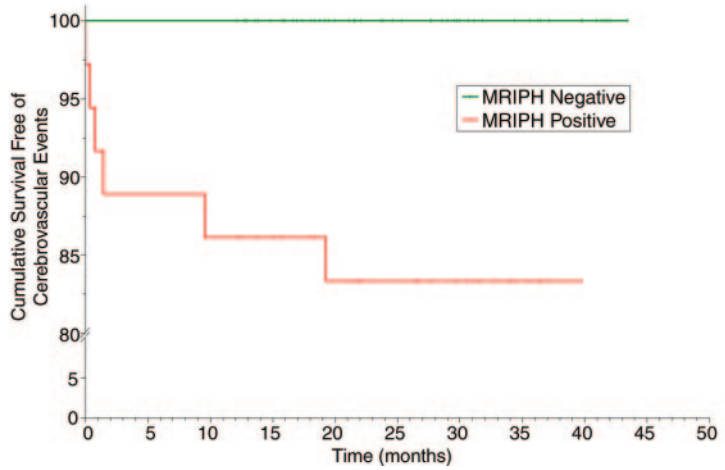

Figure 4: Kaplan-Meier plot of the incidence of cerebrovascular events between arteries with *(MRIPH Positive)* and those without *(MRIPH Negative)* MR-depicted IPH.

Larger prospective studies are warranted to determine the value of carotid MR-depicted IPH in predicting stroke. Its ability to predict cerebrovascular events in women and in patients with other degrees of stenosis also requires further investigation.

Our study had limitations. It was a retrospective review with a relatively small sample size from a single institution. We used a combined outcome of stroke or transient ischemic attack, but prevention of stroke, rather than transient ischemic attack, is the major clinical event that drives surgical intervention in carotid stenosis. The limited sample size and number of events despite the 2-year follow-up for our study necessitated clustering of cerebrovascular events and prevented testing the ability of carotid MR-depicted IPH to serve as an independent risk factor for stroke with multivariate Cox regression analysis. Our length of follow-up may have been insufficient to detect all events. We used clinical definitions for transient ischemic attack and stroke; however, the inclusion of an event required diagnosis by a physician. As in previous studies (17,21), patients were classified as asymptomatic if they had had an absence of symptoms for 6 months.

We analyzed MR data from a single point in time. Temporal changes in hemorrhagic plaque were not evaluated by way of repeat MR measurement in our study. Yamada et al (21) previously demonstrated that comparison of the volume of the hyperintensity between successive MR imaging sessions does not change significantly (P = .690) in arteries (median interval, 279 days; range, 10–1037 days).

Lastly, the MR technique we used has low spatial resolution. However, this does not interfere with the dichotomous interpretation of images. A recent study (23) has shown the use of a high spatial resolution technique to localize IPH on the basis of high signal intensity.

In men with asymptomatic moderate carotid stenosis, future ipsilateral cerebrovascular events are associated with carotid IPH detected by using a rapid 3D T1-weighted fat-suppressed spoiled gradient-echo MR sequence.

Acknowledgments: Many thanks to Jennifer Jeffrey, BA, Heather Amadori, BSc, and the Vascular Biology Imaging Research Group at Sunnybrook Health Sciences Centre for study support.

References

1. Elkins JS, Johnston SC. Thirty-year projections for deaths from ischemic stroke in the United States. Stroke 2003;34(9):2109–2112.
2. Barnett HJ, Taylor DW, Eliasziw M, et al. Benefit of carotid endarterectomy in patients with symptomatic moderate or severe stenosis: North American Symptomatic Carotid Endarterectomy Trial Collaborators. N Engl J Med 1998;339(20):1415–1425.
3. Halliday A, Mansfield A, Marro J, et al. Prevention of disabling and fatal strokes by successful carotid endarterectomy in patients without recent neurological symptoms: randomised controlled trial. Lancet 2004; 363(9420):1491–1502.
4. Qureshi AI, Alexandrov AV, Tegeler CH, et al. Guidelines for screening of extracranial carotid artery disease: a statement for healthcare professionals from the multidisciplinary practice guidelines committee of the American Society of Neuroimaging—cosponsored by the Society of Vascular and Interventional Neurology. J Neuroimaging 2007;17(1):19–47.
5. Rao DS, Goldin JG, Fishbein MC. Determinants of plaque instability in atherosclerotic vascular disease. Cardiovasc Pathol 2005; 14(6):285–293.
6. Virmani R, Kolodgie FD, Burke AP, et al. Atherosclerotic plaque progression and vulnerability to rupture: angiogenesis as a source of intraplaque hemorrhage. Arterioscler Thromb Vasc Biol 2005;25(10):2054–2061.
7. Kolodgie FD, Narula J, Yuan C, Burke AP, Finn AV, Virmani R. Elimination of neoangiogenesis for plaque stabilization: is there a role for local drug therapy? J Am Coll Cardiol 2007;49(21):2093–2101.
8. Iemolo F, Martiniuk A, Steinman DA, Spence JD. Sex differences in carotid plaque and stenosis. Stroke 2004;35(2):477–481.
9. Dick P, Sherif C, Sabeti S, Amighi J, Minar E, Schillinger M. Gender differences in outcome of conservatively treated patients with asymptomatic high grade carotid stenosis. Stroke 2005;36(6):1178–1183.
10. Moody AR, Murphy RE, Morgan PS, et al. Characterization of complicated carotid plaque with magnetic resonance direct thrombus imaging in patients with cerebral ischemia. Circulation 2003;107(24):3047–3052.
11. Wardlaw JM, Chappell FM, Best JJ, Wartolowska K, Berry E. Non-invasive imaging compared with intra-arterial angiography in the diagnosis of symptomatic carotid stenosis: a meta-analysis. Lancet 2006;367(9521): 1503–1512.
12. Maldonado TS. What are current preprocedure imaging requirements for carotid artery stenting and carotid endarterectomy: have magnetic resonance angiography and computed tomographic angiography made a difference? Semin Vasc Surg 2007;20(4): 205–215.
13. Pilcher JM, Danaher J, Khaw KT. The prevalence of asymptomatic carotid artery disease in patients with peripheral vascular disease. Clin Radiol 2000;55(1):56–61.
14. House AK, Bell R, House J, Mastaglia F, Kumar A, D'Antuono M. Asymptomatic carotid artery stenosis associated with peripheral vascular disease: a prospective study. Cardiovasc Surg 1999;7(1):44–49.
15. Cina CS, Safar HA, Maggisano R, Bailey R, Clase CM. Prevalence and progression of internal carotid artery stenosis in patients with peripheral arterial occlusive disease. J Vasc Surg 2002;36(1):75–82.
16. Goessens BM, Visseren FL, Kappelle LJ, Algra A, van der Graaf Y. Asymptomatic carotid artery stenosis and the risk of new vascular events in patients with manifest arterial disease: the SMART study. Stroke 2007;38(5): 1470–1475.
17. Takaya N, Yuan C, Chu B, et al. Association between carotid plaque characteristics and subsequent ischemic cerebrovascular events: a prospective assessment with MRI—initial results. Stroke 2006; 37(3):818–823.
18. Altaf N, MacSweeney ST, Gladman J, Auer DP. Carotid intraplaque hemorrhage predicts recurrent symptoms in patients with high-grade carotid stenosis. Stroke 2007; 38(5):1633–1635.
19. Altaf N, Daniels L, Morgan PS, et al. Detection of intraplaque hemorrhage by magnetic resonance imaging in symptomatic patients with mild to moderate carotid stenosis predicts recurrent neurological events. J Vasc Surg 2008;47(2):337–342.
20. Murphy RE, Moody AR, Morgan PS, et al. Prevalence of complicated carotid atheroma as detected by magnetic resonance direct thrombus imaging in patients with suspected carotid artery stenosis and previous acute cerebral ischemia. Circulation 2003;107 (24):3053–3058.
21. Yamada N, Higashi M, Otsubo R, et al. Association between signal hyperintensity on T1-weighted MR imaging of carotid plaques and ipsilateral ischemic events. AJNR Am J Neuroradiol 2007;28(2):287–292.
22. Altaf N, Beech A, Goode SD, et al. Carotid intraplaque hemorrhage detected by magnetic resonance imaging predicts embolization during carotid endarterectomy. J Vasc Surg 2007;46(1):31–36.
23. Bitar R, Moody AR, Leung G, et al. In vivo 3D high-spatial-resolution MR imaging of intraplaque hemorrhage. Radiology 2008; 249(1):259–267.