This copy is for personal use only. To order printed copies, contact *reprints@rsna.org*

Role of Optimal Quantification of FDG PET Imaging in the Clinical Practice of Radiology[1]

Pouya Ziai, MD
Mohammad Reza Hayeri, MD, MPH[2]
Aliaksei Salei, MD
Ali Salavati, MD, MPH[3]
Sina Houshmand, MD
Abass Alavi, MD
Oleg M. Teytelboym, MD

Abbreviations: FDG = fluorine 18 fluorodeoxyglucose, PERCIST = PET Response Criteria in Solid Tumors, ROI = region of interest, SUL = standardized uptake normalized on the basis of lean body mass, SUV = standardized uptake value

RadioGraphics 2016; 36:481–496

Published online 10.1148/rg.2016150102

Content Codes: MI NM OI

[1]From the Department of Radiology, Mercy Catholic Medical Center, 1500 Lansdowne Ave, Darby, PA 19023 (P.Z., M.R.H., A. Salei, O.M.T.); and Department of Radiology, Hospital of the University of Pennsylvania, Philadelphia, Pa (A. Salavati, S.H., A.A.). Presented as an education exhibit at the 2014 RSNA Annual Meeting. Received April 7, 2015; revision requested July 28 and received October 25; accepted November 24. For this journal-based SA-CME activity, the authors, editor, and reviewers have disclosed no relevant relationships. **Address correspondence to** O.M.T. (e-mail: *olegmt@gmail.com*).

[2]**Current address:** Department of Radiology, University of California San Diego Medical Center, San Diego, Calif.

[3]**Current address:** Department of Radiology, University of Minnesota, Minneapolis, Minn.

©RSNA, 2016

The combination of fluorine 18 fluorodeoxyglucose (FDG) positron emission tomography (PET) and computed tomography (CT) for dual-modality imaging (PET/CT) plays a key role in the diagnosis and staging of FDG-avid malignancies. FDG uptake by the tumor cells offers an opportunity to detect cancer in organs that appear normal at anatomic imaging and to differentiate viable tumor from posttreatment effects. Quantification of FDG uptake has multiple clinical applications, including cancer diagnosis and staging. Dedicated FDG PET/CT–based visual and quantitative criteria have been developed to evaluate treatment response. Furthermore, the level of tumor FDG uptake reflects the biologic aggressiveness of the tumor, predicting the risk of metastasis and recurrence. FDG uptake can be measured with qualitative, semiquantitative, and quantitative methods. Qualitative or visual assessment of PET/CT images is the most common clinical approach for describing the level of FDG uptake. Standardized uptake value (SUV) is the most commonly used semiquantitative tool for measuring FDG uptake. SUV can be measured as maximum, mean, or peak SUV and may be normalized by using whole or lean body weight. SUV measurements provide the basis for quantitative response criteria; however, SUVs have not been widely adopted as diagnostic thresholds for discriminating malignant and benign lesions. Volumetric FDG uptake measurements such as metabolic tumor volume and total lesion glycolysis have shown substantial promise in providing accurate tumor assessment. SUV measurement and other quantification techniques can be affected by many technical, physical, and biologic factors. Familiarity with FDG uptake quantification approaches and their pitfalls is essential for clinical practice and research.

©RSNA, 2016 • *radiographics.rsna.org*

SA-CME LEARNING OBJECTIVES

After completing this journal-based SA-CME activity, participants will be able to:

- Discuss different approaches to FDG uptake assessment and their clinical applications.
- Discuss quantitative PET-based tumor response criteria.
- Identify factors that can affect the reproducibility of SUV measurement.

See www.rsna.org/education/search/RG.

Introduction

Cancer is the second most common cause of mortality in developed countries; and with rapid aging of the world's population, it will soon become the leading cause of death. During the past decades, fluorine 18 fluorodeoxyglucose (FDG) positron emission tomography (PET), combined with computed tomography (CT), has been adopted as an essential tool for the diagnosis and management of cancer. Multiple new PET radiotracers have been developed during the past several decades, with many clinical and research applications. However, FDG remains the most commonly used radiopharmaceutical in day-to-day practice.

TEACHING POINTS

- In some tumors, FDG PET/CT early in therapy can be used to predict treatment response, permitting early therapy modification. This use represents a considerable advance toward a future of cancer care in which treatment is tailored to cancer genetics and is rapidly modified on the basis of early response assessment.
- The accuracy of the visual interpretation is dependent on the reader's experience and knowledge of normal physiologic FDG distribution, common artifacts, tumor biology, and posttherapy changes.
- Normalization of SUV on the basis of lean body mass avoids confounding factors from fatty tissue and is a better representation of metabolic activity than body weight or surface area normalization.
- The effects of motion on SUV_{max} are often seen in the evaluation of lung and liver lesions near the diaphragm.
- Overall, for FDG-avid tumors such as lung cancer, the level of FDG uptake correlates with the risk of metastasis and makes metastasis easier to detect.

Dedicated FDG PET–based visual and quantitative criteria have been developed to facilitate assessment of treatment response (1–3). In some tumors, FDG PET/CT early in therapy can be used to predict treatment response, permitting early therapy modification. This use represents a considerable advance toward a future of cancer care in which treatment is tailored to cancer genetics and is rapidly modified on the basis of early response assessment.

The recent addition of quantitative measurements of FDG uptake has shown substantial promise in the assessment of tumor biology and, therefore, disease activity in many cancers (4). However, measurements of the standardized uptake value (SUV), a semiquantitative representation of tumor FDG uptake, in combination with visual evaluation, constitute the most common method used in clinical practice because of the ease of use. It has been well established that SUV measurements are affected by multiple technical, physical, and biologic factors (5). Therefore, knowledge of these confounding factors is essential for proper utilization of this powerful and effective method for optimal management of patients with cancer.

The purpose of this article is to review and illustrate these evolving concepts in depth, to provide a framework for optimal utilization of FDG PET imaging in clinical practice. First, FDG uptake assessment is considered, followed by dual time-point imaging, volumetric PET parameters, and confounding factors of SUV measurement. Then the various applications of FDG uptake measurement are detailed. Finally, PET response criteria are covered.

Table 1: Methods of FDG Uptake Assessment with Combined PET and CT

Method	Advantages and Disadvantages
Qualitative (visual inspection)	Simple scan, good image quality required
Semiquantitative (SUV)	Standardization required
Quantitative (kinetic modeling)	Complex data analysis, dynamic scan, limited FOV

FDG Uptake Assessment

Qualitative interpretation, semiquantitative measures, and absolute quantitative analysis can be used to assess FDG uptake with combined PET and CT (Table 1).

Qualitative Assessment

Qualitative assessment of FDG uptake is based on the visual evaluation of the images. The target lesion is compared with normal FDG uptake in the surrounding background or with the reference FDG uptake in the mediastinal blood pool or the liver. This comparison is often best performed on three-dimensional maximum intensity projection or coronal images, which facilitate comparison with the standard references.

At diagnostic or staging FDG PET/CT, lesions that asymmetrically stand out above background are likely to be abnormal. On posttreatment images, resolution of FDG uptake by the target lesion is suggestive of complete response. In response to curative therapy, a persistent or new intensely FDG-avid lesion is indicative of treatment failure. Version 1.1 of the Response Evaluation Criteria in Solid Tumors (RECIST 1.1), which is the latest version of the most commonly used anatomic response criteria, has incorporated a new intensely FDG-avid lesion as a sign of progression (6).

Persistent low to moderate FDG uptake by the target lesion after therapy was addressed in the Deauville response criteria (7), which were developed as a part of response-adapted therapy for lymphoma. These criteria use a 5-point scale for response assessment, comparing the target lesion FDG uptake to mediastinal blood pool and liver references (Table 2).

The accuracy of the visual interpretation is dependent on the reader's experience and knowledge of normal physiologic FDG distribution (Fig 1), common artifacts, tumor biology, and posttherapy changes. Visual assessment is the most common tool for FDG uptake evaluation used in typical clinical practice, and it shows adequate reliability in most clinical and many research settings.

Table 2: Deauville Criteria

Score	Definition	Clinical Importance
1	No uptake	Negative: possible to de-escalate treatment
2	Uptake less than or equal to that of mediastinal blood pool	Negative: possible to de-escalate treatment
3	Uptake more than that of mediastinal blood pool but less than or equal to that of liver	Negative if considering treatment escalation, positive if considering treatment de-escalation
4	Uptake moderately increased compared with that of liver	Positive: possible to escalate treatment
5	Uptake markedly increased compared with that of liver, or development of new lesions	Positive: possible to escalate treatment

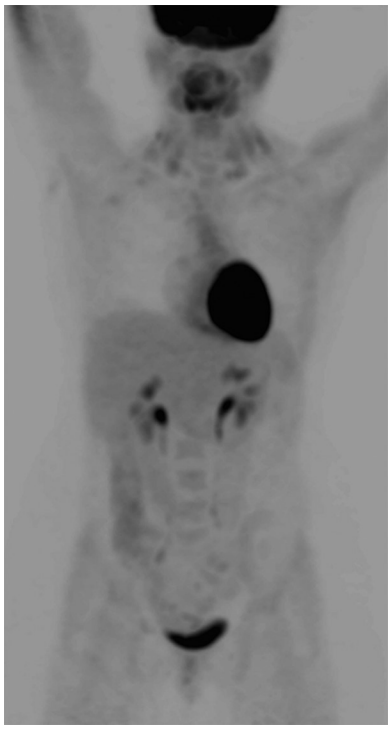

Figure 1. Normal physiologic distribution of FDG. Coronal maximum intensity projection reformatted PET image shows physiologic intense FDG uptake in the brain and heart and moderate FDG uptake in the liver, kidneys, and bone marrow. Note the variable uptake in the muscles and bowel. FDG undergoes urinary excretion, with intense FDG activity in the renal collecting systems, ureters, and bladder.

Quantitative and Semiquantitative Assessment

Quantification of FDG uptake has multiple clinical applications, including tumor diagnosis and response assessment in equivocal cases. It can provide information about metastatic potential and risk of recurrence, facilitate optimal biopsy site selection, and assist in radiation therapy planning.

Absolute quantification is technically challenging and quite complex and is not practical for routine clinical practice (8,9). To overcome these challenges, semiquantitative approaches have been introduced and have become the standard of care in clinical practice.

Measurement of the SUV is a semiquantitative normalization approach reflecting the degree of radiotracer uptake at a single point in time. The SUV of a given tissue is calculated by the following formula (10): SUV = tissue tracer activity/[injected dose/patient weight], where the SUV is measured in grams per milliliter, the tissue tracer activity is in kilobecquerels per milliliter, the injected dose is in kilobecquerels, and the patient weight is in grams.

Measuring the SUV generally requires an interactive workstation (such as an MIMvista [Mim Software, Cleveland, Ohio] or Advantage [GE Healthcare, Milwaukee, Wis] workstation); however, some of the modern picture archiving and communication systems (PACS) have built-in measurement tools. The measurement begins by drawing a two-dimensional or volumetric region of interest (ROI) surrounding the tumor or the area of interest. Two-dimensional measurement is less likely to inadvertently include an adjacent FDG-avid structure but can miss the most FDG-avid voxel of the tumor.

The measured tissue activity is normalized to the average radioactivity in the body on the basis of the patient's body weight (SUV_{bw}), lean body mass (SUV_{lbm}; also known as SUL), or body surface area (SUV_{bsa}) (11). Fat contributes to the patient weight but has low FDG uptake, leading to a relative increase in the SUV_{bw} in obese patients compared with the SUV_{bw} in thinner patients (12). Normalization of SUV on the basis of lean body mass avoids confounding factors from fatty tissue and is a better representation of metabolic activity than body weight or surface area normalization (12). Lean body mass is calculated in male subjects as 1.10 × weight – 128 × (weight^2/height^2), and in female subjects as 1.07 × weight – 148 × (weight^2/height^2), where weight is measured in kilograms, and height is in centimeters.

Table 3: Methods of Reporting SUV

SUV Parameter	Definition	Advantages	Disadvantages
SUV_{max}	Highest voxel value within the ROI	Independent of ROI size, less observer dependent than SUV_{mean}, more reproducible than SUV_{mean}	More susceptible to image noise
SUV_{mean}	Mean value of all voxels within the ROI	Less sensitive to image noise	More sensitive to ROI definition, subject to intra- and interobserver variability
SUV_{peak}	Mean value of radiotracer uptake within the ROI surrounding the pixel with the highest activity	Combines reproducibility of SUV_{max} and image noise reduction of SUV_{mean}	Reduced accuracy in the assessment of small lesions, compared with SUV_{max}; limited availability of the required automated measurement software

The SUV, independent of normalization, is commonly reported either as the maximum (SUV_{max}) or as the mean (SUV_{mean}) value of all voxels within an ROI (Table 3). The main advantage of SUV_{mean} is a reduced effect of image noise because the information is obtained from multiple voxels. A disadvantage of SUV_{mean} is sensitivity to inter- and intraobserver variability because the measurement is highly dependent on ROI size (13). Advantages of SUV_{max} include independence of ROI size and excellent intra- and interobserver variability. The main disadvantage of SUV_{max} is sensitivity to image noise and motion because the measurement represents a single-voxel value (14). The effects of motion on SUV_{max} are often seen in the evaluation of lung and liver lesions near the diaphragm. Motion can result in blurring of the target volume, consequently resulting in a reduction of the measured SUV_{max}, which is a highest-single-pixel value.

Peak SUV (SUV_{peak}) has been introduced in an attempt to decrease image noise and maintain the reproducibility of SUV_{max} (15). SUV_{peak} is a hybrid value measuring the mean value of radiotracer uptake within an ROI surrounding the highest-intensity voxel. The size, shape, and location of the ROI have a substantial effect on SUV_{peak} measurement (15). Wahl et al (2), in version 1.0 of the PET Response Criteria in Solid Tumors (PERCIST), suggested using a 1-cm^3 ROI surrounding the voxel with the highest activity. The mean value of the radiotracer activity within that ROI (SUV_{peak}) is then normalized to lean body mass and reported as peak SUL (SUL_{peak}) (2). The disadvantages of SUL_{peak} include the difficulty of small lesion evaluation and the need for specialized software, which currently is not widely available.

Overall, SUV_{max} normalized by whole or lean body weight has continued to be the most popular measurement technique in clinical practice, given its simplicity, reproducibility, and readily available software. SUL_{peak} may be a workable alternative, but current clinical adoption is hampered by the limited availability of the required automated measurement software.

Dual Time-Point Imaging

Dual time-point imaging, or delayed time-point imaging, was a concept introduced by Zhuang et al (16). In dual time-point imaging, after the standard initial scan at the first hour, the patient is rescanned at multiple time points (2 or 3 hours) after the injection of the radiotracer. The time interval between the injection of FDG and image acquisition determines the intensity of the FDG uptake and its clearance from the blood (17). Dual time-point imaging is based on the observation that the FDG uptake increases with time in malignant tissues until 4 hours after injection (18), whereas FDG uptake stays the same or decreases in inflammatory or infectious processes (19). This type of imaging can result in increased conspicuity of malignant tissues and increased sensitivity (Fig 2).

The effect of dual time-point imaging on the diagnosis, prognosis (20), and treatment planning (21) of different malignancies, including head and neck (22), lung (23), breast (24), and pancreatic (25) cancers, has been reported by investigators from multiple prior studies. However, the clinical utility of dual time-point imaging remains controversial because the results of some large studies have shown marked overlap of FDG uptake patterns between malignant and benign lesions on dual time-point images (26,27).

Currently, experts in the field recommend selective use of dual time-point imaging in equivocal cases to enhance the diagnostic accu-

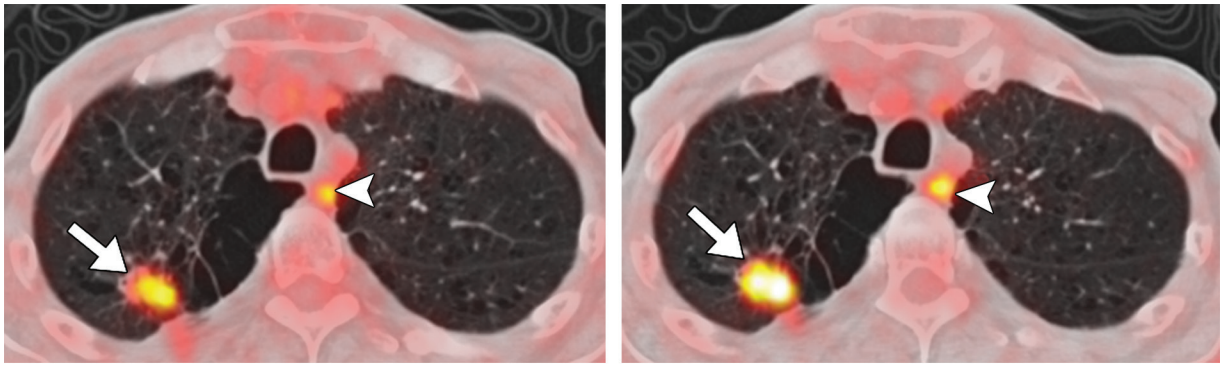

a. b.

Figure 2. Dual time-point imaging of a 57-year-old man with poorly differentiated adenocarcinoma of the lung. **(a)** Axial PET/CT image obtained at the initial time point shows a tumor with an SUV_{max} of 4.3 and SUV_{peak} of 2.8 (arrow). **(b)** Axial PET/CT image obtained 2 hours later shows the tumor with an SUV_{max} of 7.2 and SUV_{peak} of 3.9 (arrow), values that are higher compared with the initial time point. Dual time-point imaging offers better conspicuity of tumor compared with background. Normal physiologic distribution of FDG in the esophagus is marked by the arrowhead on both images.

racy of FDG PET (28). For example, when the suspicion for malignancy is high but the baseline FDG uptake is not high enough to establish the diagnosis, dual time-point imaging might show an increasing trend, helping to confirm the presence of malignancy. Dual time-point imaging is most often used for evaluation of lung nodules and pancreatic lesions.

Volumetric PET Parameters

Volumetric PET parameters consist of metabolic tumor volume and total lesion glycolysis. Metabolic tumor volume represents the volume of the tumor with active FDG uptake. Total lesion glycolysis is calculated by multiplying the SUV_{mean} of the total tumor by the metabolic tumor volume and represents both the tumor size and the extent of FDG uptake.

Metabolic tumor volume and total lesion glycolysis have been shown to correlate with risk stratification in various types of malignancies. For example, in two large meta-analysis studies comprising 1581 patients with non–small cell lung cancer (29) and 1180 patients with head and neck cancer (30), the patients with higher values of total lesion glycolysis and metabolic tumor volume demonstrated a greater risk of local-regional recurrence and progression and higher mortality. In addition, evidence exists that total lesion glycolysis and metabolic tumor volume outperform SUV_{max} and SUV_{mean} in the prediction of prognosis for patients with non–small cell lung cancer (31). Total lesion glycolysis can be used for tumor response assessment (Fig 3) (2,32); however, in formal response assessment criteria such as PERCIST, the use of total lesion glycolysis is suggested as an optional tool to assess tumor burden but is not proposed for response assessment (2).

SUV Measurement: Confounding Factors

SUV quantification is subject to several sources of variability arising from technical, physics-related, and biologic-physiologic factors (5,31–33) (Tables 4–6). SUV measurement is highly dependent on the drawn ROI, because a two-dimensional ROI can miss the highest-intensity voxel, and a three-dimensional ROI can inadvertently include an adjacent FDG-avid organ such as the bladder (Fig 4). Use of contrast agent–enhanced CT can improve lesion localization but may affect the accuracy of attenuation correction by overestimating the attenuation and, consequently, overestimate SUV (Fig 5). Respiratory motion can decrease the measured SUV of lesions near the diaphragm by blurring the lesion volume; SUV_{max} is particularly affected because it relies on the highest-intensity voxel (Fig 6).

The blood glucose level, insulin level, and body size calculation can have a substantial effect on SUV. A high blood glucose level competitively inhibits tumor uptake of FDG, causing underestimation of the SUV. A high level of insulin will stimulate muscle uptake of FDG, reducing its availability to the tumor. Measurement of the injected FDG amount is the most common source of technical errors, because of residual tracer in the syringe or extravasation from paravenous injection.

Individually, these factors have a relatively small effect on SUV measurement; however, cumulatively, these factors can have a major influence on SUV measurement. This influence may become particularly important in determining treatment response with quantitative PET criteria such as PERCIST. Erroneous SUV measurement may result in the continuation of ineffective therapy or the discontinuation of effective therapy.

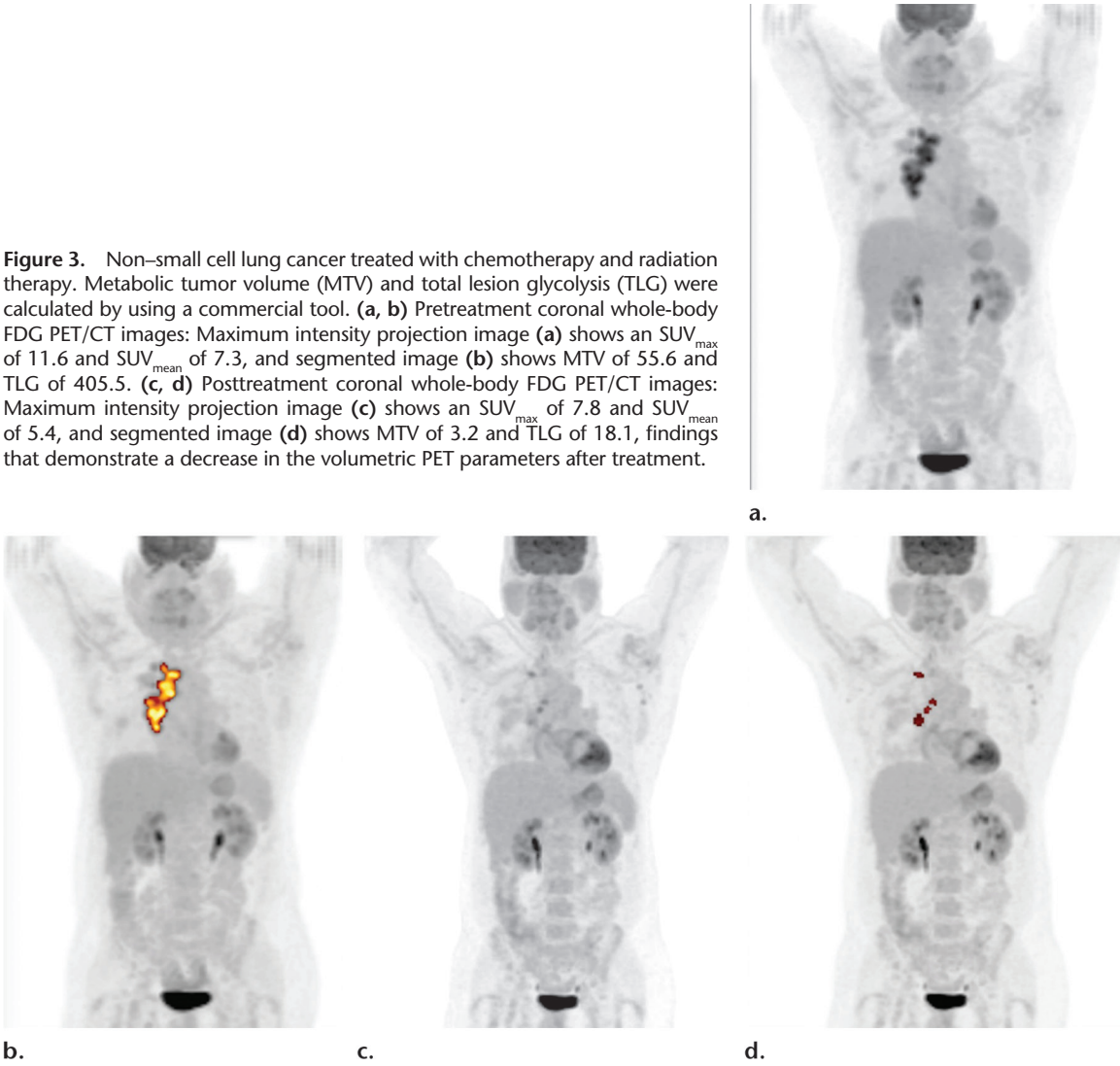

Figure 3. Non–small cell lung cancer treated with chemotherapy and radiation therapy. Metabolic tumor volume (MTV) and total lesion glycolysis (TLG) were calculated by using a commercial tool. **(a, b)** Pretreatment coronal whole-body FDG PET/CT images: Maximum intensity projection image **(a)** shows an SUV_{max} of 11.6 and SUV_{mean} of 7.3, and segmented image **(b)** shows MTV of 55.6 and TLG of 405.5. **(c, d)** Posttreatment coronal whole-body FDG PET/CT images: Maximum intensity projection image **(c)** shows an SUV_{max} of 7.8 and SUV_{mean} of 5.4, and segmented image **(d)** shows MTV of 3.2 and TLG of 18.1, findings that demonstrate a decrease in the volumetric PET parameters after treatment.

Strict standardization and thorough knowledge of the confounding factors are critical to avoid or minimize misinterpretation of the findings from PET examinations.

Applications of FDG Uptake Measurement

Diagnosis

The clinical use of FDG PET/CT in tumor diagnosis and staging primarily relies on qualitative interpretation. Many cancers show increased FDG uptake, a finding that helps to establish the diagnosis; however, the level of uptake can overlap with that for inflammatory diseases. Multiple SUV cutoff values have been proposed in an attempt to discriminate benign diseases from malignancies, but no universally reliable values have been identified.

Lung nodule evaluation is a common clinical indication for FDG PET/CT. One of the most popular thresholds during the early days of clinical adoption of FDG PET/CT was proposed by Fletcher et al (35), who suggested an SUV_{max} threshold of 2.5 to discriminate between benign and malignant lung lesions. However, the patients in the study of Fletcher et al (35) had solid nodules originally identified at chest radiography, with a 16-mm average nodule size. In the National Lung Screening Trial, in 64% of the subjects with positive results at screening, the largest nodule was 7 mm or less in diameter (36). Given its 5–7-mm inherent resolution, PET is unlikely to be helpful for the evaluation of most of the lung nodules identified during lung cancer screening.

Many slow-growing neoplasms demonstrate low SUV values, as illustrated by the behavior of subsolid lung nodules at FDG PET. Neoplastic subsolid lung nodules typically have nonaggressive histopathologic findings such as adenomatous hyperplasia, adenocarcinoma in situ, or minimally invasive adenocarcinoma and therefore are likely to have a low level of FDG uptake. In a study of subsolid nodules, Chun et al (37) found that the

Table 4: Technical Errors That Affect SUV Measurement

Factor	Description	Corrective Measures
Quality of FDG administration	Paravenous injection (extravasation)	Extravasation should be reported to avoid false interpretation
Residual activity in syringe	Represents approximately 5% of technical errors	Measure residual activity in the syringe to use exact administered dose for SUV calculations
Timing mismatch	A wrong time interval between injection and dose calibration results in an incorrect SUV because that interval is used for decay correction of the administered dose	The recommended interval between FDG administration and the start of acquisition is 60 minutes; calibrate the FDG dose calibrators; synchronize the dose calibrator clocks with the scanner clocks
Scanner variability	Different physical properties with different reconstruction and acquisition parameters	Use the same PET/CT scanner for baseline and follow-up imaging
Partial volume effect (PVC)	Caused by limited spatial resolution of the PET scanner; underestimation of SUV, especially for small lesions of less than 20 mm; aggravates even further in the lesions moving with cardiac and respiratory motion	Adopt an optimal partial volume correction factor; PVC was able to increase the accuracy of the estimates of SUV in lesions smaller than 2 cm from 55% to 89% in patients with lung cancer*
Inter- and intra-observer variability	Different observer equals different ROI	Use screen saves or other documentation to improve reproducibility of the marked ROI

Note.—PVC = partial volume correction.
*Data from reference 34.

Table 5: Physics-related Errors That Affect SUV Measurement

Factor	Description	Corrective Measures
ROI inaccuracy	Happens when 2D ROIs are not drawn on multiple axial sections covering the whole lesion to determine the highest activity	3D ROI preferred to 2D ROI; check coronal and sagittal planes to avoid including adjacent FDG-avid structures such as the bladder or heart
Acquisition, reconstruction, and processing parameters	Provided and recommended by the manufacturer, underestimation of SUV with highly smooth reconstruction algorithms	Use the same standardized acquisition and reconstruction parameters in serial scans of the same patient, for optimal comparison; use the same CT protocol for PET image attenuation correction
Use of CT contrast agents and presence of metallic or high-attenuation material	Overestimation of attenuation and therefore higher SUV may occur (upward bias)	Use the same CT protocol for PET image attenuation correction

Note.—3D = three-dimensional, 2D = two-dimensional.

SUV_{max} was significantly higher in inflammatory nodules (2.00 ± 1.18; range, 0.48–5.60) than in malignant nodules (1.26 ± 0.71; range, 0.32–2.6) (P = .018); all subsolid nodules with an SUV_{max} greater than 2.6 were benign.

Despite the absence of defined SUV thresholds, FDG PET/CT in appropriately selected patients can help to make the decision of whether biopsy is warranted. For example, a 2-cm solid lung nodule showing no FDG uptake is almost certainly benign, with a 97% negative predictive value for malignancy (35). There is no need to perform a biopsy, and the nodule can be safely followed with chest CT (Fig 7).

Prognosis

The inherent biologic aggressiveness of the tumor plays a substantial role in the survival of cancer patients. The ability to predict high-risk aggressive tumor behavior can help to develop

Table 6: Physiologic, Biologic, and Physical Errors That Affect SUV Measurement

Factor	Description	Corrective Measures
Respiratory motion	Can lead to inaccurate CT attenuation correction and bias in SUV; especially prevalent at the lung bases and upper abdomen	Improve patient comfort (immobilization devices) and patient information (clear instructions not to move and to breathe shallowly); respiratory motion correction approaches (breath holding in quiet end-expiration)
Blood glucose level	High levels competitively inhibit FDG uptake, causing underestimation of the SUV	Control of blood glucose level before FDG administration; most guidelines do not recommend SUV correction; other recommended approaches are to use insulin or reschedule the PET study (if level is more than 200 mg/dL)*
Body size calculation	Weight change during treatment could affect the validity of the measurement of SUV change	Measure weight with the same calibrated scale at the PET facility; normalization to body surface area or lean body mass (SUL), which are less dependent on weight changes

*Data from reference 32.

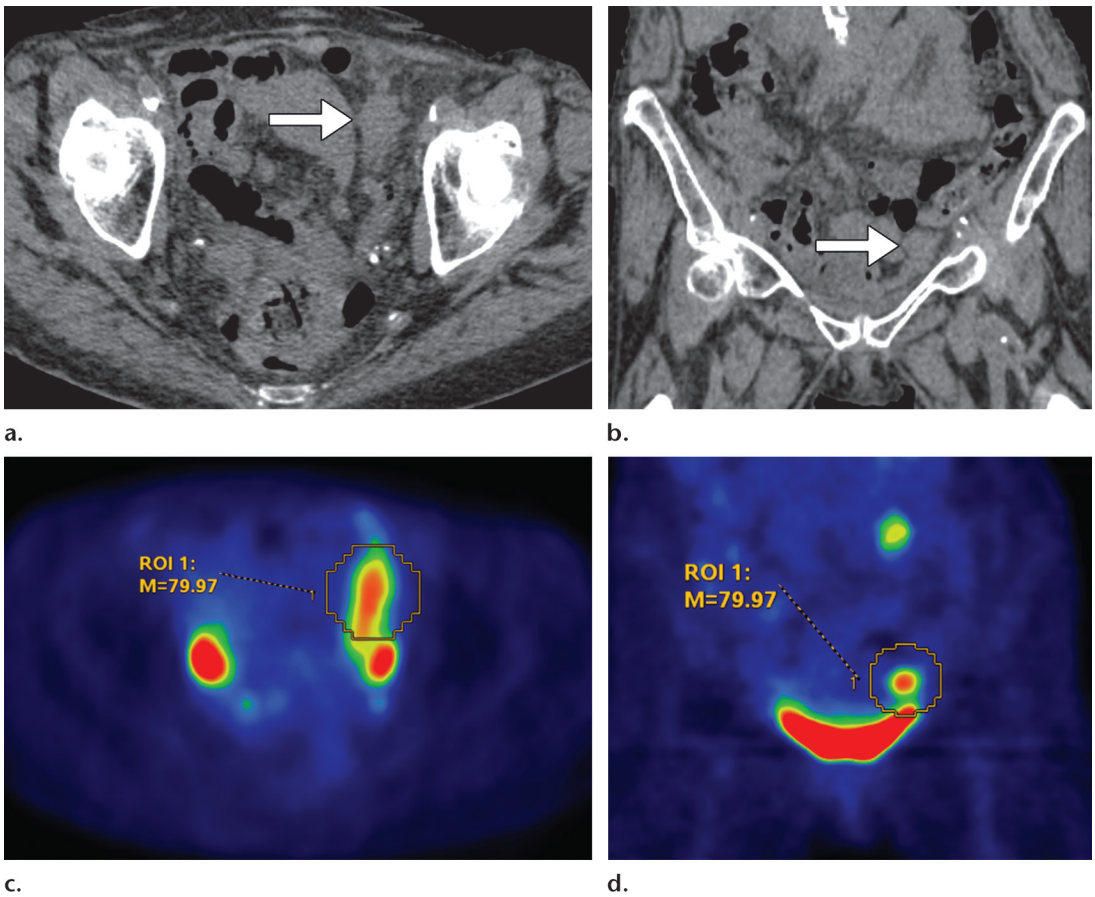

Figure 4. Metastatic lung adenocarcinoma in a 95-year-old woman. **(a, b)** Axial **(a)** and coronal **(b)** CT images show a peritoneal implant in the left lower quadrant (arrow). **(c, d)** On the axial **(c)** and coronal **(d)** PET images, the SUV_{max} of the peritoneal implant is overestimated by including the bladder in the volumetric ROI. This overestimation is not apparent on the axial images only, which do not show the full extent of the ROI. *(Fig 4 continues.)*

better treatment strategies and improve patient outcomes.

In multiple studies, investigators have demonstrated a strong correlation between the intensity of FDG uptake and the tumor prognosis in various types of malignancies, including lung, breast, and head and neck cancers (38–45). For example, in patients with non–small cell lung cancer, the

RadioGraphics

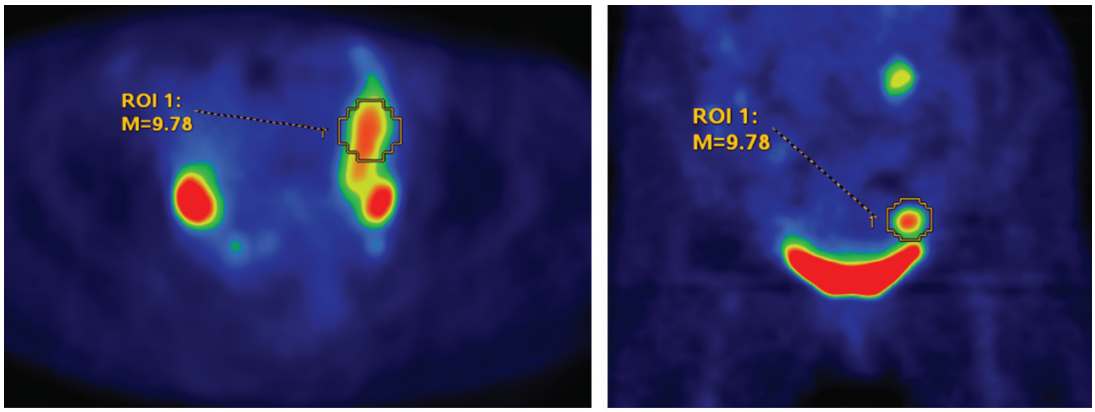

e. f.

Figure 4. *(continued)* **(e, f)** The SUV measurement was corrected by appropriate sizing of the ROI to exclude the bladder, as shown on the corrected axial **(e)** and coronal **(f)** PET images.

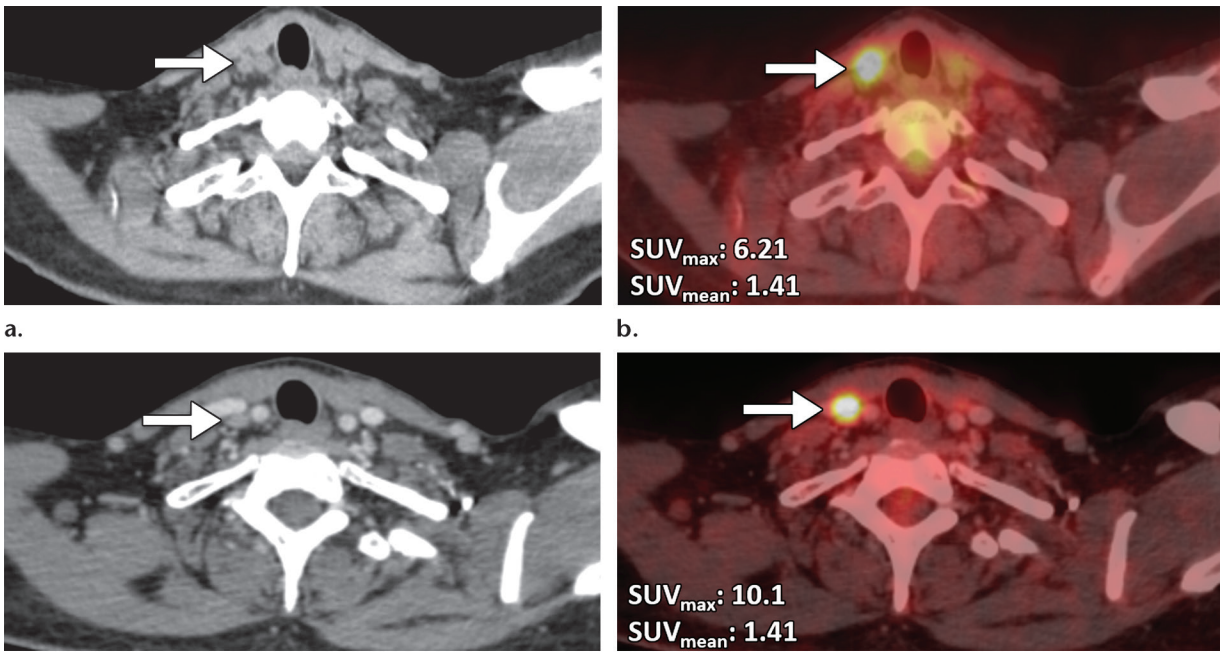

a. b. c. d.

Figure 5. Effect of intravenous contrast agent administration on SUV measurement in a 50-year-old woman with a biopsy-proven right lobe thyroid cancer. **(a, b)** Nonenhanced axial CT **(a)** and fused PET and CT **(b)** images show an SUV_{max} of 6.21 in the right cervical lymph node (arrow). **(c, d)** Contrast-enhanced axial CT **(c)** and fused PET and CT **(d)** images show an SUV_{max} of 10.1 for the lesion (arrow), which is an overestimation of the SUV caused by inaccurate attenuation correction.

SUV_{max} of the primary tumor has been shown to be an independent prognostic factor (38,40,42). In patients with non–small cell lung cancers, Cerfolio et al (42) showed that a high tumor SUV_{max} ($\geq$10) correlated with poorly differentiated tumors, an advanced TNM stage, and an inability to fully resect the tumor. Furthermore, SUV_{max} was a better predictor of survival and recurrence than the TNM stage for patients with early-stage resected tumors. In the findings from a meta-analysis of 13 studies, Berghmans et al (40) have confirmed the link between tumor SUV and patient prognosis.

In breast cancer, the intensity of primary tumor FDG uptake is also an independent prognostic factor (Figs 8, 9). In the results of multiple studies, investigators have demonstrated a positive correlation between the intensity of FDG uptake and different prognostic factors in breast cancer, such as tumor size, tumor grade, hormone receptor negativity, triple negativity, overexpression of c-erbB-2, axillary lymph node involvement, and proliferative activity assessed by Ki-67 immunostaining (39,41,44).

Staging

FDG PET/CT plays a key role in the staging of FDG-avid cancers. Identification of unsuspected distant metastasis at FDG PET/CT can

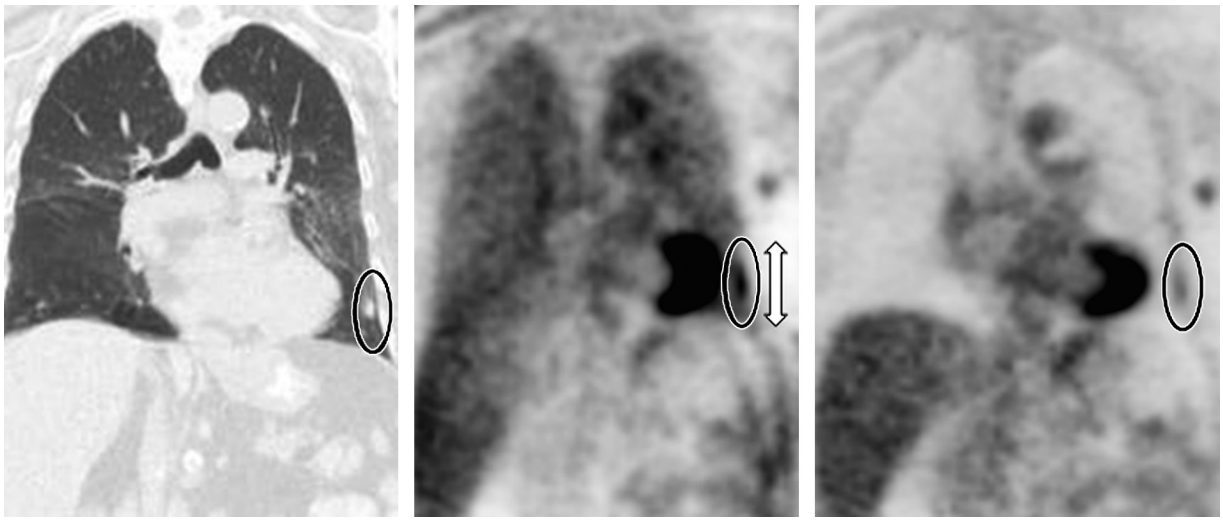

a. b. c.

Figure 6. Effect of respiratory motion on SUV measurement in a 61-year-old woman with a left lower lobe pulmonary nodule. **(a)** Coronal CT image shows an inconspicuous 5-mm solid nodule (within oval) close to the diaphragm. **(b, c)** Coronal PET images show that the nodule (oval) is easier to see on a PET image obtained without attenuation correction **(b)**, in comparison with an attenuation-corrected PET image **(c)**. Note the vertical smudging (double-headed arrow) of the FDG activity caused by respiratory motion on **b**. This smudging will falsely decrease the SUV_{max}, which is a highest-single-pixel value.

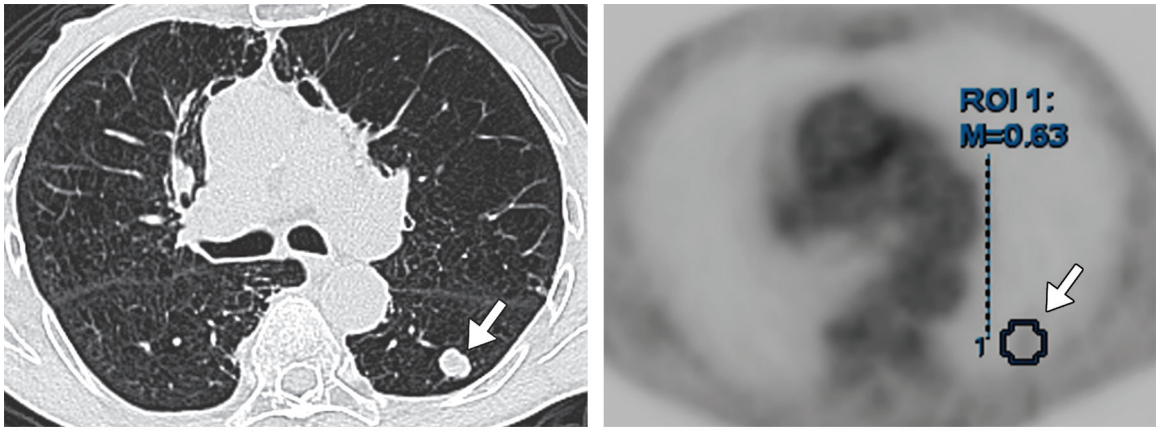

a. b.

Figure 7. Evaluation of a left lower lobe nodule in a 66-year-old man with a history of right upper lobe lung cancer. Axial CT **(a)** and fused PET and CT **(b)** images show a 1.3-cm well-circumscribed nodule (arrow) with low FDG uptake (SUV_{max} of 0.63), a value less than that of the mediastinal blood pool. The nodule was presumed to be a benign entity such as a hamartoma, and biopsy was not performed. The lesion was unchanged at a 2-year follow-up CT examination, a finding that helped confirm the benign etiology.

prevent costly and futile interventions. Awareness of the particular tumor biology, cancer-specific guidelines, and current National Comprehensive Cancer Network staging protocols is essential for appropriately using and interpreting FDG PET/CT during staging.

The National Oncologic PET Registry (NOPR) was used in a large study funded by Medicare to evaluate the effect of PET on staging in multiple malignancies that were not covered by Medicare at that point (46). On the basis of the PET results, physicians changed their intended management in approximately 37% of cases. In patients with a planned biopsy before PET, biopsy was avoided in approximately 70%. If the pre-PET strategy was treatment, the post-PET strategy involved a major change in the type of treatment in 8.7% of patients and in the therapeutic goal in 5.6%. The substantial clinical effect of PET during the NOPR study provided the basis for Medicare's decision to subsequently reimburse for PET staging for the malignancies included in the study.

The detectability of metastasis at FDG PET/CT depends on multiple factors, including lesion size, background, and motion. Lymph node metastases are a particular challenge because of both the tumor size and the wide range of physiologic FDG uptake by reactive lymph nodes.

RadioGraphics

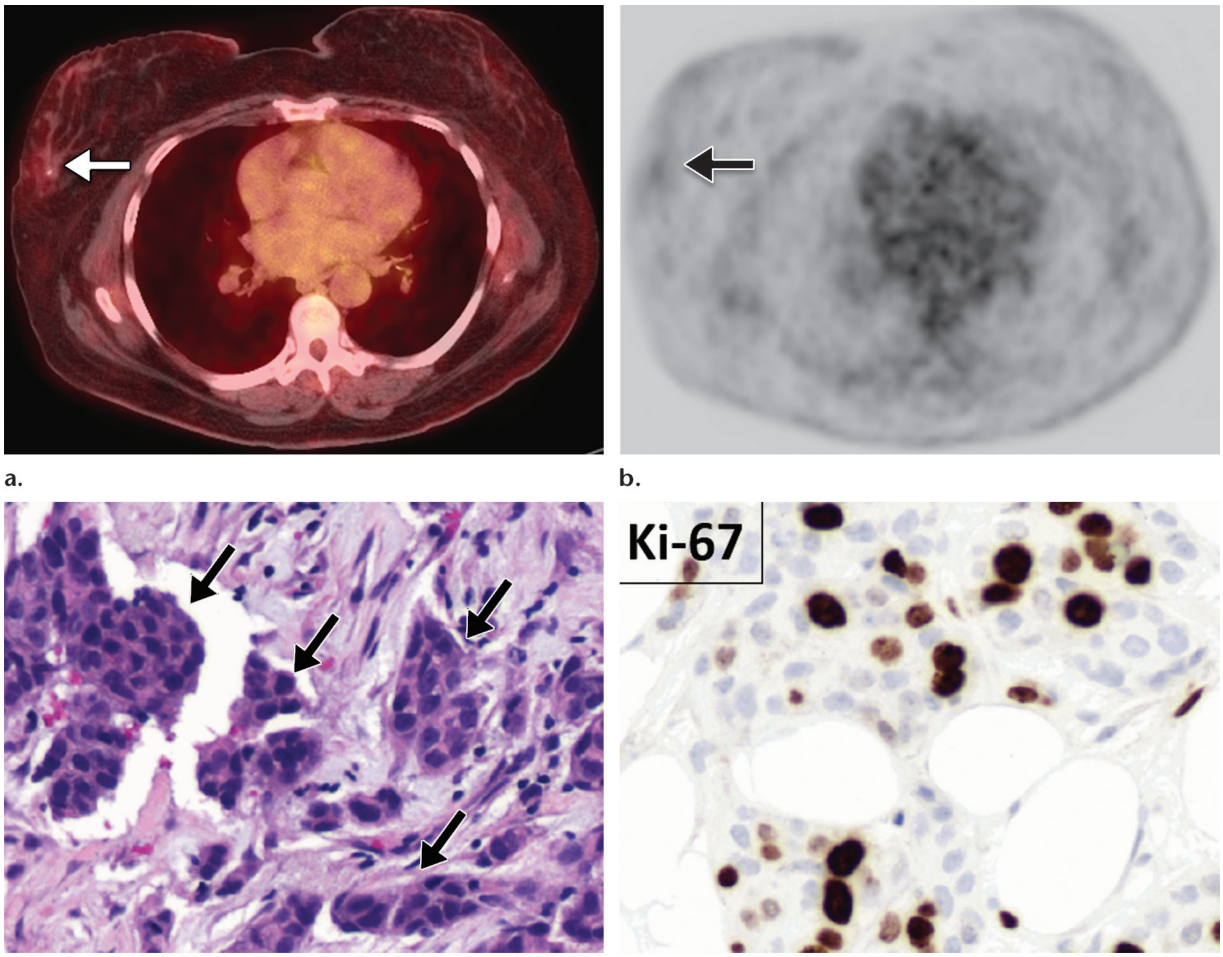

Figure 8. Positive correlation between the proliferation rate (Ki-67) and FDG uptake in breast cancer in a 56-year-old woman with invasive and in situ ductal carcinoma of the right breast. **(a, b)** Fused PET and CT **(a)** and PET **(b)** images show low FDG uptake (arrow) in the tumor, with an SUV_{max} of 2.4. **(c)** High-power photomicrograph shows clusters of malignant epithelial cells (arrows) in a desmoplastic stroma. (Hematoxylin-eosin stain; original magnification, ×400). **(d)** High-power photomicrograph obtained with Ki-67 staining shows proliferation (brown staining) and demonstrates a borderline proliferation rate of 10%. (Ki-67 stain; original magnification, ×400).

Tiny metastases, particularly in normal-sized lymph nodes, are undetectable with any modern imaging modality but can be found at surgical sampling (47). In patients with clinically resectable non–small cell lung cancer, Billé et al (48) reported that the sensitivity of PET/CT for the detection of malignant lymph node involvement was approximately 32% in nodes smaller than 10 mm and 85% in nodes measuring 10 mm or larger. In breast cancer, sentinel node excision is a standard part of breast cancer resection, given the inadequate performance of FDG PET/CT for detection of lymph node metastasis, with a 60% sensitivity and 82% specificity at visual assessment (47,49). At semiquantitative assessment with an SUV_{max} cutoff point of 1.8, metastatic lymph node detection is 100% specific but demonstrates a low sensitivity of only 36% (49).

Overall, for FDG-avid tumors such as lung cancer, the level of FDG uptake correlates with the risk of metastasis and makes metastasis easier to detect. Despite the challenges in the detection of lymph node metastases, patients with non–small cell lung cancer who are surgical candidates on the basis of PET/CT findings may not need additional confirmation and can proceed directly to surgery, although this remains controversial. N2 lymph node station involvement, which often precludes surgical resection, was predicted with 92% accuracy in a study by Bryant et al (50) and with 97% accuracy by Lee et al (51) by using a 5.3 SUV_{max} cutoff value of the primary tumor.

Treatment Response

Treatment response assessment is a key component of clinical cancer care and research. FDG PET response assessment is based on extensive evidence that FDG uptake in the tumor correlates with the number of viable cancer cells (2). Metabolic response assessment with FDG

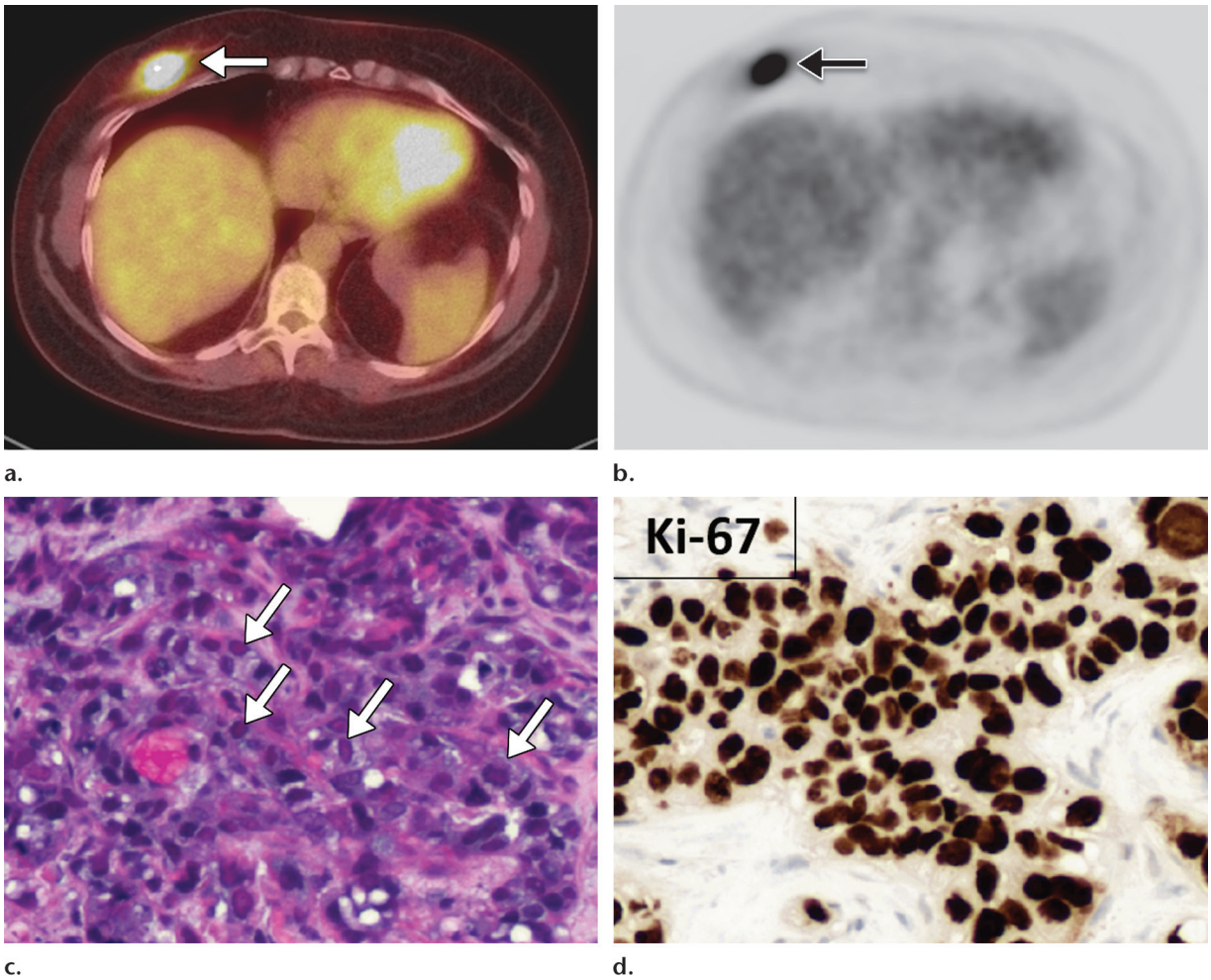

Figure 9. Positive correlation between the proliferation rate (Ki-67) and FDG uptake in breast cancer in a 57-year-old woman with invasive ductal carcinoma of the right breast. **(a, b)** Fused PET and CT **(a)** and PET **(b)** images show intense FDG uptake (arrow) in the tumor, with an SUV_{max} of 7.6. **(c)** High-power photomicrograph shows multiple malignant epithelial cells (arrows). (Hematoxylin-eosin stain; original magnification, ×400). **(d)** High-power photomicrograph obtained with Ki-67 staining shows a high proliferation rate of 76%. (Ki-67 stain; original magnification, ×400).

PET has been shown to be superior to anatomic criteria in predicting patient outcomes for many cancers, including lymphoma, non–small cell lung cancer, and esophageal cancer (2). In gastrointestinal stromal tumors treated with imatinib mesylate (Gleevec; Novartis, East Hanover, NJ), FDG PET can be used to determine efficacy within days of the start of therapy, with a marked reduction in FDG uptake predicting positive treatment response (52).

PET Response Criteria

Qualitative Response Criteria

Qualitative FDG PET/CT evaluation is the most commonly used approach in typical clinical practice, by using a visual comparison of the target lesion to the background, the mediastinal blood pool, or the liver. The first formalized qualitative PET response criteria were the revised International Working Group (or International Workshop Coalition [IWC]) with PET criteria (IWC+PET) for the evaluation of lymphoma treatment response, which were published in 2007 (53), evolving from the gallium-based 1999 IWC criteria (54). Mediastinal blood pool activity was recommended as the reference point to define PET positivity for a residual mass measuring 2 cm or more in the greatest transverse diameter. Findings of smaller lesions or a normal-sized lymph node were considered positive if the activity was higher than that of the surrounding background (55).

Subsequent evolution of the IWC+PET criteria has led to development of the Deauville criteria (Table 2) for FDG PET/CT in the response assessment of Hodgkin and FDG-avid non-Hodgkin lymphomas (1). In the current National Comprehensive Cancer Network treatment guidelines, the Deauville criteria are used to guide therapy during midtreatment and end-of-treatment assessment. PET results are negative when the residual lesion has FDG uptake less

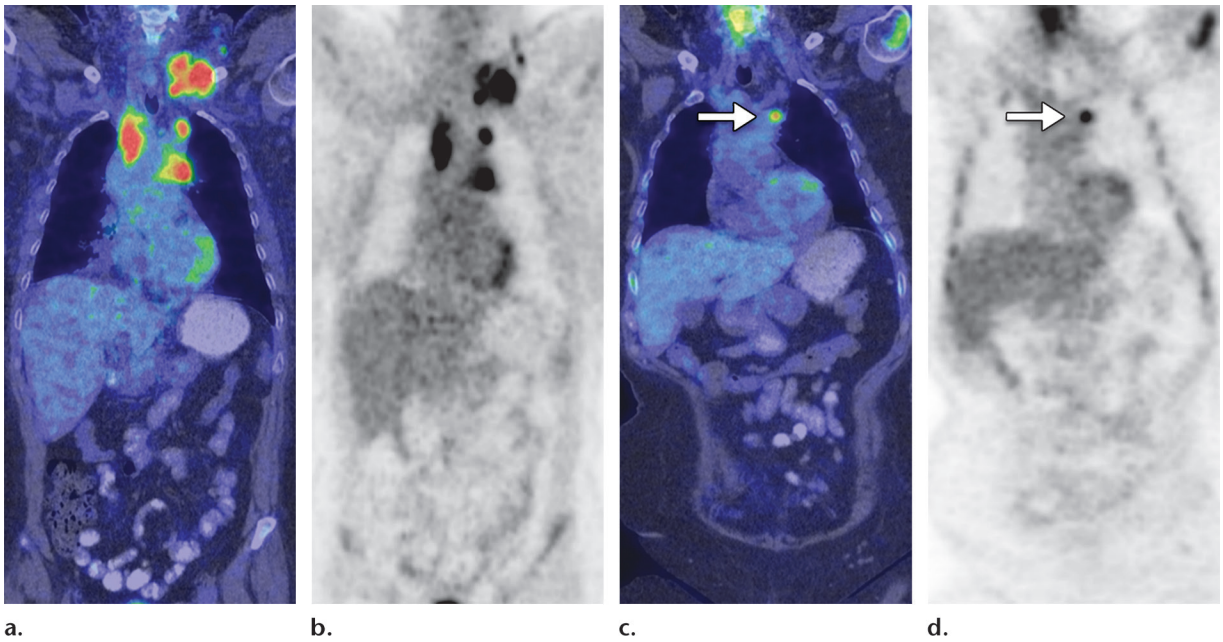

Figure 10. Stage II Hodgkin lymphoma in a 23-year-old man. **(a, b)** Pretherapy coronal fused PET and CT **(a)** and PET **(b)** images show a large intensely FDG-avid anterior mediastinal mass abutting the aortic arch and the pulmonary artery, findings that are consistent with Hodgkin lymphoma. **(c, d)** Interim FDG PET/CT was performed after two cycles of chemotherapy: Coronal fused PET and CT **(c)** and PET **(d)** images show an interval decrease in the size and FDG avidity of the mediastinal uptake. However, an area of focal intense FDG uptake (arrow), which is markedly more than that of the liver, remains in the superior left mediastinum (Deauville score, 5).

than that of the mediastinal blood pool (Deauville 1 or 2), a finding permitting de-escalation of therapy. PET results are positive when the residual lesion has FDG uptake higher than that of the liver (Deauville 4 and 5), a finding permitting escalation of therapy (Fig 10). Residual lesion FDG uptake that is between the level of the mediastinal blood pool and that of the liver (Deauville 3) is regarded *(a)* as positive when considering de-escalation of therapy or *(b)* as negative when considering escalation of therapy. Midtherapy assessment facilitated by the Deauville criteria represents an important advance for therapy in patients with lymphoma.

Formal visual assessment scales have not been developed for most malignancies; however, a similar approach works in most common clinical situations, by using the mediastinal blood pool and the liver as visual references. Visual assessment of FDG uptake is not useful in tumors that are not substantially FDG avid, such as some of the lymphomas or musculoskeletal neoplasms.

Quantitative Response Criteria

Despite the clinical and trial usefulness of qualitative response criteria, it is apparent that a substantial amount of information can be gained from quantitative assessment of PET, with SUV being the most commonly used value. The 1999 European Organization for Research and Treatment of Cancer (EORTC) recommendations for tumor response assessment represented the first attempt to use the quantitative approach for response assessment with PET. The EORTC recommendations used the percent SUV change to assign patients to a response category and emphasized the necessity of standardized patient preparation (3).

PERCIST 1.0, published in 2009 by Wahl et al (2), further standardized and refined quantitative PET criteria for response assessment. In PERCIST, definitions are provided for the appropriate settings for PET performance, the choice of the target lesions, data collection and recording (Table 7), and response criteria (Table 8). On the basis of a literature review and personal experience, Wahl et al (2) concluded that lean body mass–normalized SUV (SUL) is preferable to standard total body weight–normalized SUV because it has lesser susceptibility to patients' weight variations. Also, SUL_{peak} was suggested for use in response assessment, given its potentially lower susceptibility to noise than SUL_{max} (2). SUL_{peak} represents the largest possible mean value of a 1-cm^3 spherical volume of interest positioned within a tumor normalized with lean body mass. In later research, however, the same group of investigators showed that single-voxel maximum and peak values perform nearly identically (56).

In PERCIST, it was suggested that response should be determined on the basis of the difference in SUL between the tumor with the most intense SUL at baseline PET and the tumor with

Table 7: Characteristics of PERCIST 1.0

Determination of Characteristic	Definition
Which SUV value?	SUL_{peak}: lean body mass–normalized SUV
Measurable lesions?	Minimum uptake: 1.5 × liver mean SUL + 2 SD; alternative: 2 × mediastinal blood pool mean SUL
What size ROI?	1-cm^3 (1.2-cm diameter) fixed-dimension ROI centered on the highest-activity area in tumor
Number of lesions?	PERCIST 1.0 only evaluates the SUL_{peak} of the single highest-activity tumor
How to calculate percent change?	Percent change in SUL_{peak} for the most-active lesion at each time point between the pre- and posttreatment combined PET and CT imaging

Note.—SD = standard deviation.

Table 8: PERCIST 1.0 Criteria for Treatment Response

Treatment Response	Definition
Complete metabolic response	Visual disappearance of all metabolically active tumor
Partial response	SUL_{peak} decrease of 30% or more and 0.8 unit or more
Stable disease	SUL_{peak} decrease of less than 30% or increase of 30% or less
Progressive disease	SUL_{peak} increase of more than 30% and more than 0.8 unit, or new lesions

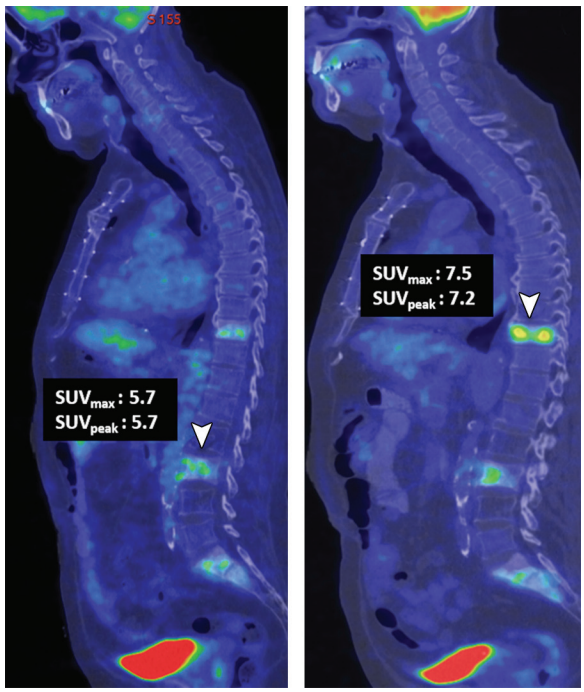

Figure 11. Metastatic lung cancer in a 65-year-old patient. **(a)** Pretherapy sagittal fused PET and CT image shows the most FDG-avid lesion (arrowhead) in the L3 vertebra, with an SUV_{max} of 5.7 and SUL of 5.7. **(b)** Posttherapy sagittal fused PET and CT image shows the most FDG-avid lesion (arrowhead) in the T10 vertebra, with an SUV_{max} of 7.5 and SUL of 7.2. After therapy, the SUV_{max} of the most-avid lesion has increased by 31.5%; however, the SUL has increased by 26%, in keeping with stable bone metastatic disease according to PERCIST criteria.

the most intense SUL at follow-up PET (Fig 11). However, Wahl et al (2) recommend collecting information on five lesions during trials, for further research and validation of the criteria. Although many questions remain unanswered, the groundwork of PERCIST represents a practical advance providing a common framework for cancer care and research.

Conclusion

FDG PET/CT plays a key role in the diagnosis and management of many cancer types. Diagnosis, staging, and some response criteria primarily rely on qualitative assessment of FDG uptake. Semiquantitative evaluation with SUV offers prognostic information, facilitates treatment planning, and provides the basis for quantitative response evaluation with PERCIST. Some of the new challenges for FDG PET/CT include cytostatic therapies and new drugs targeting tumor-specific mechanisms. Response adaptive therapy has become the standard of care for many lymphomas, with the use of midtherapy FDG PET/CT to predict treatment response and allow therapy modification. Future research is likely to offer similar opportunities for other malignancies.

References

1. Cheson BD, Fisher RI, Barrington SF, et al. Recommendations for initial evaluation, staging, and response assessment of Hodgkin and non-Hodgkin lymphoma: the Lugano classification. J Clin Oncol 2014;32(27):3059–3068.
2. Wahl RL, Jacene H, Kasamon Y, Lodge MA. From RECIST to PERCIST: evolving considerations for PET response criteria in solid tumors. J Nucl Med 2009;50(suppl 1):122S–150S.
3. Young H, Baum R, Cremerius U, et al; for the European Organization for Research and Treatment of Cancer (EORTC) PET Study Group. Measurement of clinical and subclinical tumour response using [18F]-fluorodeoxyglucose and positron emission tomography: review and 1999 EORTC recommendations. Eur J Cancer 1999;35(13):1773–1782.
4. Houshmand S, Salavati A, Hess S, Werner TJ, Alavi A, Zaidi H. An update on novel quantitative techniques in the context of evolving whole-body PET imaging. PET Clin 2015;10(1):45–58.
5. Adams MC, Turkington TG, Wilson JM, Wong TZ. A systematic review of the factors affecting accuracy of SUV measurements. AJR Am J Roentgenol 2010;195(2):310–320.
6. Eisenhauer EA, Therasse P, Bogaerts J, et al. New response evaluation criteria in solid tumours: revised RECIST guideline (version 1.1). Eur J Cancer 2009;45(2):228–247.
7. Gallamini A, Fiore F, Sorasio R, Meignan M. Interim positron emission tomography scan in Hodgkin lymphoma: definitions, interpretation rules, and clinical validation. Leuk Lymphoma 2009;50(11):1761–1764.
8. Lindholm P, Minn H, Leskinen-Kallio S, Bergman J, Ruotsalainen U, Joensuu H. Influence of the blood glucose concentration on FDG uptake in cancer: a PET study. J Nucl Med 1993;34(1):1–6.
9. Kim SK, Allen-Auerbach M, Goldin J, et al. Accuracy of PET/CT in characterization of solitary pulmonary lesions. J Nucl Med 2007;48(2):214–220.
10. Tse NY, Hoh CK, Hawkins RA, et al. The application of positron emission tomographic imaging with fluorodeoxyglucose to the evaluation of breast disease. Ann Surg 1992;216(1):27–34.
11. Gámez-Cenzano C, Pino-Sorroche F. Standardization and quantification in FDG-PET/CT imaging for staging and restaging of malignant disease. PET Clin 2014;9(2):117–127.
12. Zasadny KR, Wahl RL. Standardized uptake values of normal tissues at PET with 2-[fluorine-18]-fluoro-2-deoxy-D-glucose: variations with body weight and a method for correction. Radiology 1993;189(3):847–850.
13. Sugawara Y, Zasadny KR, Neuhoff AW, Wahl RL. Reevaluation of the standardized uptake value for FDG: variations with body weight and methods for correction. Radiology 1999;213(2):521–525.
14. Lucignani G. SUV and segmentation: pressing challenges in tumour assessment and treatment. Eur J Nucl Med Mol Imaging 2009;36(4):715–720.
15. Boellaard R, Krak NC, Hoekstra OS, Lammertsma AA. Effects of noise, image resolution, and ROI definition on the accuracy of standard uptake values: a simulation study. J Nucl Med 2004;45(9):1519–1527.
16. Zhuang H, Pourdehnad M, Lambright ES, et al. Dual time point 18F-FDG PET imaging for differentiating malignant from inflammatory processes. J Nucl Med 2001;42(9):1412–1417.
17. Houshmand S, Salavati A, Basu S, Khiewvan B, Alavi A. The role of dual and multiple time point imaging of FDG uptake in both normal and disease states. Clin Transl Imaging 2014;2(4):281–293.
18. Basu S, Kung J, Houseni M, Zhuang H, Tidmarsh GF, Alavi A. Temporal profile of fluorodeoxyglucose uptake in malignant lesions and normal organs over extended time periods in patients with lung carcinoma: implications for its utilization in assessing malignant lesions. Q J Nucl Med Mol Imaging 2009;53(1):9–19.
19. Alkhawaldeh K, Bural G, Kumar R, Alavi A. Impact of dual-time-point 18F-FDG PET imaging and partial volume correction in the assessment of solitary pulmonary nodules. Eur J Nucl Med Mol Imaging 2008;35(2):246–252.
20. Salavati A, Saboury B, Alavi A. Comment on: "Tumor aggressiveness and patient outcome in cancer of the pancreas assessed by dynamic 18F-FDG PET/CT." J Nucl Med 2014;55(2):350–351.
21. Whaley JT, Fernandes AT, Sackmann R, et al. Clinical utility of integrated positron emission tomography/computed tomography imaging in the clinical management and radiation treatment planning of locally advanced rectal cancer. Pract Radiat Oncol 2014;4(4):226–232.
22. Abgral R, Le Roux PY, Rousset J, et al. Prognostic value of dual-time-point 18F-FDG PET-CT imaging in patients with head and neck squamous cell carcinoma. Nucl Med Commun 2013;34(6):551–556.
23. Barger RL Jr, Nandalur KR. Diagnostic performance of dual-time 18F-FDG PET in the diagnosis of pulmonary nodules: a meta-analysis. Acad Radiol 2012;19(2):153–158.
24. Zytoon AA, Murakami K, El-Kholy MR, El-Shorbagy E. Dual time point FDG-PET/CT imaging: potential tool for diagnosis of breast cancer. Clin Radiol 2008;63(11):1213–1227.
25. Lyshchik A, Higashi T, Nakamoto Y, et al. Dual-phase 18F-fluoro-2-deoxy-D-glucose positron emission tomography as a prognostic parameter in patients with pancreatic cancer. Eur J Nucl Med Mol Imaging 2005;32(4):389–397.
26. Kim SJ, Kim YK, Kim IJ, Kim YD, Lee MK. Limited predictive value of dual-time-point F-18 FDG PET/CT for evaluation of pathologic N1 status in NSCLC patients. Clin Nucl Med 2011;36(6):434–439.
27. Kim SJ, Kim BH, Jeon YK, Kim SS, Kim IJ. Limited diagnostic and predictive values of dual-time-point 18F FDG PET/CT for differentiation of incidentally detected thyroid nodules. Ann Nucl Med 2011;25(5):347–353.
28. Cheng G, Torigian DA, Zhuang H, Alavi A. When should we recommend use of dual time-point and delayed time-point imaging techniques in FDG PET? Eur J Nucl Med Mol Imaging 2013;40(5):779–787.
29. Im HJ, Pak K, Cheon GJ, et al. Prognostic value of volumetric parameters of 18F-FDG PET in non-small-cell lung cancer: a meta-analysis. Eur J Nucl Med Mol Imaging 2015;42(2):241–251.
30. Pak K, Cheon GJ, Nam HY, et al. Prognostic value of metabolic tumor volume and total lesion glycolysis in head and neck cancer: a systematic review and meta-analysis. J Nucl Med 2014;55(6):884–890.
31. Liao S, Penney BC, Wroblewski K, et al. Prognostic value of metabolic tumor burden on 18F-FDG PET in nonsurgical patients with non-small cell lung cancer. Eur J Nucl Med Mol Imaging 2012;39(1):27–38.
32. Boellaard R, Delgado-Bolton R, Oyen WJ, et al. FDG PET/CT: EANM procedure guidelines for tumour imaging—version 2.0. Eur J Nucl Med Mol Imaging 2015;42(2):328–354.
33. Boellaard R. Standards for PET image acquisition and quantitative data analysis. J Nucl Med 2009;50(suppl 1):11S–20S.
34. Hickeson M, Yun M, Matthies A, et al. Use of a corrected standardized uptake value based on the lesion size on CT permits accurate characterization of lung nodules on FDG-PET. Eur J Nucl Med Mol Imaging 2002;29(12):1639–1647.
35. Fletcher JW, Kymes SM, Gould M, et al. A comparison of the diagnostic accuracy of 18F-FDG PET and CT in the characterization of solitary pulmonary nodules. J Nucl Med 2008;49(2):179–185.
36. Gierada DS, Pinsky P, Nath H, Chiles C, Duan F, Aberle DR. Projected outcomes using different nodule sizes to define a positive CT lung cancer screening examination. J Natl Cancer Inst 2014;106(11):dju284. http://jnci.oxfordjournals.org/content/106/11/dju284.long. Published October 17, 2014. Accessed February 5, 2015.
37. Chun EJ, Lee HJ, Kang WJ, et al. Differentiation between malignancy and inflammation in pulmonary ground-glass nodules: the feasibility of integrated 18F-FDG PET/CT. Lung Cancer 2009;65(2):180–186.
38. Al-Sarraf N, Gately K, Lucey J, et al. Clinical implication and prognostic significance of standardised uptake value of primary non-small cell lung cancer on positron emission tomography: analysis of 176 cases. Eur J Cardiothorac Surg 2008;34(4):892–897.

39. Basu S, Chen W, Tchou J, et al. Comparison of triple-negative and estrogen receptor-positive/progesterone receptor-positive/HER2-negative breast carcinoma using quantitative fluorine-18 fluorodeoxyglucose/positron emission tomography imaging parameters: a potentially useful method for disease characterization. Cancer 2008;112(5):995–1000.
40. Berghmans T, Dusart M, Paesmans M, et al. Primary tumor standardized uptake value (SUVmax) measured on fluorodeoxyglucose positron emission tomography (FDG-PET) is of prognostic value for survival in non-small cell lung cancer (NSCLC): a systematic review and meta-analysis (MA) by the European Lung Cancer Working Party for the IASLC Lung Cancer Staging Project. J Thorac Oncol 2008;3(1):6–12.
41. Buck A, Schirrmeister H, Kühn T, et al. FDG uptake in breast cancer: correlation with biological and clinical prognostic parameters. Eur J Nucl Med Mol Imaging 2002;29(10):1317–1323.
42. Cerfolio RJ, Bryant AS, Ohja B, Bartolucci AA. The maximum standardized uptake values on positron emission tomography of a non-small cell lung cancer predict stage, recurrence, and survival. J Thorac Cardiovasc Surg 2005;130(1):151–159.
43. Chung MK, Jeong HS, Park SG, et al. Metabolic tumor volume of [18F]-fluorodeoxyglucose positron emission tomography/computed tomography predicts short-term outcome to radiotherapy with or without chemotherapy in pharyngeal cancer. Clin Cancer Res 2009;15(18):5861–5868.
44. Groheux D, Giacchetti S, Moretti JL, et al. Correlation of high 18F-FDG uptake to clinical, pathological and biological prognostic factors in breast cancer. Eur J Nucl Med Mol Imaging 2011;38(3):426–435.
45. Xie P, Yue JB, Zhao HX, et al. Prognostic value of 18F-FDG PET-CT metabolic index for nasopharyngeal carcinoma. J Cancer Res Clin Oncol 2010;136(6):883–889.
46. Hillner BE, Siegel BA, Liu D, et al. Impact of positron emission tomography/computed tomography and positron emission tomography (PET) alone on expected management of patients with cancer: initial results from the National Oncologic PET Registry. J Clin Oncol 2008;26(13):2155–2161.
47. Ueda S, Tsuda H, Asakawa H, et al. Utility of 18F-fluorodeoxyglucose emission tomography/computed tomography fusion imaging (18F-FDG PET/CT) in combination with ultrasonography for axillary staging in primary breast cancer. BMC Cancer 2008;8:165. http://bmccancer.biomedcentral.com/articles/10.1186/1471-2407-8-165. Published June 8, 2008. Accessed February 5, 2015.
48. Billé A, Pelosi E, Skanjeti A, et al. Preoperative intrathoracic lymph node staging in patients with non-small-cell lung cancer: accuracy of integrated positron emission tomography and computed tomography. Eur J Cardiothorac Surg 2009;36(3):440–445.
49. Wahl RL, Siegel BA, Coleman RE, Gatsonis CG; PET Study Group. Prospective multicenter study of axillary nodal staging by positron emission tomography in breast cancer: a report of the Staging Breast Cancer with PET Study Group. J Clin Oncol 2004;22(2):277–285.
50. Bryant AS, Cerfolio RJ, Klemm KM, Ojha B. Maximum standard uptake value of mediastinal lymph nodes on integrated FDG-PET-CT predicts pathology in patients with non-small cell lung cancer. Ann Thorac Surg 2006;82(2):417–422; discussion 422–423.
51. Lee BE, Redwine J, Foster C, et al. Mediastinoscopy might not be necessary in patients with non-small cell lung cancer with mediastinal lymph nodes having a maximum standardized uptake value of less than 5.3. J Thorac Cardiovasc Surg 2008;135(3):615–619.
52. Van den Abbeele AD. The lessons of GIST: PET and PET/CT—a new paradigm for imaging. Oncologist 2008;13(suppl 2):8–13.
53. Cheson BD, Pfistner B, Juweid ME, et al. Revised response criteria for malignant lymphoma. J Clin Oncol 2007;25(5):579–586.
54. Cheson BD, Horning SJ, Coiffier B, et al; NCI Sponsored International Working Group. Report of an international workshop to standardize response criteria for non-Hodgkin's lymphomas. J Clin Oncol 1999;17(4):1244.
55. Juweid ME, Stroobants S, Hoekstra OS, et al. Use of positron emission tomography for response assessment of lymphoma: consensus of the Imaging Subcommittee of International Harmonization Project in Lymphoma. J Clin Oncol 2007;25(5):571–578.
56. Leal J, Wahl R. SUL-PEAK, -MAX and -PAX in PERCIST 1.0: an ROC analysis [abstr]. J Nucl Med 2012;53(suppl 1):1223. http://jnumedmtg.snmjournals.org/cgi/content/meeting_abstract/53/1_MeetingAbstracts/1223. Published May 2012. Accessed February 5, 2015.