

# Translabial US and Dynamic MR Imaging of the Pelvic Floor: Normal Anatomy and Dysfunction<sup>1</sup>

Luciana P. Chamié, MD, PhD  
Duarte Miguel Ferreira Rodrigues  
Ribeiro, MD

Angela H. M. Caiado, MD  
Gisele Warmbrand, MD, PhD  
Paulo C. Serafini, MD, PhD

**Abbreviations:** DPS = descending perineal syndrome, FIESTA = fast imaging employing steady-state acquisition, PCL = pubococcygeal line, PFD = pelvic floor dysfunction, POP = pelvic organ prolapse, 2D = two dimensional, 3D = three dimensional, 4D = four dimensional

**RadioGraphics** 2018; 38:287–308

<https://doi.org/10.1148/rg.2018170055>

**Content Codes:**    

<sup>1</sup>From the Department of Diagnostic Imaging, Chamié Imagem da Mulher, Rua Casa do Ator, 1117, cj 72, São Paulo, SP 04546-004, Brazil (L.P.C.); Department of Diagnostic Imaging, Fleury Medicina e Saúde, São Paulo, Brazil (L.P.C., A.H.M.C., G.W.); Department of Female Reconstructive Surgery, Clínica Dr Duarte Miguel Ferreira Rodrigues Ribeiro, São Paulo, Brazil (D.M.F.R.R.); and Instituto de Radiologia-INRAD (A.H.M.C.) and Department of Gynecology (P.C.S.), Faculdade de Medicina da Universidade de São Paulo, São Paulo, Brazil. Presented as an education exhibit at the 2016 RSNA Annual Meeting. Received March 13, 2017; revision requested June 13 and received July 14; accepted July 27. For this journal-based SA-CME activity, the authors, editor, and reviewers have disclosed no relevant relationships. Address correspondence to L.P.C. (e-mail: [luciana@chamie.com.br](mailto:luciana@chamie.com.br)).

©RSNA, 2018

## SA-CME LEARNING OBJECTIVES

After completing this journal-based SA-CME activity, participants will be able to:

- Identify the most important anatomic structures that form the pelvic floor.
- Discuss the roles of translabial US and dynamic MR imaging in the evaluation of PFD and their strengths and limitations in the assessment of individual pathologic entities.
- Identify the most common pathologic conditions in the three pelvic compartments and the typical US and MR imaging findings of these entities.

See [www.rsna.org/education/search/RG](http://www.rsna.org/education/search/RG).

Pelvic floor dysfunction (PFD) is a common condition that typically affects women older than 50 years and decreases the quality of life. Weakening of support structures can involve all three pelvic compartments and cause a combination of symptoms, including constipation, urinary and fecal incontinence, obstructed defecation, pelvic pain, perineal bulging, and sexual dysfunction. The causes of PFD are complex and multifactorial; however, vaginal delivery is considered a major predisposing factor. Physical examination alone is limited in the evaluation of PFD; it frequently leads to an underestimation of the involved compartments. Imaging has an important role in the clinical evaluation, yielding invaluable information for patient counseling and surgical planning. Three- and four-dimensional translabial ultrasonography (US) is a relatively new imaging modality with high accuracy in the evaluation of PFD such as urinary incontinence, pelvic organ prolapse, and puborectalis avulsion. Evaluation of mesh implants is another important indication for this modality. Dynamic magnetic resonance (MR) imaging of the pelvic floor is a well-established modality for pelvic floor evaluation, with high-resolution images yielding detailed anatomic information and dynamic sequences yielding functional data. Specific protocols and dedicated image interpretation are required with both of these imaging methods. In this article, the authors review the normal anatomy of the female pelvic floor by using a practical approach, discuss the roles of translabial US and MR imaging in the investigation of PFD, describe the most appropriate imaging protocols, and illustrate the most common imaging findings of PFD in the anterior, middle, and posterior compartments of the pelvis.

*Online supplemental material is available for this article.*

©RSNA, 2018 • [radiographics.rsna.org](http://radiographics.rsna.org)

## Introduction

*Pelvic floor dysfunction* (PFD) is an umbrella term used to describe pelvic function disorders, which include pelvic organ prolapse (POP), urinary incontinence, fecal incontinence, and descending perineal syndrome (DPS). PFD affects approximately 50% of women older than 50 years worldwide. In one study involving women with PFD (1), the estimated lifetime risk of undergoing a single surgical intervention for PFD was 11.1%, and two or more surgical procedures were required in 30% of cases. In the United States, PFD affects approximately 23.7% of women, and approximately 225 000 of women undergo inpatient surgery for POP each year (2,3). With increasing life expectancies, the negative effect of PFD on the health care system in terms of cost, productivity, and quality of life is critical. Thus, primary attention and the development of appropriate prevention strategies are required.

## TEACHING POINTS

- *Pelvic floor dysfunction* (PFD) is an umbrella term used to describe pelvic function disorders, which include pelvic organ prolapse (POP), urinary incontinence, fecal incontinence, and descending perineal syndrome (DPS).
- The pathologic findings of PFD generally involve the three pelvic compartments. They affect the interrelated network of muscles, ligaments, and connective tissue and result in structural damage and dysfunction.
- The levator ani and coccygeus muscles form the muscular floor of the pelvis, which is also known as the pelvic diaphragm. The levator ani is composed of two major muscles from the medial to lateral aspects: the pubococcygeus muscle and the ileococcygeus muscle.
- Since the advent of MR imaging, the superior anatomic resolution achieved with this modality has led to its emergence as a valuable imaging tool for evaluating the female pelvis, with the levator ani depicted for the first time.
- Translabial US is the best imaging modality for identifying and locating mesh implants and evaluating their functionality.

The causes of PFD are multifactorial and are related to the weakening and/or ineffectiveness of support structures. Risk factors include vaginal delivery, multiparity, hysterectomy, advanced age, connective tissue disorders, obesity, hypoes-trogenism, chronic pulmonary disorders, and conditions associated with increased abdominal pressure (4). The greatest associated risk factors are advanced age and vaginal parity.

PFD is associated with a wide spectrum of symptoms, which are based on the affected compartment(s) and include chronic pelvic pain, urinary and fecal incontinence, constipation, perineal bulging, painful intercourse, and abnormal rectal emptying (5). Women with advanced POP may have a diminished self-image and quality of life and often have various combinations of symptoms owing to multicompartmental involvement (6).

The clinical evaluation of PFD mainly involves physical examination performed by using the POP quantification system proposed by the International Continence Society in 1996 (7). With this system, POP is graded by using the vaginal hymen as a reference line during the Valsalva maneuver. Although this system has been widely adopted, it has demonstrated low sensitivity and specificity for the diagnosis of complex alterations, with frequent underestimation of the affected compartments and associated surgical failure and high recurrence rates (8).

The pathologic findings of PFD generally involve the three pelvic compartments. They affect the interrelated network of muscles, ligaments, and connective tissue and result in structural damage and dysfunction. The success of reconstructive

pelvic surgery depends on the overall restoration of form and function (9,10). Within this framework, imaging mapping can be used to accurately determine the location and extent of pelvic injuries for clinical counseling and surgical planning.

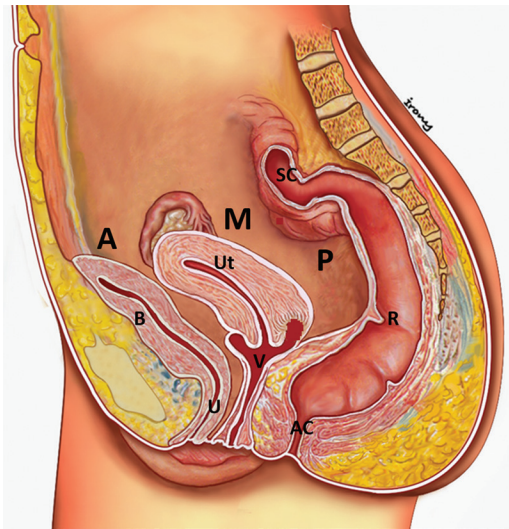
During the past decade, three-dimensional (3D) and four-dimensional (4D) translabial ultrasonography (US) and magnetic resonance (MR) imaging have been used to accurately assess pelvic floor anatomy and function, enabling evaluation of all three pelvic compartments simultaneously (11,12). The information acquired with these imaging examinations can be used to substantially change the clinical scenarios associated with treatment failure and early recurrence of symptoms.

In this article, we review the normal anatomy of the female pelvic floor by using a practical and comprehensive approach and discuss the roles of translabial US and MR imaging in the investigation of PFD. This review includes a description of the most appropriate imaging protocols and a critical analysis of the advantages and limitations of these methods. In addition, the most common imaging findings of PFD in the anterior, middle, and posterior compartments of the pelvis are described and illustrated, and the static and dynamic sequences that yield better diagnostic results are reviewed.

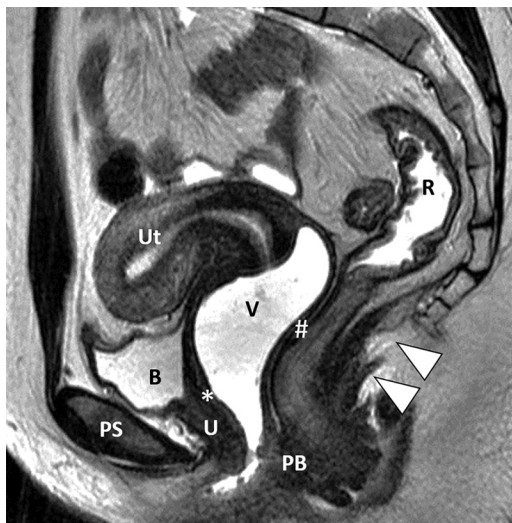## Pelvic Floor Anatomy

Appropriate management of PFD depends on the clinician's thorough knowledge of the underlying pathophysiologic mechanisms of the disease. Understanding the relationship between the structure and function of the female pelvic floor is the key to correctly interpreting imaging findings and guiding treatment decisions.

The pelvic floor comprises three compartments: the anterior compartment, which contains the bladder and urethra; the middle compartment, which contains the uterus and vagina; and the posterior compartment, which contains the anal canal, rectum, and sigmoid colon (Fig 1) (13,14). The support structures of the pelvic floor consist of a complex interaction among the bones, muscles, ligaments, and organs. The ligaments, muscle, and fascia constitute a musculoelastic system that gives form and function to the organs. The pelvic organs, including the urethra, vagina, and rectum, have no inherent shape or strength. The role of the fascia is to strengthen and support the organs, and the role of the ligaments is to suspend the organs and act as anchoring points for the muscles. The muscle forces stretch the organs, contributing to their shape, form, and strength. The support structures form three layers from the superior to inferior



**Figure 1.** Schematic illustration of the midsagittal view of the female pelvic cavity demonstrates the three pelvic compartments. The anterior compartment (A) contains the bladder (B) and urethra (U). The middle compartment (M) contains the uterus (Ut) and vagina (V). The posterior compartment (P) contains the anal canal (AC), rectum (R), and sigmoid colon (SC). (Adapted, with permission, from reference 13.)



**Figure 2.** Normal female pelvic floor anatomy. Sagittal T2-weighted MR image shows the pubocervical fascia (\*) and the rectovaginal septum (S). The levator plate (arrowheads) at rest follows the vaginal and anorectal angulation and the perineal body (PB) in the anovaginal septum. B = bladder, PS = pubic symphysis, R = rectum, U = urethra, Ut = uterus, V = vagina.

aspects: the endopelvic fascia, pelvic diaphragm, and urogenital diaphragm (Movies 1, 2).

### Endopelvic Fascia and Connective Tissue Support Structures

The endopelvic fascia is a sheet that covers the pelvic organs and levator ani muscles continuously. It is a meshlike group of collagen fibers interlaced with elastin, smooth muscle cells, fi-

broblasts, and vascular structures. The endopelvic fascia lies immediately beneath the peritoneum and is one continuous unit with various condensations in specific areas. It is continuous with the visceral fascia, which provides a capsule containing the organs and allows displacements and changes in volume (15). The distinct regions of these structures—specifically, the ligaments and fascia—are given individual names.

**Anterior Support Structures.**—In the anterior compartment, the endopelvic fascia supports the urethra, bladder, vagina, and uterus. The portion that extends from the symphysis pubis to the anterior vaginal wall to blend with the fascia that surrounds the cervix is known as the pubocervical fascia (Fig 2). Here, the support comes from the lateral attachment of the vagina to the arcus tendineus of the pelvic fascia. The anterior vaginal wall also supports the urethra by way of its lateral attachment to the pubococcygeus muscle of the levator ani. The ligaments of the anterior vaginal wall provide hammock-like support to the vesical neck and urethra and have a fundamental role in maintaining urinary continence in women (16). The urethral ligaments are urethra-supporting structures that extend from the urethra to the pubic bone and include three groups: periurethral ligaments arising from the puborectalis muscle, ventral to the urethra; paraurethral ligaments, which arise from the lateral wall of the urethra and extend to the periurethral ligaments; and pubourethral ligaments, which extend from the pelvic bone to the ventral aspect of the urethra (17,18). Consequently, damage to the pubocervical fascia or periurethral ligaments can lead to urethral hypermobility, a cystocele, or urinary incontinence.

**Middle Support Structures.**—In the middle compartment, the condensations of the endopelvic fascia are known as the paracolpium and parametrium, which are the connective tissues surrounding the vagina and uterus, respectively. In the middle region of the vagina, the paracolpium fuses with the pelvic wall and fascia laterally. The cardinal ligaments, also known as the transverse cervical ligaments of Mackenrodt, are condensations of the lowermost part of the broad ligaments. Medially, the cardinal ligaments are continuous with the paracolpium and parametrium, as well as with the pubocervical fascia. The uterosacral ligaments are attached to the cervix and posterior vaginal fornices posterolaterally. They are continuous with the connective tissue of the cardinal ligaments. The uterosacral and cardinal ligaments simultaneously hold the uterus and upper vagina in their proper places over the levator plate, preventing genital organ prolapse (19).

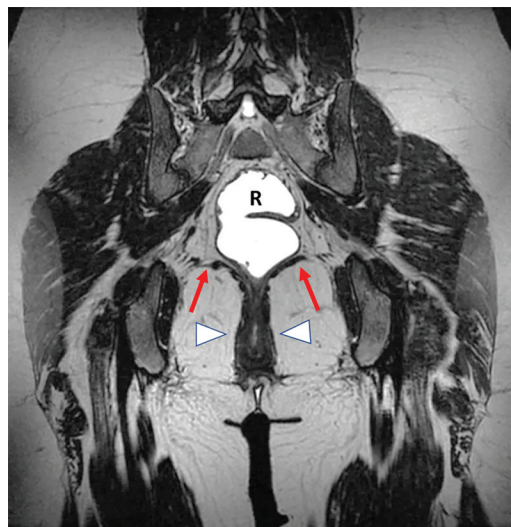


**Posterior Support Structures.**—The posterior vaginal wall is supported from the sides by the paracolpium and pelvic diaphragm. In this area, the paracolpium is called the rectovaginal septum, which extends from the posterior vaginal wall to the anterior wall of the rectum (Fig 2). The intact rectovaginal septum permits independent mobility of the rectal and vaginal walls. Another important anchoring structure for the muscles and ligaments is the perineal body, or the so-called anchor of the pelvis, which lies within the anovaginal septum and is bound by the vagina anteriorly and the anterior anal wall posteriorly (Fig 2). It is a solid pyramidal fibromuscular mass fused with the inferior third of the posterior vaginal wall, without any intervening fascia (20). The lateral rectal ligaments, which are the fascial supports for the rectum, extend from the posterolateral pelvic sidewall to the rectum and surround the middle rectal arteries (15). A tear in the rectovaginal fascia can lead to an anterior rectocele, enterocele, and/or peritoneocele.

### Muscular Support Structures and Pelvic Diaphragm

The levator ani and coccygeus muscles form the muscular floor of the pelvis, which is also known as the pelvic diaphragm. The levator ani is composed of two major muscles from the medial to lateral aspects: the pubococcygeus muscle and the ileococcygeus muscle (Fig 3). The bulkier medial portion is the pubococcygeus muscle, which arises from the posterior border of the pubis and the anterior portion of the arcus tendineus. This muscle runs back horizontally to behind the rectum. The inner border is a margin of the urogenital hiatus, which includes the urethra, vagina, and anorectum. The medial portions of the pubococcygeus muscle have been subdivided into various parts, including the pubourethralis, pubovaginalis, puboanalis, and puborectalis muscles, to reflect the attachments of the muscle. Collectively, these portions are referred to as the pubovisceralis muscle (Fig 4) (15,21). The levator ani provides tone to the pelvic floor, maintaining pelvic organs in their proper position.

The thin lateral part of the levator ani is the ileococcygeus muscle, which arises from the arcus tendineus of the levator ani to the ischial spine. The fibers from both sides fuse posteriorly in the midline to form a condensation raphe called the levator plate (Fig 2). When a woman is in a standing position, the levator plate is horizontal and supports the rectum and the upper two-thirds of the vagina above it. Levator ani weakness may lead to loosening of the sling, changing the configuration of the levator plate to a vertical position and predisposing the woman to POP.



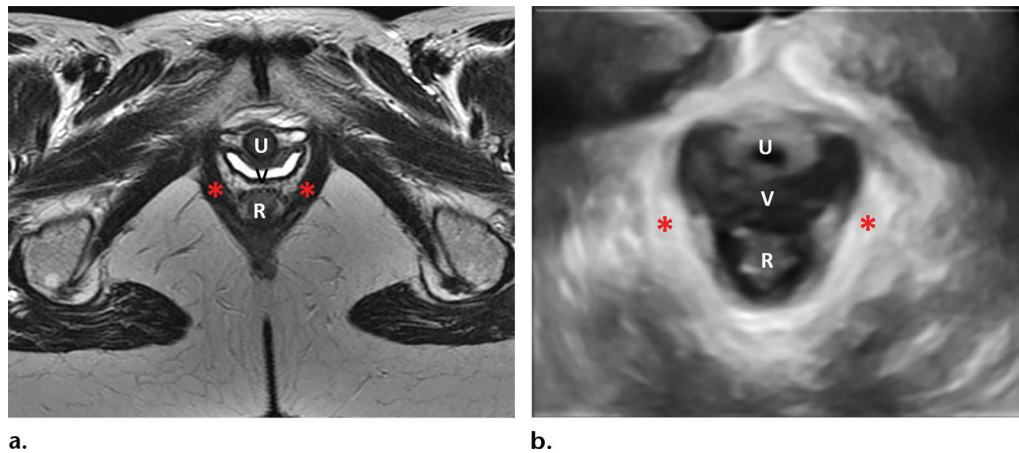
**Figure 3.** Normal female pelvic floor anatomy. Coronal T2-weighted MR image shows the normal aspect of the levator ani muscle. The horizontal configuration of the ileococcygeus muscle (arrows) and pubococcygeus muscle (arrowheads) is seen. R = rectum.

### Urogenital Diaphragm (Perineal Membrane)

The urogenital diaphragm is a musculofascial structure located below the pelvic diaphragm and anterior to the anorectum. It comprises the deep transverse muscle of the perineum and connective tissue. This structure serves as a bridge between the inferior pubic rami and the perineal body and provides structural support to the distal urethra and vagina. The posterior triangle around the anus does not have a corresponding diaphragm or membrane (22).

### Vagina

The vagina is a tubular structure centrally located in the middle compartment of the pelvis; its oblique orientation has a fundamental role in maintaining the integrity of the pelvic floor. The vagina is essentially an elastic membrane. The vaginal walls are composed of smooth muscle and connective tissue, and because the vagina lacks an inherent shape, synergic interaction among the ligaments, fascia, and connective tissue is necessary to maintain its form and adequate function. According to DeLancey (23,24), vaginal support is provided at three levels: level I, the uterosacral-cardinal complex; level II, the arcus tendineus fascia pelvis; and level III, the perineal membrane and arcus tendineus levator ani. Support to the uterus and upper vagina is provided by the uterosacral and cardinal ligaments that are attached to the cervical ring. All fascial and ligamentous structures insert directly or indirectly into the cervical ring, which consists mainly of collagen. The middle region of



**Figure 4.** Normal female pelvic floor anatomy. Axial T2-weighted MR image (a) and axial 3D translabial US image (b) show the pelvic hiatus. The puborectalis muscles (\*) form a sling that surrounds the urethra (U), vagina (V), and rectum (R). Note the typical butterfly shape of the vagina.

the vagina is supported by the attachment of the vaginal muscularis to the arcus tendineus fascia pelvis. It is suspended like a trampoline between the two arcus tendineus fasciae pelvis by lateral fascial extensions. This “hammock” lies beneath the urethra and is a crucial component of urinary continence. Support to the inferior region of the vagina is provided by the rectovaginal fascia, the perineal membrane, and the vaginal attachment to the levator ani (23).

### Anal Sphincter

The anal sphincter is composed of a smooth-muscle internal sphincter and an external sphincter complex of skeletal muscle. The internal sphincter is a continuation of the circular muscle layer of the rectum. It promotes a continuous tone and thus is responsible for involuntary anal continence. The longitudinal layer continues as an intersphincteric plane between the internal and external sphincters (24). It extends from the anorectal junction to approximately 1.0–1.5 cm below the dentate line and has autonomous innervations from sympathetic presacral nerves. The external sphincter complex comprises the inferior part of the levator ani, the puborectalis muscle, and the external sphincter muscles. The puborectalis muscle suspends the rectum at the anorectal junction, with a slinglike configuration around the anal canal and rectum. This muscle functions under voluntary control and is innervated by the pudendal nerves. It produces a continuous tone, contributing 10%–15% of the tension with resting pressure, and it voluntarily relaxes during defecation. The external sphincter complex comprises several parallel bundles and extends 1.0 cm beyond the internal sphincter. The epithelial lining of the distal part of the anal canal is stratified squamous epithelium, with a rich sup-

ply of sensory receptors that are mainly concentrated at the dentate line. This line demarcates the junction with the columnar epithelium (25).

### Diagnostic Imaging

Imaging assessment of the pelvic floor historically has been performed with use of a single examination or a combination of conventional radiologic techniques such as voiding cystourethrography, video defecography, and US of the bladder neck and anal sphincter. Since the advent of MR imaging, the superior anatomic resolution achieved with this modality has led to its emergence as a valuable imaging tool for evaluating the female pelvis, with the levator ani depicted for the first time. Later, the first applications of MR imaging for dynamic examination of the pelvic floor prompted a renewed interest in using this modality to evaluate PFD (26). Subsequently, with upgraded machines, MR imaging has proven to be useful for not only the diagnosis of anatomic changes and structural damage associated with different pathologic conditions but also the functional analysis of the three pelvic compartments in real time. Dynamic examination enables simulation of the clinical conditions associated with POP, urinary incontinence, fecal incontinence, and DPS and can be performed with the patient at rest, squeezing, performing the Valsalva maneuver, and defecating (27,28).

With the development of 3D and 4D US technologies, 3D and 4D translabial US recently has been used as an alternative imaging method, with some advantages over other modalities, including absence of ionizing radiation, cost-effectiveness, greater availability, and minimal discomfort (12). A potential new application for US is that of obtaining images of the pelvic hiatus in the axial plane, as is possible with MR imaging. Nevertheless,

knowledge of and experience with pelvic floor US is not widespread among radiologists; rather, it is still confined to clinicians in very specific subspecialties, such as urologists, gynecologists, and colorectal surgeons (11).

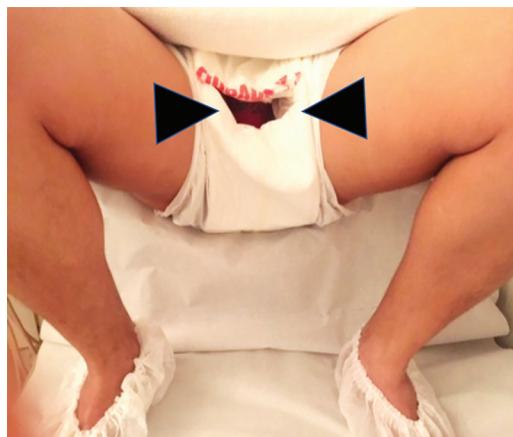Routine examination and counseling of patients with PFD include physical examination and urodynamic testing. However, relevant data have shown that for complex cases involving moderate to severe symptoms, this approach has poor sensitivity and specificity for the diagnosis of all conditions involved, with early recurrence of symptoms in up to 32% of cases (29,30). In addition, the information acquired by using imaging techniques can lead to a complete change in the surgical strategy and required multidisciplinary team in up to 67% of cases (28).

Before step-by-step descriptions of the algorithms for each modality are provided, one step that is crucial to achieving the best imaging performance should be emphasized: that of performing the dynamic maneuvers properly. Because this can be challenging for patients, adequate instruction is fundamental to avoid misinterpretation of findings and acquisition of false-negative results. Moreover, a good patient-physician rapport aids in minimizing the embarrassment that patients usually feel while undergoing pelvic floor examinations. More than 50% of all women reportedly do not perform the proper pelvic floor contraction when asked to, and Valsalva maneuvers are often performed with concomitant levator muscle coactivation (31).

### Translabial US of the Pelvic Floor

**Patient Preparation.**—Patient preparation is simple and includes minimal bowel cleaning. Fecal content and gas impair the diagnostic accuracy of US examinations. The patient is required to empty the rectum by using one simple rectal enema up to 1 hour before the examination. In addition, bladder voiding is required before the beginning of the examination. An adult diaper with a frontal opening can be worn to protect the patient from any leaked material during the US examination and thus minimize embarrassment (Fig 5).

**Patient Examination.**—Translabial US is performed with the patient in the dorsal lithotomy position, with the hips flexed and abducted, or sometimes with her in a standing position. The latter position may be necessary to improve the Valsalva maneuver in patients who have difficulty performing effective maneuvers. A 3D convex volumetric transabdominal transducer is placed on the perineum, between the labia majora, with the smallest amount of pressure



**Figure 5.** Photograph shows a patient in the dorsal lithotomy position, with the hips flexed and abducted. An adult diaper with a frontal opening (arrowheads) allows placement of the transducer and protects the patient from leaked urine and/or fecal material.

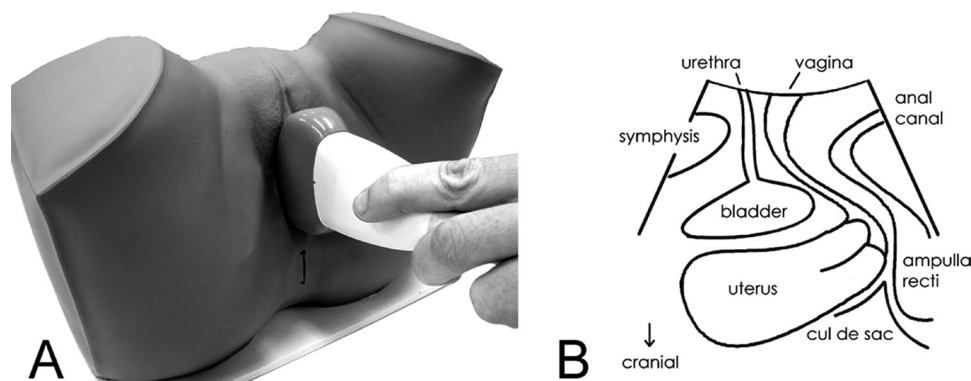
applied to enable full pelvic organ descent (Fig 6) (32). Manual parting of the labia before transducer placement is sometimes necessary, especially if they are hypertrophic. For proper hygiene, the transducer is covered with a thin plastic wrap or powder-free glove (Fig 7). With these transducers, an electronic curved array of 4–8 MHz combined with mechanical sector technology enables the creation of acquisition angles of up to 85°. This facilitates fast motorized sweeps through the field of view, including the levator hiatus in its entirety. Three-dimensional data are collected in a cine loop to form a volume dataset. An advantage of this technique is the capability to obtain volumes that can be postprocessed in different orthogonal planes and perform multisection imaging to assess the dynamic maneuvers and puborectalis integrity.

Four-dimensional imaging involves the real-time acquisition of rendered volumes or volumes in orthogonal planes. Analyses can be performed by using the US machine or a personal computer with use of dedicated software.

**Imaging Data Interpretation.**—The translabial US algorithm is divided into two steps: In step 1, images are obtained with the pelvis at rest (Fig 8), and a 2D midsagittal image of the pelvis is obtained to assess the residual bladder volume (RBV), bladder wall thickness, urethra, bladder neck mobility, and funneling.

The RBV can be determined at translabial US. After a mild Valsalva maneuver, the two largest diameters ( $x$  and  $y$ ) are measured perpendicular to each other, and the resultant measurement, in centimeters, is multiplied by 5.9. Subtracting 14.9 from the resultant product yields the RBV:  $[(x \cdot y) \cdot 5.9] - 14.9 = \text{RBV}$  (33).





**Figure 6.** A, Model demonstrates transducer placement. B, Schematic diagram illustrates the resulting midsagittal view at two-dimensional (2D) transperineal US. (Reprinted, with permission, from reference 32.)



**Figure 7.** Photograph shows the volumetric convex transducer covered with a thin plastic wrap for proper hygiene.

After the bladder is emptied, the bladder wall thickness can be assessed with translabial US and measured at the bladder dome. Although a hypertrophic wall is not a specific marker for detrusor overactivity, it may be a helpful finding when combined with clinical symptoms (34).

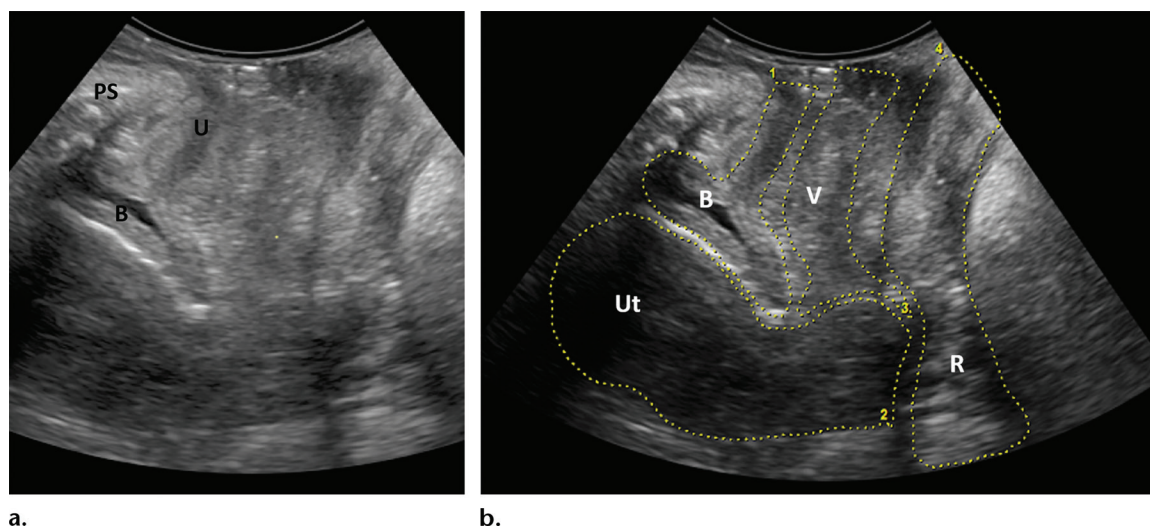
Bladder neck mobility can be assessed by calculating the difference between the distance from the bladder base to the inferoposterior margin of the symphysis pubis during rest and this distance during a maximal Valsalva maneuver (Movie 3). This difference yields a numeric value of the bladder neck descent. Although there is no standard definition of the cutoff value for bladder neck descent, cutoff values of 15, 20, and 25 mm have been

proposed. The mean cutoff value for women with urinary incontinence is approximately 30 mm (35).

Evaluation of the urethra includes dimension measurements and assessment of occasionally seen abnormalities, such as diverticula and dilated glands. Funneling is an indirect and nonspecific sign of urinary incontinence, but it can be seen in asymptomatic women. It may be associated with urine leakage.

In step 2, US images are obtained during the dynamic phase by using the plane of minimal dimensions (Fig 9). This plane represents the region of interest and is defined as the shortest line between the posterior surface of the symphysis pubis and the levator muscle behind the anorectal angle, with 2.5-mm intervals recorded from 5 mm below this plane to 12.5 mm above it. Three-dimensional volumes are obtained and stored in cine loop and video modes during rest, contraction, and a maximal Valsalva maneuver. In the multiplanar display mode, cross-sectional views through the obtained volume are seen in the midsagittal (top left), coronal (top right), and axial (bottom left) planes for each maneuver. The three orthogonal planes are complemented by a volume-rendered semitransparent image, with a caudal to cranial orientation (Fig 10). The plane of minimal dimensions is determined to measure the hiatal area and assess POP, the anal sphincter, levator ani muscle integrity, avulsion defects, and mesh implants.

Hiatal dimensions can be traced in a single axial plane or in a rendered volume during all phases—but ideally during the Valsalva maneuver (Fig 11). Hiatal biometry has high reproducibility with use of this method and when measurements of less than 25 mm<sup>2</sup> at Valsalva maneuvering are unlikely to be associated with POP. Translabial US has a distinct advantage over MR imaging for imaging in the oblique plane to calculate hiatal dimensions with acquisition angles greater than 70°, which

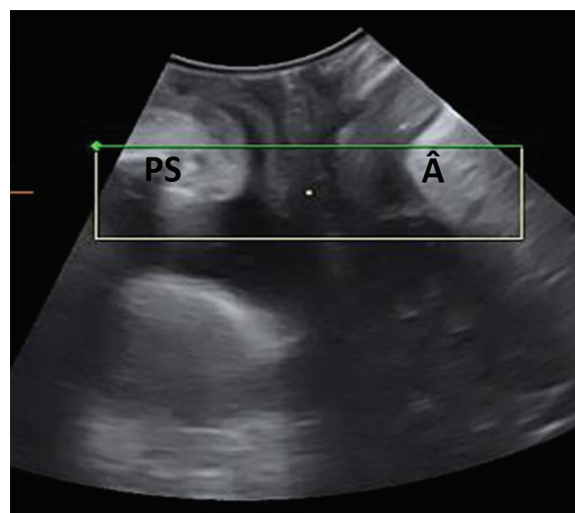


**Figure 8.** Two-dimensional US of the female pelvis at rest. (a) Midsagittal translabial image of the pelvis shows the normal aspects of the urethra (U), bladder (B) neck, and pubic symphysis (PS). (b) Dotted lines drawn on the same image outline the bladder (B, 1), uterus (Ut, 2), vagina (V, 3), and rectum (R, 4).

encompass the entire levator hiatus and surrounding muscles (ie, pubococcygeous and puborectalis muscles). The extent of ballooning, defined as excessive distention of the hiatus, is categorized as mild ( $25.0\text{--}29.9\text{ cm}^2$ ), moderate ( $30.0\text{--}34.9\text{ cm}^2$ ), marked ( $35.0\text{--}39.9\text{ cm}^2$ ), or severe ( $\geq 40\text{ cm}^2$ ) (36).

Tomographic US can be performed after the volume acquisition to process imaging information into a predetermined number of sections with predetermined spacing, similar to the data processing involved in other multiplanar methods such as computed tomography and MR imaging. With tomographic US, coronal images are used for reference and are obtained during the contraction phase on the basis of the plane of minimal dimensions, with eight parallel 2.5-mm-thick sections (Fig 12). The main application for translabial US is evaluation of the levator ani muscle integrity and avulsion defects. The most common morphologic abnormality of the levator ani is right-side avulsion of the pubovisceral muscle off the pelvic sidewall; this condition is clearly related to childbirth (37). There is a good correlation between 3D translabial US and MR imaging of the puborectalis complex for dimension and thickness measurements (36,38).

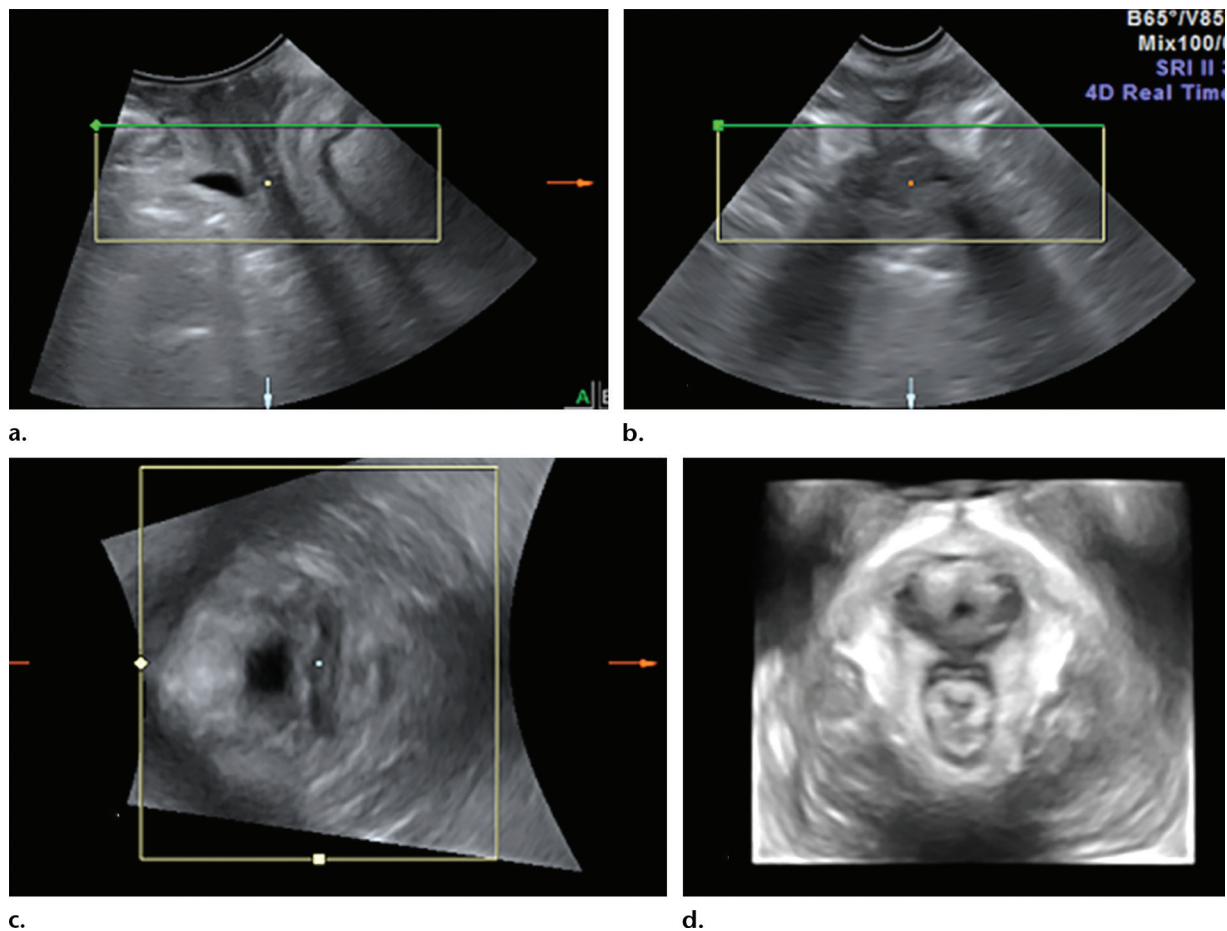
POP can be evaluated and quantified with translabial US in all three pelvic compartments. The inferior margin of the symphysis pubis is used as a landmark against which the maximal descents of the bladder, uterus, cul-de-sac, and rectal ampulla at Valsalva maneuvering can be measured (Fig 13). The bladder neck or the leading edge of a cystocele is used for quantification of anterior vaginal descent; the cervix or the pouch of Douglas, for quantification of central compartment descent; and the most caudal aspect of the rectal ampulla or the



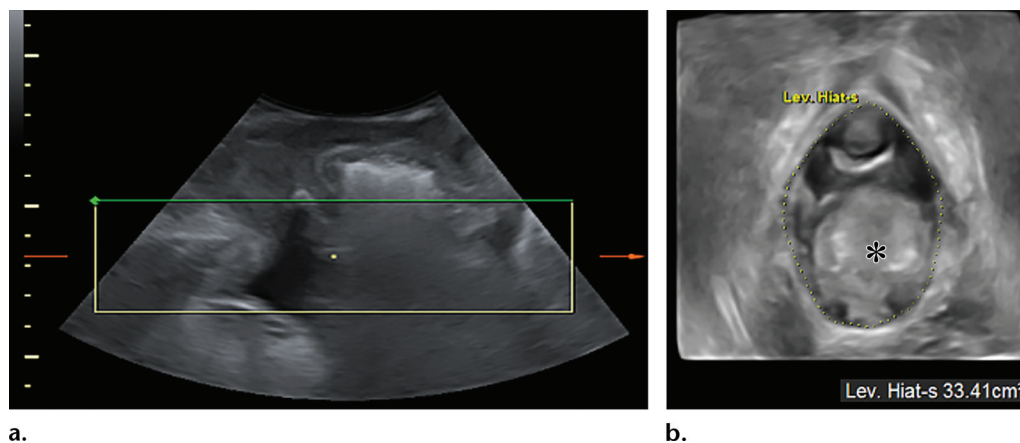
**Figure 9.** Determining the plane of minimal hiatal dimensions, which is a reference plane for assessing the puborectalis muscle. Midsagittal translabial US image of the female pelvis shows the space between the pubic symphysis (PS) and the levator ani posterior to the anorectal angle (A).

top border of rectocele contents, for quantification of posterior compartment descent. US quantification of anterior and central compartment prolapse has been shown to have a good correlation with clinical prolapse assessment performed by using the POP quantification system (39). In the posterior compartment, the correlation is not as strong; a descent of 15 mm below the reference line has been proposed as a cutoff value for substantial clinical prolapse. Four-dimensional US facilitates real-time acquisition, which is very important in pelvic floor evaluations because it enables the visualization of morphologic and functional changes during maneuvers such as levator contraction and Valsalva maneuvers. This advantage possibly makes





**Figure 10.** (a–c) Sagittal (a), coronal (b), and axial (c) US images depict the female pelvic floor. The rectangles represent the volume of images obtained in each plane. (d) The 3D volume-rendered US image is a semitransparent representation of all of the gray-scale data in the rendered volume, with a caudal to cranial orientation.

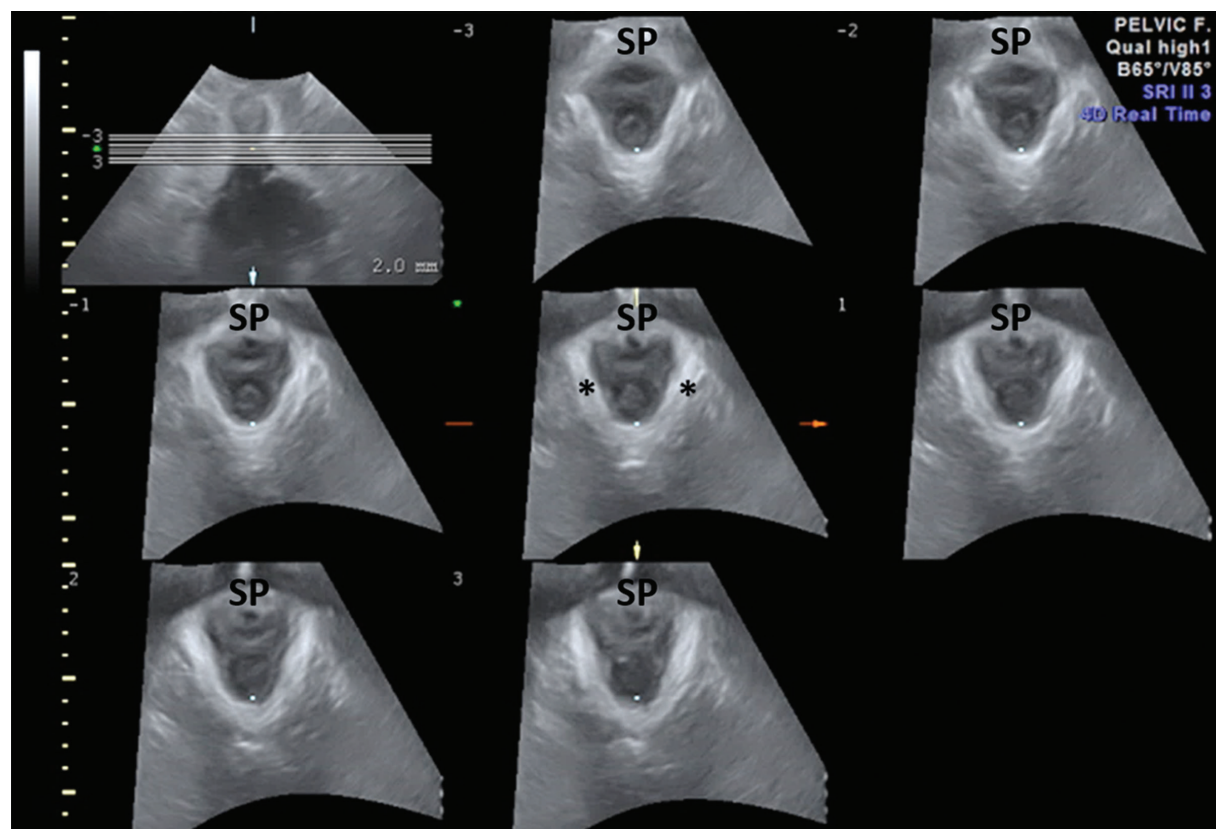


**Figure 11.** Measurement of hiatal circumference. Two-dimensional midsagittal translabial US image obtained during the Valsalva maneuver (a) and simultaneously obtained axial 3D volume-rendered translabial US image (b). The hiatal area is measured by bordering the inner limits of the puborectalis muscle. An area of less than 25 cm<sup>2</sup> at Valsalva maneuvering is unlikely to be associated with substantial prolapse. Note the ballooning of the levator hiatus (*Lev. Hiatus*) (hiatal area, 33.4 cm<sup>2</sup>) and the rectocele (\*) in b.

the 4D US technique superior to MR imaging, with which very fast acquisition without optimal spatial resolution is required. Furthermore, owing to the characteristics of MR imaging systems, there is limited control of common confounders such

as concomitant levator contraction during the Valsalva maneuver.

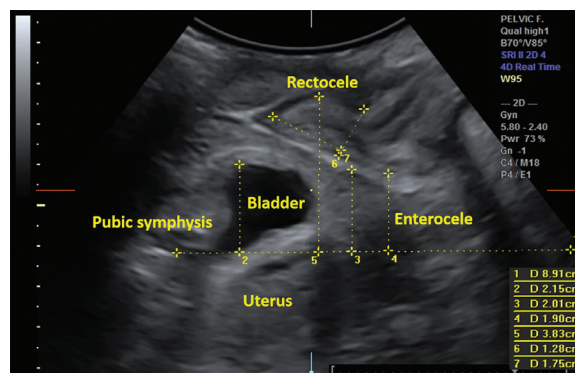
Although endoanal US performed with a high-resolution probe is considered the reference standard for sphincter evaluation, the use



**Figure 12.** Tomographic translabial US images of the normal puborectalis muscle (\*). Multiple sections of a volume were obtained during muscle contraction, in 2.5-mm section intervals. SP = symphysis pubis.

of high-frequency curved-array or transvaginal probes placed exoanally in the coronal plane has been accepted for anal sphincter evaluation at rest and during contraction. The normal mucosa is visualized as a hyperechoic area surrounded by a hypoechoic ring that represents the internal anal sphincter. The more external hyperechoic tissue represents the external anal sphincter (Fig 14) (40,41). Anal injuries occur more frequently than they are reported and can be related to the use of vaginal instrumentation during childbirth. They appear as a discontinuity of the rings of the internal and external anal sphincters (42). The clock face is used to report the locations of these injuries.

Assessment of mesh implants is one of the most important applications of translabial US, as these implants are very difficult to detect with other methods such as MR imaging and conventional radiography. Three-dimensional US can depict the implant over its entire intrapelvic course, from the pubic rami to behind the urethra, and can be used to distinguish the different varieties of these entities. These implants can appear as hyperechogenic tape strips in the midurethral region. Urethral implants have been widely used to treat urinary incontinence and can be associated with complications such as recurrent urinary incontinence, urinary retention,

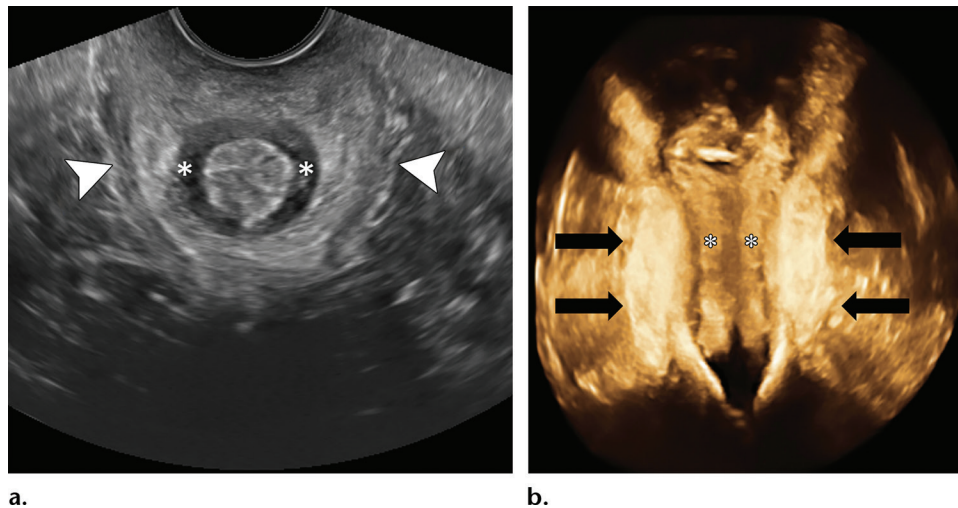


**Figure 13.** Prolapse quantification at translabial US. The horizontal line of reference is positioned through the inferior margin of the pubic symphysis. The vertical lines indicate the maximal descents of the bladder, uterus, and anorectal junction, and the top borders of a rectocele and an enterocele. In addition, the rectocele depth can be measured by using a line spanning the cranioventral aspect of the internal anal sphincter as a baseline from which the maximal depth is measured.

and erosion. Imaging—3D volume-rendered examinations in particular—has an important role in pre- and postoperative evaluations (43).

### Dynamic MR Imaging of the Pelvic Floor

**Patient Preparation.**—The patient's preparation before the dynamic MR imaging examination



**Figure 14.** US of the normal anal sphincter at rest. **(a)** Axial transvaginal US image obtained with posterior angulation of the probe for evaluation of the anal canal shows the internal sphincter (\*) as a hypoechoic continuation of the circular muscle layer of the rectum. The external sphincter complex (arrowheads) consists of the inferior part of the levator ani muscle, the puborectalis muscle, and the external sphincter muscles. It comprises several parallel hyperechoic bundles and extends approximately 1.0 cm beyond the internal sphincter. **(b)** Coronal 3D transvaginal US image of the anal canal shows the hyperechoic puborectalis muscle (arrows) and the internal sphincter (\*).

includes a mild bowel preparation and fasting for 4 hours. Bowel preparation is optional and varies among institutions. The patient is instructed to use one rectal enema the night before the examination and another one up to 1 hour before the examination. In addition, she is asked to keep her bladder filled to the medium level. To prevent the misinterpretation of imaging results, the bladder should not be completely empty or fully distended. A fully distended bladder may obscure POP; however, having a small amount of urine in the bladder improves visualization of the bladder and anterior vaginal wall prolapse. With the patient already positioned on the MR imaging table and in a right decubitus position, with slightly bent knees, the distal rectum can be filled with 120–200 mL of ultrasound gel, which is introduced by using a flexible tube, and the vagina can be filled with 30–60 mL of the gel, which is introduced by using a syringe.

The patient wears an adult diaper, and the table is covered with an absorbent pad to minimize embarrassment related to the eventual loss of feces and/or urine. She receives 10 mg of butylscopolamine intravenously to reduce bowel peristalsis; half of this dose is injected immediately before the first MR imaging sequence, and the other half is administered before the T2-weighted 3D fast spin-echo sequence. This also is optional; at many institutions in North America, MR imaging is performed without the use of butylscopolamine, and no technical limitations are encountered. It is crucial to explain the details of the entire procedure and the maneuvers to the patient in advance, with use of simple and direct instructions. It is

also important to practice the maneuvers with the patient after she lies down on the table. She should understand the importance of the maneuvers for her diagnosis and treatment planning. It is also very important for the radiologist to ensure that the patient performs the maneuver properly—for example, with the caliber of the femoral vein increased during straining and with a change in the anorectal angle during contraction.

**Patient Examination.**—The MR imaging examination is usually performed in a closed-magnet system, with the patient supine and a pillow providing leg and knee support. The knees are kept slightly bent, with the hips at flexion. At our institution, we use a conventional 1.5-T MR imaging unit, and the examination is performed with a cardiac coil wrapped around the pelvis. The symphysis pubis is positioned in the middle of the coil. A proposed protocol for performing dynamic MR imaging of the pelvic floor is summarized in Table 1. The use of a 0.5-T open-magnet MR imaging system facilitates more functional patient positioning; however, the resultant images have a lower signal-to-noise ratio and lower soft-tissue resolution.

**Resting Examination.**—T2-weighted fast spin-echo MR images without fat saturation (5170/137; field of view, 26 cm; section thickness, 5 mm; matrix, 512 × 256) are acquired in the sagittal and axial planes for anatomic evaluation. A T2-weighted 3D fast spin-echo sequence (1500/123; field of view, 34 cm; section thickness, 1.4 mm;



Table 1: Suggested Protocol for Dynamic MR Imaging of the Pelvic Floor

Pulse Sequence	Imaging Plane	TR/TE (msec)	FOV (cm)	Section Thickness/Spacing (mm)	Matrix	Acquisition Phase
T2-weighted localizer	...	4850/1330	46	8/16	256 × 128	Rest
T2-weighted propeller	Sagittal, axial	5170/137	26	5/6	512 × 256	Rest
3D T2-weighted FSE	Coronal	1500/123	34	1.4/1.4	320 × 320	Rest
FIESTA	Axial	3760/1660	30	10/0	256 × 256	Rest and straining
FIESTA	Midsagittal	3840/1670	30	8/0	256 × 256	Rest and straining
FIESTA	Midsagittal	3840/1670	30	8/0	256 × 256	Squeezing
FIESTA	Midsagittal	3840/1670	30	8/0	256 × 256	Defecation

Note.—The dynamic fast imaging employing steady-state acquisition (FIESTA) sequence is performed during maximal straining, squeezing, and defecation. If the patient has difficulty defecating, the examination is repeated once or twice. The listed parameters were established by using a 1.5-T MR imaging system (Signa HD23; GE Healthcare, Milwaukee, Wis). FOV = field of view, FSE = fast spin echo, TE = echo time, TR = repetition time.

matrix, 320 × 320) is used to obtain isotropic data and therefore enable interactive multiplanar reformatting at random orientations.

**Dynamic Examination.**—Dynamic imaging is performed after the resting examination. It involves image acquisitions while the patient is at rest, squeezing (maximal sphincter contraction), straining (Valsalva maneuver), and defecating. The competence of the internal and external sphincters is verified during the straining phase. The squeezing phase yields information regarding the strength and integrity of the pelvic floor muscle. In the normal pelvic floor, the anorectal junction rises 1–2 cm from its resting position and the anorectal angle closes during squeezing. The defecation phase is the most important phase during the dynamic examination, as it enables better assessment and more accurate grading of POP. If the patient has difficulty defecating, the sequence is repeated until the rectal gel is fully or at least partially eliminated. Although there has been recent debate regarding the utility of the Valsalva maneuver, a considerable number of patients are not able to perform the defecation phase exercises. For the dynamic examination, FIESTA (3760/1660; field of view, 30 cm; section thickness, 10 mm; matrix, 256 × 256) is performed in the midsagittal plane and repeated 15–25 times. All dynamic imaging findings are analyzed in cine loop mode.

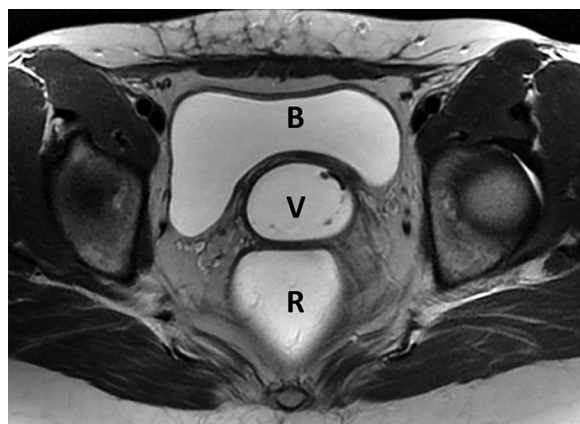
**MR Image Interpretation.**—The interpretation of pelvic floor MR images should be standardized and separated into two steps. Step 1 involves anatomic evaluation based on findings seen on high-resolution T2-weighted

images obtained to search for specific lesions of the architectural support structures of the pelvic floor (Fig 15). This evaluation should be focused on assessments of structural integrity, signal intensity, symmetry, and thickness. Step 2 involves functional and dynamic evaluations based on findings seen during the maneuvers, at which points of reference are applied to assess the presence and severity of POP (26,30) (Fig 16). The following are the most commonly used measurements—and were adopted as key imaging parameters—at our institution:

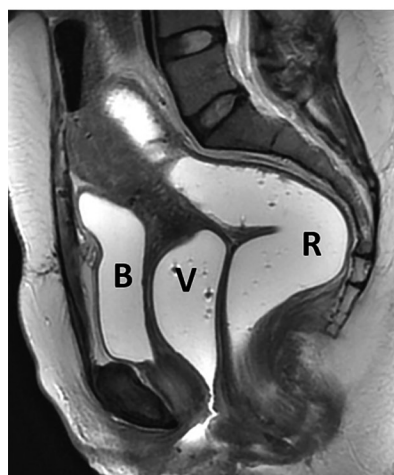The PCL demarcates the level of the pelvic floor and is the most important line for measuring POP on dynamic midsagittal MR images. This line extends from the inferior border of the symphysis pubis to the last coccygeal joint (Fig 17). POP can be graded according to the “rule of three”: The descent of an organ less than 3 cm below the PCL is considered mild prolapse. Organ descent 3–6 cm below the PCL is considered moderate prolapse, and a descent of more than 6 cm below the PCL is considered severe prolapse (30) (Table 2).

The H line is the distance from the inferior border of the symphysis pubis to the posterior anorectal junction on midsagittal MR images; this distance is indicative of the anteroposterior width of the levator hiatus (Fig 17). In women with a normal pelvic floor anatomy, this distance is approximately 5 cm. Widening or ballooning of the levator hiatus can be graded as mild, moderate, or severe (Table 3).

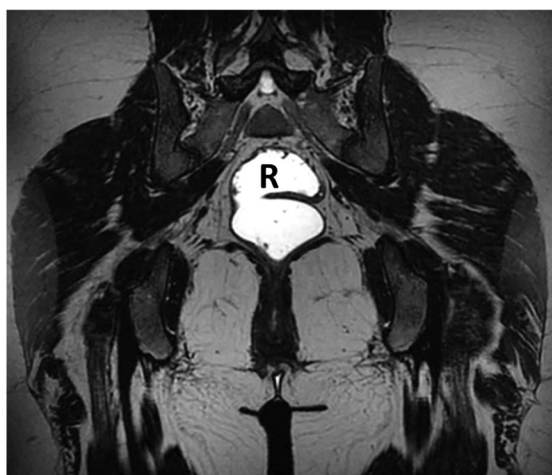The M line is a perpendicular line drawn from the PCL to the most distal aspect of the H line and is indicative of the descent of the levator hiatus from the PCL (Fig 17). In women with



a.



b.



c.

**Figure 15.** Assessment of the normal female pelvic anatomy at high-resolution MR imaging. Axial (a), sagittal (b), and coronal (c) T2-weighted fast spin-echo MR images of the pelvis without fat saturation show the distal rectum (R) filled with 160 mL of ultrasound gel and the vagina (V) filled with 60 mL of ultrasound gel. The bladder (B) is filled to the midlevel to prevent misinterpretation of findings. This protocol is very important for anatomic evaluation and for assessing the positions of the pelvic organs at rest.

**Table 2: Grading POP in Relation to the PCL**

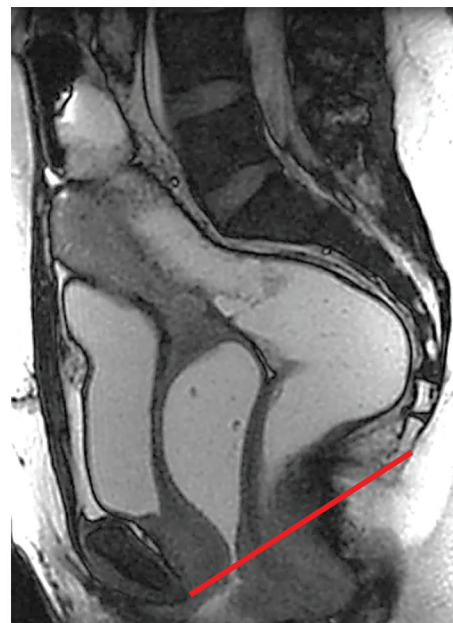Pathologic Finding	Mild POP*	Moderate POP*	Severe POP*
Cystocele	<3 cm	3–6 cm	>6 cm
Uterovaginal enterocele	<3 cm	3–6 cm	>6 cm
Peritoneocele	<3 cm	3–6 cm	>6 cm
Rectocele	<2 cm	2–4 cm	>4 cm

\*Values are depths of the structure's descent below the PCL.

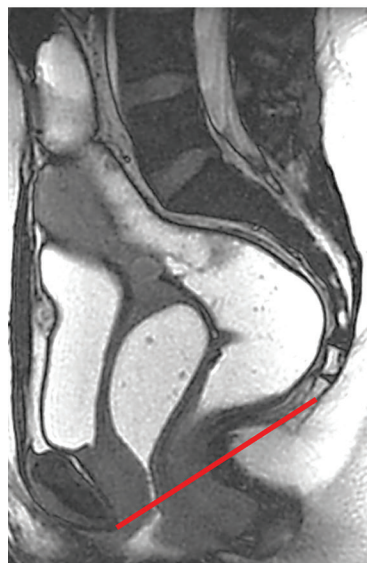
**Table 3: Grading Levator Hiatus Ballooning and DPS**

Reference Line	Mild	Moderate	Severe
H line	6–8 cm	8–10 cm	>10 cm
M line	2–4 cm	4–6 cm	>6 cm

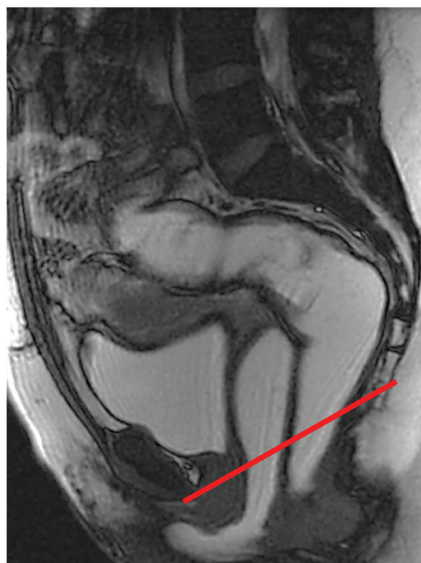**Figure 16.** Dynamic examination of the female pelvic floor with FIESTA sequence. Sagittal T2-weighted MR images obtained with the patient at rest (**a**), squeezing (**b**), performing the Valsalva maneuver (**c**), and defecating (**d**). The red line indicates the pubococcygeal line (PCL). Defecography is crucial for better grading and assessment of prolapse. Although patients are instructed on how to perform the maneuvers before the examination, many of them cannot perform a proper Valsalva maneuver when asked to do so. In such cases, diagnosis of cystocele, rectocele (\* in **d**), or DPS is possible during defecography only.



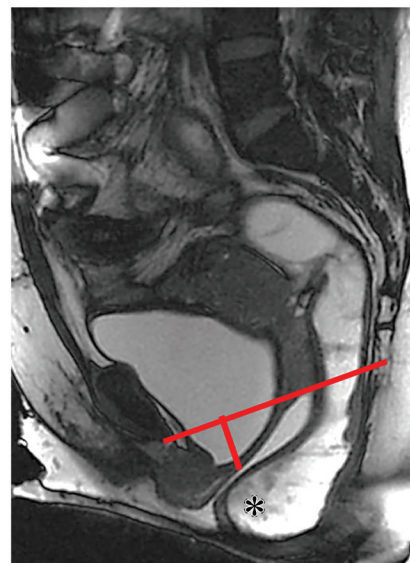
a.



b.



c.



d.

a normal pelvic floor anatomy, this distance is approximately 2 cm. DPS can be graded as mild, moderate, or severe (Table 3).

The anorectal angle is the angle between the central long axis of the anal canal and the posterior border of the rectum, and it normally measures 108°–127° at rest and varies between 15° and 20° during contraction or defecation (Fig 18).

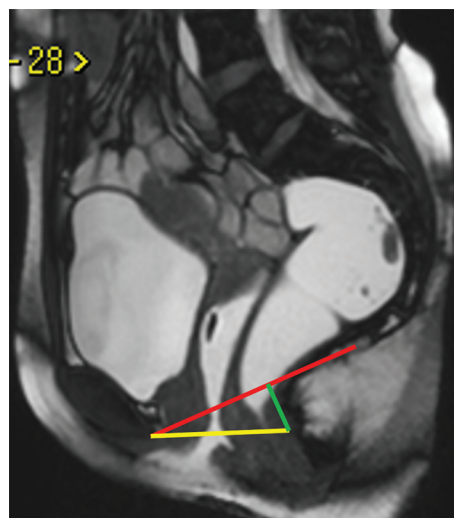
The midpubic line corresponds to the level of the vaginal hymen, which is the landmark for clinical staging, and is drawn along the long axis of the symphysis pubis. Measurements are made by drawing perpendicular lines from each reference point to the midpubic line. Using this line as the main reference, POP is assigned a stage, from 0 to 4 (44). There is no consensus regarding which line is best for staging POP: the PCL or

the midpubic line. At our institution, we adopted the PCL as the reference line for POP evaluation.

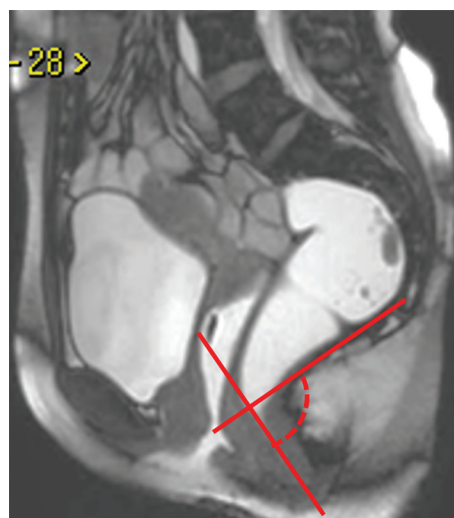
In the anterior compartment of the pelvis, the reference point is the most inferior aspect of the bladder base. In the middle compartment, the reference point is the most anterior and inferior aspect of the cervix or the vaginal posterior apex in patients who have undergone a hysterectomy. In the posterior compartment, the reference point is the anterior margin of the anorectal junction. In women with a normal pelvic floor anatomy, a minimal descent of the pelvic organs during defecation is considered normal.

The normal configuration of the levator plate at rest and during straining is parallel to the PCL on midsagittal MR images. Verticalization of the levator plate during the Valsalva maneuver and





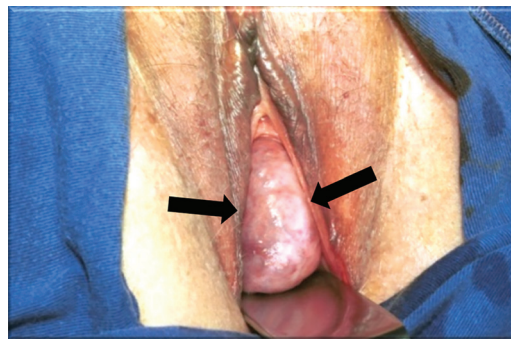
**Figure 17.** Midsagittal T2-weighted MR image of the normal pelvic floor anatomy at rest. The reference lines most frequently used for evaluation of PFD are the PCL (red), H line (yellow), and M line (green).



**Figure 18.** Sagittal T2-weighted MR image of the normal anorectal angle at rest. The anorectal angle (dashed line) is measured between two lines: one corresponding to the central axis of the anal canal and the other bordering the posterior wall of the rectum.

defecation phase is considered abnormal and a positive finding for DPS.

The axial plane is best for assessing the normal configuration of the hiatus—especially the vaginal anatomy, periurethral ligaments, anal sphincter, and pubovisceral muscle integrity. The normal vagina has a typical H shape or butterfly configuration, which can be easily demonstrated after vaginal distention with gel. Any change in this configuration may suggest a paravaginal fascial defect. The puborectalis muscle forms a U-shaped sling that comprises the urethra, vagina, and rectum, and it demonstrates homogeneous low



**Figure 19.** Photograph taken during the physical examination of a 62-year-old woman shows vaginal bulging caused by a cystocele (arrows).

signal intensity on T2-weighted MR images and symmetric components. The ileococcygeus muscle has a horizontal orientation and upward convexity and is better evaluated on coronal T2-weighted MR images. Levator ani injuries are characterized by asymmetry, thickness reduction, fat infiltration, and an increase in hiatal dimensions. In severe cases, the vagina loses its normal butterfly configuration and is retracted toward the lesion.

The normal urethra has a vertical orientation at rest and during maximal straining. Horizontalization of the urethral axis or an angulation greater than  $30^\circ$  can be associated with hypermobility. The smooth muscle of the urethra demonstrates high signal intensity on T2-weighted MR images and enhancement after contrast material injection.

Anal sphincters are better assessed in the axial and coronal planes. On T2-weighted MR images, the internal sphincter demonstrates intermediate signal intensity and the external sphincter complex demonstrates low signal intensity.

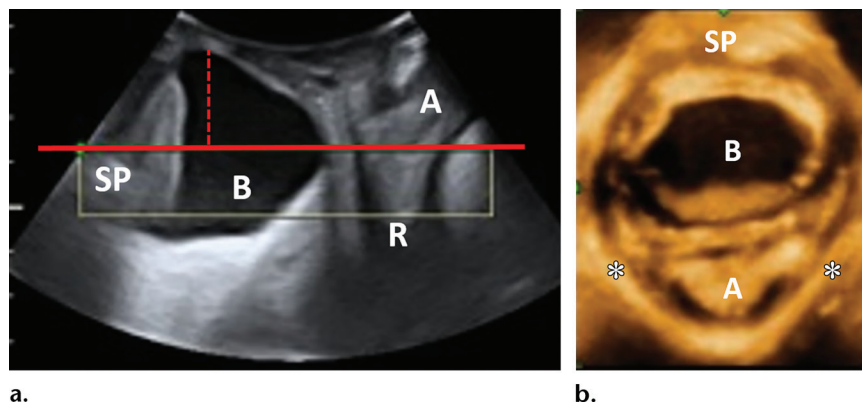
## Pathologic Conditions

### Anterior Compartment

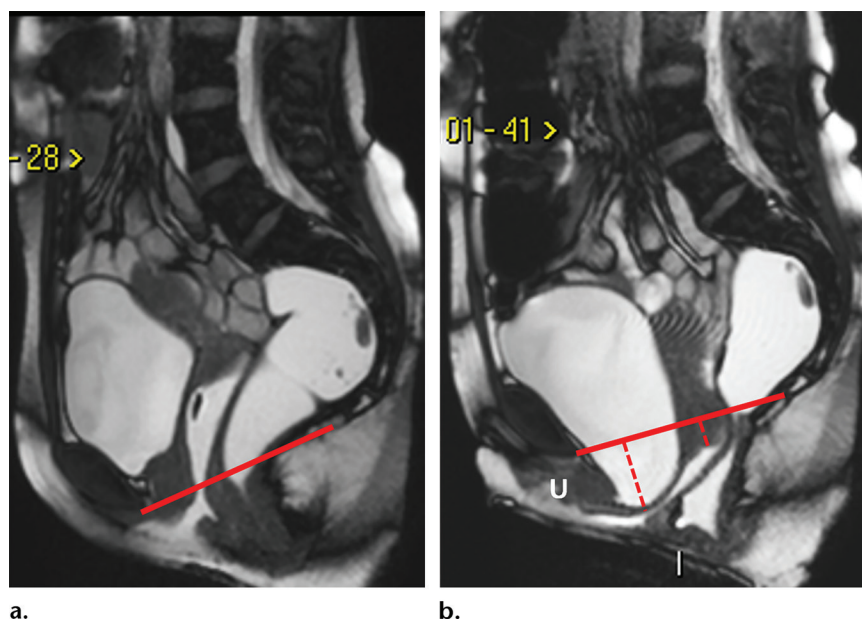
Abnormalities in the anterior pelvic compartment include cystocele and urethral hypermobility. *Cystocele* is defined as a descent of the posterior bladder wall or bladder neck of 1.0 cm below the PCL. It occurs owing to tearing or stretching that affects the pubocervical fascia or levator ani. Cystoceles are graded, according to the distance between the bladder base and the PCL, as mild ( $<3.0$  cm), moderate (3.0–6.0 cm), or severe ( $>6.0$  cm). The descent of the bladder enlarges the pelvic hiatus, displacing the vagina, uterus, and anorectal junction posteriorly. Clinically, vaginal bulging can be seen and is sometimes associated with eversion of the vaginal mucosa (Fig 19). Severe cystoceles can hide urethral hypermobility and impair bladder voiding (Fig 20, Movie 4).

Urethral hypermobility is a functional abnormality that involves a downward, greater than  $30^\circ$

**Figure 20.** Cystocele in a 60-year-old woman with vaginal bulging. Midsagittal 2D (a) and axial 3D volume-rendered (b) translabial US images simultaneously obtained during the Valsalva maneuver show bladder (B) prolapse (dashed red line in a) below the symphysis pubis (SP) line (solid red line in a) and ballooning of the levator hiatus (\* in b). The rectangle in a outlines the volume of images obtained during the Valsalva maneuver. A = anal canal, R = rectum.



**Figure 21.** Cystourethrocele and mild uterine prolapse in a 66-year-old woman who previously underwent surgery for urinary incontinence. Sagittal FIESTA MR images show the pelvic floor at rest (a) and during the Valsalva maneuver (b). The solid line is the PCL. During straining (b), a moderate cystocele (long dashed line) and mild uterine prolapse (short dashed line) are seen. Note the horizontal orientation and clockwise rotation of the urethral axis (U) during the Valsalva maneuver.

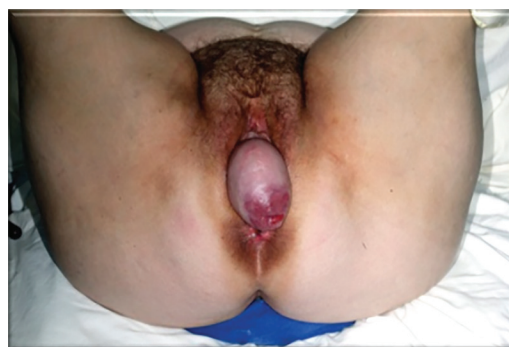

clockwise rotation of the urethral axis after an increase in intra-abdominal pressure. It can be associated with funneling (opening with urinary filling of the proximal third of the urethra) and urinary leakage and is secondary to loss of periurethral and paraurethral support (Fig 21, Movie 5). Stress-induced urinary incontinence is related to urethral hypermobility or intrinsic urethral sphincter deficiency.

Both translabial US and MR imaging enable reliable evaluation of cystoceles and urethral hypermobility. However, translabial US has a slight advantage over MR imaging in the quantification of urethral hypermobility.

### Middle Compartment

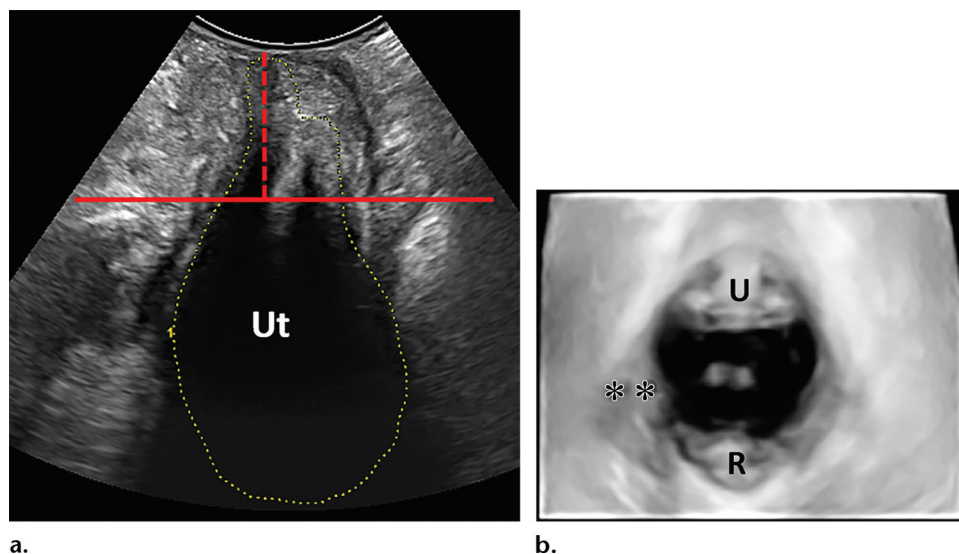
Weakness of the middle compartment support structures, including the pubocervical fascia, rectovaginal fascia, parametrium (ie, uterosacral and cardinal ligaments), and paracolpium, results in uterine and vaginal prolapse (Fig 22). After a hysterectomy, prolapse of the scar site, referred to as apical prolapse, is related to para-



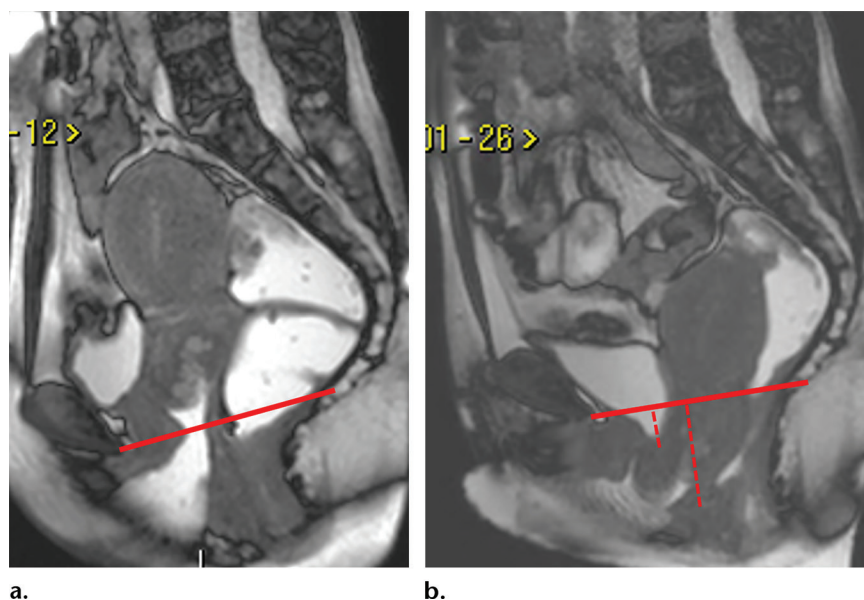
**Figure 22.** Photograph taken during the physical examination of a 51-year-old woman shows complete uterine prolapse (ie, procidentia). The vaginal walls are everted, and the uterus is a bulging mass projecting beyond the external genitalia.

colpium and cervical ring damage. In normal conditions, the scar site will remain at least 1.0 cm above the PCL during the Valsalva maneuver and defecation phase. With uterine prolapse, the hiatal area will be widened with associated ballooning at translabial US. At MR imaging, the





**Figure 23.** Uterine prolapse in a 52-year-old woman with a perineal mass and a history of two vaginal deliveries. **(a)** Midsagittal 2D translabial US image obtained during the Valsalva maneuver shows uterine prolapse (dashed red line) below the symphysis pubis line (solid red line). *Ut* = uterus. **(b)** Axial 3D volume-rendered translabial US image shows ballooning of the levator hiatus in association with right-side avulsion (\*\*) of the puborectalis muscle. *R* = rectum, *U* = urethra.



**Figure 24.** POP in a 55-year-old woman with perineal bulging and urinary incontinence. Sagittal FIESTA MR images show no apparent abnormalities at rest **(a)** but a mild cystocele (short dashed line) and severe uterine prolapse (long dashed line) during maximal straining **(b)**. The solid line is the PCL.

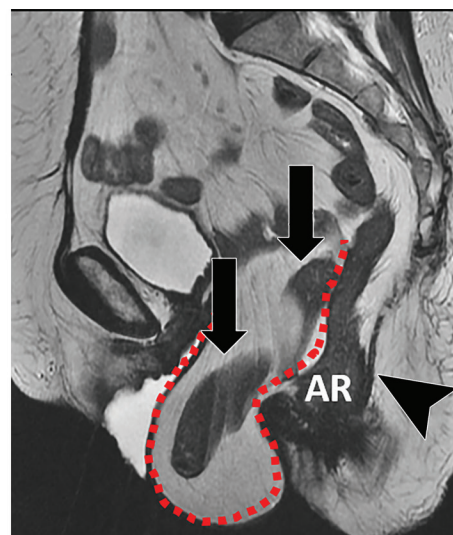
H and M lines will be elongated and the vagina will demonstrate a vertical orientation—sometimes with shortened length. Uterine prolapse can be graded as mild (<3 cm), moderate (3–6 cm), or severe (>6 cm) (Figs 23, 24; Movies 6, 7). Owing to difficulties visualizing the uterine cervix and scar site at translabial US, MR imaging is more accurate for the evaluation of uterine and apical prolapse—especially in elderly women.

Another abnormality related to weakening of the rectovaginal fascia that may occur in the middle compartment is herniation of the cul-de-sac. The normal location of the pouch of

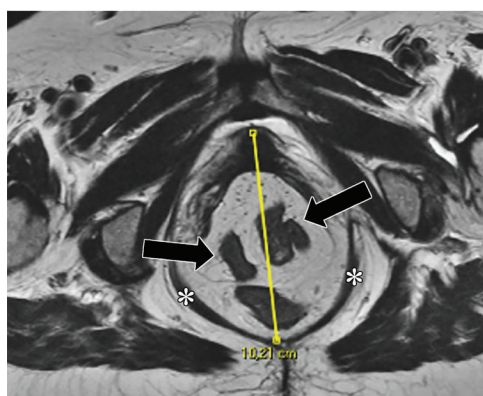
Douglas is at the level of the posterior vaginal fornix, with a variation in depth no greater than 5 cm. These hernias are named according to their content. For example, the hernia is called an enterocele if it contains a small-bowel loop, a sigmoidocele if it contains a small portion of the sigmoid colon, and a peritoneocele if it contains only fat tissue. Because of the typical configuration of the rectal ampulla at rest and during straining, these hernias may be evident at the end of the defecation only. Large enteroceles can impair and cause incomplete defecation by compressing the anorectal junction. Previous hysterectomy is a predisposing factor and increases the



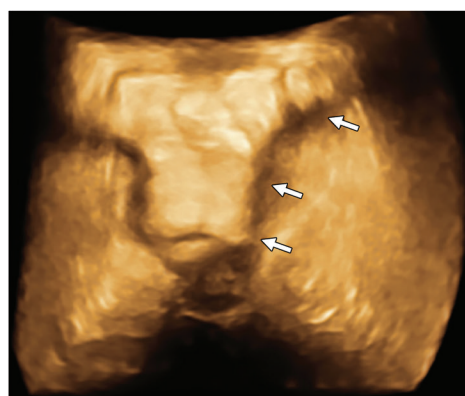
**Figure 25.** Peritoneocele and enterocele in a 72-year-old woman with a history of previous hysterectomy, who reported having a perineal mass and constipation. **(a)** Sagittal FIESTA MR image of the pelvic floor at rest shows a pouch of Douglas (dashed line) hernia containing small-bowel loops (arrows). The vagina has a vertical orientation and shows signals of apical prolapse. Note the vertical orientation of the levator plate (arrowhead) and the descent of the anorectal junction (AR), which are indicative of pelvic floor descent. **(b)** Axial T2-weighted MR image obtained in the plane of the pelvic hiatus shows severe ballooning, with increased anteroposterior length (vertical line) of the hiatus and a stretched puborectalis muscle (\*). Small-bowel loops (arrows) can be seen in this atypical location. **(c)** Axial 3D volume-rendered translabial US image shows the herniated sac, which contains small-bowel loops (arrows).



a.



b.

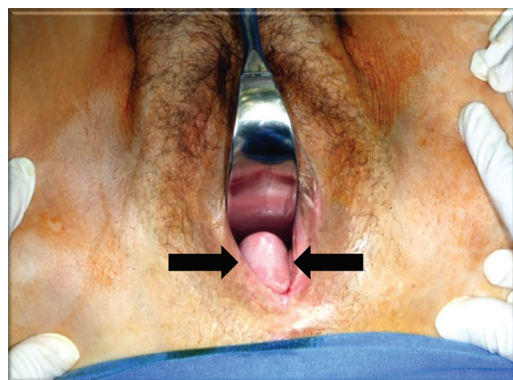


c.

probability of an enterocele. Translabial US and MR imaging are more accurate for diagnosis of this abnormality than is conventional defecography because they can be used to elucidate the hernia content (Fig 25; Movies 8, 9).

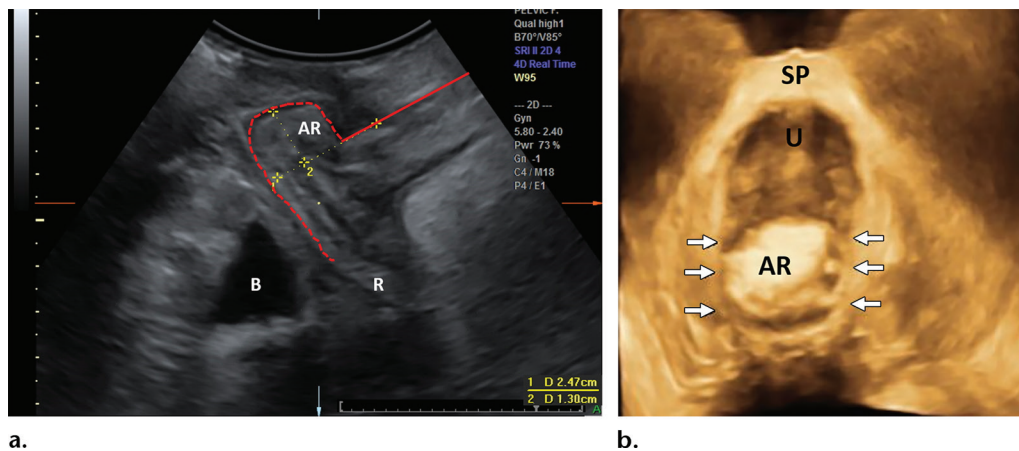
### Posterior Compartment

The most common abnormality in the posterior compartment of the pelvis is an anterior rectocele. *Anterior rectocele* is defined as bulging of the anterior rectal wall caused by herniation of the rectal wall into the posterior vaginal wall due to weakness in the rectovaginal fascia. This abnormality can be asymptomatic and clinically irrelevant when it protrudes less than 2 cm from the expected margin in a woman without defecatory dysfunction. Anterior rectoceles that protrude up to 3.0 cm from the margin are an important cause of obstructed or incomplete defecation. Rectoceles are classified, according to their depth of protrusion beyond the expected margin, as mild (<2 cm), moderate (2–4 cm), or severe (>4 cm) (Table 2). Although a physical examination can be performed to readily identify a rectocele, it has limited

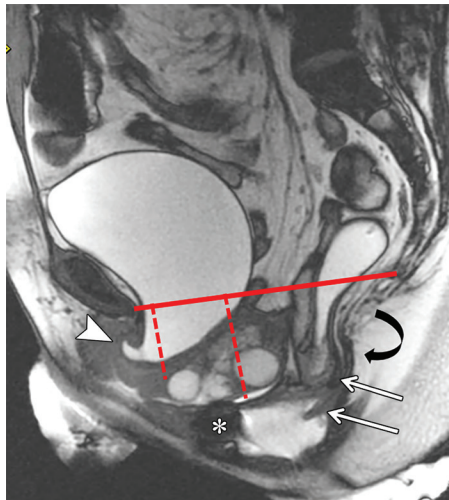


**Figure 26.** Photograph taken during the physical examination of a 48-year-old woman, who reported having constipation and obstructed defecation, shows an anterior rectocele (arrows).

value in the differentiation between rectoceles and complex abnormalities such as enteroceles and peritoneoceles (Fig 26). Translabial US and MR imaging enable direct visualization of the anterior rectal wall during dynamic maneuvers and the content of the pouch of Douglas. In addition, MR imaging yields useful information regarding



**Figure 27.** Anterior rectocele in a 38-year-old woman with constipation and incomplete defecation. **(a)** Mid-sagittal 2D translabial US image obtained during the Valsalva maneuver shows bulging of the anterior rectal wall (dashed red line). The depth of the bulging is measured perpendicular to the expected contour of the anterior aspect of the rectal muscularis (solid red line). AR = anterior rectocele, B = bladder, R = rectum. **(b)** Simultaneously obtained axial 3D volume-rendered translabial US image shows the anterior rectocele (AR) protruding into the pelvic hiatus (arrows). SP = symphysis pubis, U = urethra.



**Figure 28.** Sagittal T2-weighted MR image obtained in a 63-year-old woman with POP and a history of partial hysterectomy. A cystourethrocele (short dashed line) is seen with funneling (arrowhead) in the anterior compartment. Severe cervical prolapse (long dashed line) is observed in the middle compartment. Intrarectal intussusception (straight arrows) and an anterior rectocele (\*) are seen in the posterior compartment. Note the caudal angulation of the levator plate (curved arrow) and the descent of the anorectal junction. The solid line is the PCL.

rectocele filling and emptying and stool retention (Fig 27; Movies 10, 11). The capability to perform imaging during the defecation phase makes MR imaging superior to translabial US for the evaluation of abnormalities in the posterior compartment. Posterior and lateral rectoceles are less common. Coronal dynamic MR imaging has been recommended for diagnosing lateral rectoceles.

Prolapse in the posterior compartment is related to rectal intussusception, with which there is

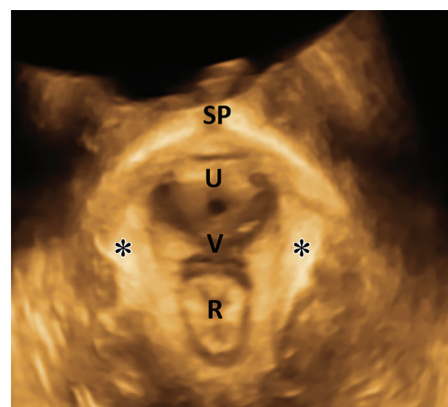
full-thickness wall invagination and eversion of the rectum, with mechanical obstruction to stool passage. Simple mucosal prolapse may occur, but it is not associated with obstructive defecation. There are three degrees of intussusception, which are classified according to the extent of rectal exteriorization at the end of the defecation: *(a)* intra-rectal intussusception with minimal involvement of the rectal wall, *(b)* intussusception restricted to the anal canal, and *(c)* intussusception extending beyond the anal canal and prolapsing through the anus (Fig 28). MR imaging enables accurate differentiation between the intussusception types and yields invaluable information for surgical planning. An S-shaped rectum may mimic intussusception; correlation with coronal T2-weighted MR imaging findings is required before a conclusion can be made. Evaluation of intussusception may be limited with translabial US owing to a lack of proper straining during the Valsalva maneuver.

### DPS and Functional Constipation

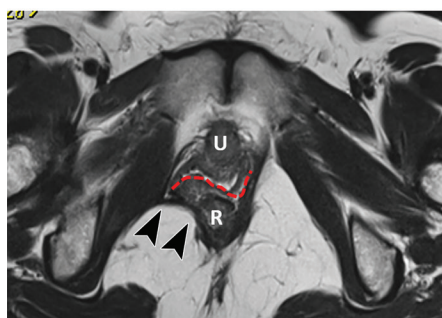
DPS is a complex condition caused by loss of pelvic organ support, with resultant descent of the pelvic floor at rest and during straining. A lower position of the anorectal junction at rest is a good indicator of muscle weakness and fascia stretching (45). A widened hiatal area affecting all three compartments is seen and is commonly associated with POP. At translabial US, the diagnosis of DPS can be suggested on the basis of hiatal measurements obtained during the Valsalva maneuver, with areas larger than 40 cm<sup>2</sup> highly associated with POP. With MR imaging, DPS can be quantified by measuring the M line, with a descent greater than 2.5 cm considered positive for this syndrome. In addition, an H-line distance of greater than 5



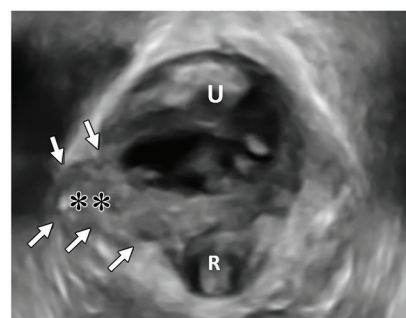
**Figure 29.** The levator ani at the level of the pelvic hiatus. *R* = rectum, *U* = urethra. **(a)** Axial 3D volume-rendered translabial US image shows a normal puborectalis muscle (\*). *SP* = symphysis pubis, *V* = vagina. **(b)** Axial T2-weighted MR image shows a typical right-side avulsion injury (arrowheads), with associated loss of the butterfly shape of the vagina (dashed line). **(c)** Axial 3D volume-rendered translabial US image obtained in the patient in **b** shows the right-side avulsion (arrows), with a gap (\*\*) between the muscle bundles.



a.



b.



c.

cm indicates widening of the elevator hiatus. At sagittal T2-weighted MR imaging, the elevator plate can have a vertical orientation. However, this is not a specific finding of DPS; it can also be present with isolated posterior compartment descent.

Functional constipation, another common entity encountered in gastroenterology clinics, is associated with rectal inertia and spastic pelvic floor syndrome. The treatment for this condition is conservative and based on positive biologic feedback. MR imaging has a crucial role in identifying affected patients and distinguishing them from the pool of potential surgical candidates.

### Anismus

Anismus, or paradoxical contraction, of the puborectalis muscle is an involuntary contraction of the striated pelvic floor musculature. It is associated with nonrelaxation of the external sphincter complex and impairs normal defecation. Imaging findings include persistent contraction of the puborectalis muscle during the Valsalva maneuver and defecation phase, with a lack of pelvic floor descent, maintaining an acute anorectal angle. The clinical manifestation is constipation with prolonged and incomplete defecation.

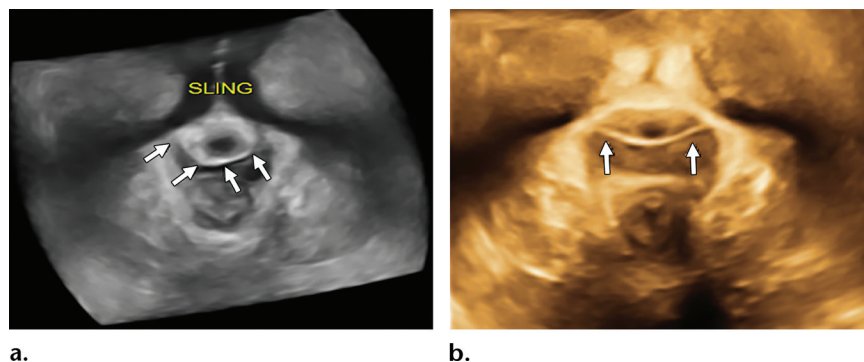
### Pubovisceral Lesions

Puborectalis muscle abnormalities are very common among women after vaginal delivery and are considered a predisposing factor for POP—cys-

tocele and uterine prolapse in particular (46). Although right-side or bilateral avulsion of the muscle off the pelvic sidewall is the most common morphologic cause of these abnormalities, other causes, such as congenital hyperdistensibility, delivery-related microtrauma, neuropathy, and fascial trauma, may have a role in these muscle injuries. Because the medial margin of the levator ani is connected to the urethral support structures, the integrity of this muscle also has an important role in the development of urinary incontinence. The levator ani is palpable at physical examination, which, however, has low accuracy in the detection of avulsion compared with imaging methods (47,48).

Translabial US and MR imaging are excellent imaging modalities for depicting normal and abnormal levator ani muscles (Fig 29). With translabial US, both rendered volumes and single sections in the axial plane can be used to detect defects. Tomographic US is particularly useful because it enables screening of one 3D volume, and defects are more apparent during contraction. At MR imaging, the axial plane orthogonal to the pelvis is the plane of choice for evaluating the pelvic hiatus and puborectalis muscle. Symmetry, thickness, signal intensity, and sling configuration are the most important criteria to evaluate. Difficulties can arise in elderly women with marked muscle atrophy. Anatomic changes in the vagina, with angulated margins and loss of the butterfly configuration, are suggestive of muscle avulsion.





**Figure 30.** Axial 3D volume-rendered translabial US images of the levator hiatus obtained for sling evaluation show a retropubic suburethral sling (arrows in a) surrounding the urethra and a trans-obturator sling (arrows in b).

## Sling Evaluation

During the past 10 years, use of suburethral slings to treat urinary incontinence has become widespread. Conventional radiography and MR imaging are very limited in the identification of these implants. Translabial US is the best imaging modality for identifying and locating mesh implants and evaluating their functionality. It is also possible to evaluate variations in the structure and placement of the sling—for example, asymmetry and twisting—and distinguish the different types of sling material. Treatment failure secondary to a loose or tight sling, as well as caudal displacement of the tension-free vaginal tape, also can be assessed with translabial US. Patients are sometimes not aware of the presence of the implant or the nature of the previous perineal surgery. Mesh implants appear hyperechogenic on US images. Volume-rendered US images are best for assessing the type and morphology of a mesh implant, and midurethral placement is considered the optimal location for success (Fig 30; Movie 12).

Deep mesh implants that are placed through the obturator foramen and used to treat recurrent prolapse in the anterior compartment are highly echogenic and visible with 3D and 4D translabial US, especially during real-time evaluation with the Valsalva maneuver. One of the limitations of US is poor depiction of deep mesh anchors used to treat apical prolapse—for example, those used for sacropexy. Complications such as recurrent stress-induced urinary incontinence, erosion, voiding dysfunction, and postoperative symptoms of irritable bladder are another reason to perform imaging assessment. MR imaging is superior to translabial US for evaluation of abscess formation and inflammatory processes owing to the high resolution of static images with superior anatomic definition.

## Conclusion

PFD affects a large number of women and increases with age. Thorough knowledge of the pelvic anatomy and careful evaluation of all pelvic

compartments are crucial for clinical counseling and surgical planning. Physical examination has limited diagnostic value, especially in complex cases. Translabial US and dynamic MR imaging of the pelvic floor enable comprehensive noninvasive evaluation of the three pelvic compartments simultaneously during a single procedure. Compared with dynamic MR imaging, translabial US is fast and relatively simple to perform and has greater availability. However, it is not entirely well-known throughout the radiology field. Dynamic MR imaging of the pelvic floor yields high-quality images of all pelvic components, and dynamic sequences enable functional evaluation. Although the cost of MR imaging is an important concern, this modality can be used in place of routinely used conventional imaging examinations such as excretory urography, voiding urethrocytography, and defecography, making it a reasonable and cost-effective option.

We suggest that translabial US can be used as the first imaging modality, especially for examination of patients with mild or moderate disease affecting the anterior compartment and for evaluation of synthetic implants. MR imaging should be performed in complex cases involving multicompartmental disease and for evaluation of postoperative complications such as abscess and inflammatory processes.

## References

1. Olsen AL, Smith VJ, Bergstrom JO, Colling JC, Clark AL. Epidemiology of surgically managed pelvic organ prolapse and urinary incontinence. *Obstet Gynecol* 1997;89(4):501–506.
2. Nygaard I, Barber MD, Burgio KL, et al. Prevalence of symptomatic pelvic floor disorders in US women. *JAMA* 2008;300(11):1311–1316.
3. Boyles SH, Weber AM, Meyn L. Procedures for urinary incontinence in the United States, 1979–1997. *Am J Obstet Gynecol* 2003;189(1):70–75.
4. Mant J, Painter R, Vessey M. Epidemiology of genital prolapse: observations from the Oxford Family Planning Association Study. *Br J Obstet Gynaecol* 1997;104(5):579–585.
5. Ghetti C, Gregory WT, Edwards SR, Otto LN, Clark AL. Pelvic organ descent and symptoms of pelvic floor disorders. *Am J Obstet Gynecol* 2005;193(1):53–57.
6. Jelovsek JE, Barber MD. Women seeking treatment for advanced pelvic organ prolapse have decreased body image and quality of life. *Am J Obstet Gynecol* 2006;194(5):1455–1461.

7. Bump RC, Mattiasson A, Bø K, et al. The standardization of terminology of female pelvic organ prolapse and pelvic floor dysfunction. *Am J Obstet Gynecol* 1996;175(1):10–17.
8. Woodfield CA, Hampton BS, Sung V, Brody JM. Magnetic resonance imaging of pelvic organ prolapse: comparing pubococcygeal and midpubic lines with clinical staging. *Int Urogynecol J Pelvic Floor Dysfunct* 2009;20(6):695–701.
9. Petros PE, Woodman PJ. The integral theory of continence. *Int Urogynecol J Pelvic Floor Dysfunct* 2008;19(1):35–40.
10. Petros PE, Ulmsten UI. An integral theory of female urinary incontinence: experimental and clinical considerations. *Acta Obstet Gynecol Scand Suppl* 1990;153:7–31.
11. Santoro GA, Wiczczonek AP, Dietz HP, et al. State of the art: an integrated approach to pelvic floor ultrasonography. *Ultrasound Obstet Gynecol* 2011;37(4):381–396.
12. Dietz HP. The evolution of ultrasound in urogynecology. *Ultrasound Obstet Gynecol* 2010;36(6):655–657.
13. Chamié LP, Blasbalg R, Pereira RMA, Warmbrand G, Serafini PC. Findings of pelvic endometriosis at transvaginal US, MR imaging, and laparoscopy. *RadioGraphics* 2011;31(4):E77–E100.
14. Weber AM, Abrams P, Brubaker L, et al. The standardization of terminology for researchers in female pelvic floor disorders. *Int Urogynecol J Pelvic Floor Dysfunct* 2001;12(3):178–186.
15. Herschorn S. Female pelvic floor anatomy: the pelvic floor, supporting structures, and pelvic organs. *Rev Urol* 2004;6(suppl 5):S2–S10.
16. DeLancey JO. Structural support of the urethra as it relates to stress urinary incontinence: the hammock hypothesis. *Am J Obstet Gynecol* 1994;170(6):1713–1720; discussion 1720–1723.
17. DeLancey JO. Correlative study of paraurethral anatomy. *Obstet Gynecol* 1986;68(1):91–97.
18. Macura KJ, Genadry RR, Bluemke DA. MR imaging of the female urethra and supporting ligaments in assessment of urinary incontinence: spectrum of abnormalities. *RadioGraphics* 2006;26(4):1135–1149.
19. Ramanah R, Berger MB, Parratte BM, DeLancey JO. Anatomy and histology of apical support: a literature review concerning cardinal and uterosacral ligaments. *Int Urogynecol J Pelvic Floor Dysfunct* 2012;23(11):1483–1494.
20. Larson KA, Yousuf A, Lewicky-Gaupp C, Fenner DE, DeLancey JO. Perineal body anatomy in living women: 3-dimensional analysis using thin-slice magnetic resonance imaging. *Am J Obstet Gynecol* 2010;203(5):494.e15–494.e21.
21. Kearney R, Sawhney R, DeLancey JO. Levator ani muscle anatomy evaluated by origin-insertion pairs. *Obstet Gynecol* 2004;104(1):168–173.
22. Brandon CJ, Lewicky-Gaupp C, Larson KA, Delancey JO. Anatomy of the perineal membrane as seen in magnetic resonance images of nulliparous women. *Am J Obstet Gynecol* 2009;200(5):583.e1–583.e6.
23. DeLancey JO. Anatomic aspects of vaginal eversion after hysterectomy. *Am J Obstet Gynecol* 1992;166(6 Pt 1):1717–1724; discussion 1724–1728.
24. DeLancey JO. Anatomy and biomechanics of genital prolapse. *Clin Obstet Gynecol* 1993;36(4):897–909.
25. Kaur H, Choi H, You YN, et al. MR imaging for preoperative evaluation of primary rectal cancer: practical considerations. *RadioGraphics* 2012;32(2):389–409.
26. Yang A, Mostwin JL, Rosenshein NB, Zerhouni EA. Pelvic floor descent in women: dynamic evaluation with fast MR imaging and cinematic display. *Radiology* 1991;179(1):25–33.
27. Colaiacono MC, Masselli G, Poletti E, et al. Dynamic MR imaging of the pelvic floor: a pictorial review. *RadioGraphics* 2009;29(3):e35.
28. Law YM, Fielding JR. MRI of pelvic floor dysfunction: review. *AJR Am J Roentgenol* 2008;191(suppl 6):S45–S53.
29. Johnson P, Larson KA, Hsu Y, Fenner DE, Morgan D, Delancey JO. Self-reported natural history of recurrent prolapse among women presenting to a tertiary care center. *Int J Gynaecol Obstet* 2013;120(1):53–56.
30. García del Salto L, de Miguel Criado J, Aguilera del Hoyo LF, et al. MR imaging-based assessment of the female pelvic floor. *RadioGraphics* 2014;34(5):1417–1439.
31. Dietz HP. Pelvic floor ultrasound in prolapse: what's in it for the surgeon? *Int Urogynecol J Pelvic Floor Dysfunct* 2011;22(10):1221–1232.
32. Dietz HP. Pelvic floor ultrasound: a review. *Am J Obstet Gynecol* 2010;202(4):321–334.
33. Haylen BT. Verification of the accuracy and range of transvaginal ultrasound in measuring bladder volumes in women. *Br J Urol* 1989;64(4):350–352.
34. Yang JM, Huang WC. Bladder wall thickness on ultrasonographic cystourethrography: affecting factors and their implications. *J Ultrasound Med* 2003;22(8):777–782.
35. Dietz HP, Clarke B, Herbison P. Bladder neck mobility and urethral closure pressure as predictors of genuine stress incontinence. *Int Urogynecol J Pelvic Floor Dysfunct* 2002;13(5):289–293.
36. Dietz HP, Shek C, Clarke B. Biometry of the pubovisceral muscle and levator hiatus by three-dimensional pelvic floor ultrasound. *Ultrasound Obstet Gynecol* 2005;25(6):580–585.
37. Dietz HP, Lanzarone V. Levator trauma after vaginal delivery. *Obstet Gynecol* 2005;106(4):707–712.
38. Fielding JR, Dumanli H, Schreyer AG, et al. MR-based three-dimensional modeling of the normal pelvic floor in women: quantification of muscle mass. *AJR Am J Roentgenol* 2000;174(3):657–660.
39. Dietz HP, Haylen BT, Broome J. Ultrasound in the quantification of female pelvic organ prolapse. *Ultrasound Obstet Gynecol* 2001;18(5):511–514.
40. Peschers UM, DeLancey JO, Schaer GN, Schuessler B. Exoanal ultrasound of the anal sphincter: normal anatomy and sphincter defects. *Br J Obstet Gynaecol* 1997;104(9):999–1003.
41. Yagel S, Valsky DV. Three-dimensional transperineal ultrasonography for evaluation of the anal sphincter complex: another dimension in understanding peripartum sphincter trauma. *Ultrasound Obstet Gynecol* 2006;27(2):119–123.
42. Sultan AH, Kamm MA, Hudson CN, Thomas JM, Bartram CI. Anal-sphincter disruption during vaginal delivery. *N Engl J Med* 1993;329(26):1905–1911.
43. Schuettoff S, Beyersdorff D, Gauruder-Burmester A, Tunn R. Visibility of the polypropylene tape after tension-free vaginal tape (TVT) procedure in women with stress urinary incontinence: comparison of introital ultrasound and magnetic resonance imaging in vitro and in vivo. *Ultrasound Obstet Gynecol* 2006;27(6):687–692.
44. Singh K, Reid WM, Berger LA. Assessment and grading of pelvic organ prolapse by use of dynamic magnetic resonance imaging. *Am J Obstet Gynecol* 2001;185(1):71–77.
45. Maglinte DD, Bartram CI, Hale DA, et al. Functional imaging of the pelvic floor. *Radiology* 2011;258(1):23–39.
46. DeLancey JO, Morgan DM, Fenner DE, et al. Comparison of levator ani muscle defects and function in women with and without pelvic organ prolapse. *Obstet Gynecol* 2007;109(2 Pt 1):295–302.
47. Kearney R, Miller JM, Delancey JO. Interrater reliability and physical examination of the pubovisceral portion of the levator ani muscle, validity comparisons using MR imaging. *Neurourol Urodyn* 2006;25(1):50–54.
48. Dietz HP, Hyland G, Hay-Smith J. The assessment of levator trauma: a comparison between palpation and 4D pelvic floor ultrasound. *Neurourol Urodyn* 2006;25(5):424–427.