



RadioGraphics

Errata

September-October 2020 • Volume 40 • Number 5

Originally published in:

RadioGraphics 2020; 40:1090–1106 • DOI: 10.1148/rg.2020190132

Imaging Coccygeal Trauma and Coccydynia

Matthew R. Skalski, George R. Matcuk, Dakshesh B. Patel, Anderanik Tomasian,

Eric A. White, Jordan S. Gross

Erratum in:

RadioGraphics 2020;40(5):1504

DOI: 10.1148/rg/2020209006

Page 1102, Figure 22: The incorrect image was shown for Figure 22c. Figure 22 and the figure legend are reprinted correctly here.

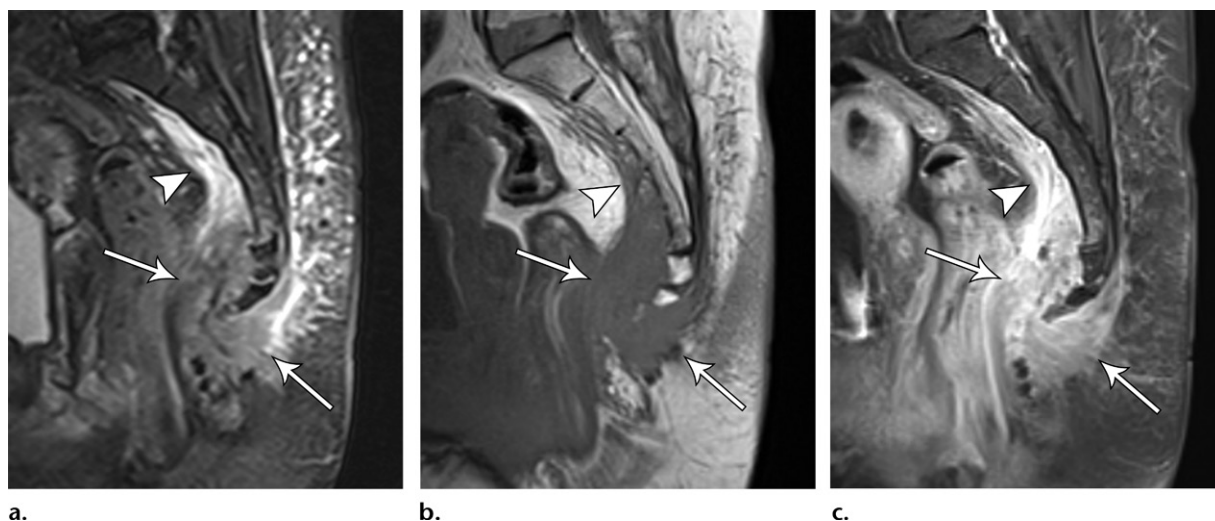


Figure 22. Paraganglioma in a 68-year-old woman with 2 years of worsening sacrococcygeal pain. Sagittal STIR (a), T1-weighted (b), and contrast-enhanced T1-weighted fat-suppressed (c) images show an enhancing mass lesion surrounding the coccyx (arrows), extending cephalad into the presacral fat (arrowhead). This proved to be a paraganglioma.