

What Radiologists Need to Know about Diagnosis and Treatment of Inflammatory Breast Cancer: A Multidisciplinary Approach¹

ONLINE-ONLY SA-CME

See www.rsna.org/education/search/RG

LEARNING OBJECTIVES

After completing this journal-based SA-CME activity, participants will be able to:

- Describe how multimodality breast imaging is used to diagnosis IBC.
- Identify ways that breast cancer specialists use imaging to plan treatment for patients with IBC.
- Discuss the role of breast imagers as members of the multidisciplinary team caring for patients with IBC.

TEACHING POINTS

See last page

Eren D. Yeh, MD • Heather A. Jacene, MD • Jennifer R. Bellon, MD • Faina Nakhlis, MD • Robyn L. Birdwell, MD • Dianne Georgian-Smith, MD • Catherine S. Giess, MD • Judi Hirshfeld-Bartek, RN • Beth Overmoyer, MD • Annick D. Van den Abbeele, MD

Inflammatory breast cancer (IBC) is a rare breast cancer with a highly virulent course and low 5-year survival rate. Trimodality treatment that includes preoperative chemotherapy, mastectomy, and radiation therapy is the therapeutic mainstay and has been shown to improve prognosis. Proper diagnosis and staging of IBC is critical to treatment planning and requires a multidisciplinary approach that includes imaging. Patients with IBC typically present with rapid onset of breast erythema, edema, and peau d'orange. Both tissue diagnosis of malignancy and clinical findings of inflammatory disease are required to confirm diagnosis of IBC. Imaging is used to identify a biopsy target; direct biopsy; stage IBC; differentiate curable from incurable (stage IV) disease; and help plan chemotherapy, surgical management, and radiation therapy. Comparison of baseline and posttreatment images helps confirm and quantitate disease response. When imaging is used early in the course of therapy to noninvasively predict treatment response, optimal tailored strategies for management of IBC can be implemented. Imaging is vital to diagnosis and treatment planning for patients with IBC, and radiologists are an integral part of the multidisciplinary patient care team.

Introduction

Inflammatory breast cancer (IBC) is a rare subtype of breast cancer that accounts for 2%–5% of all breast cancers. It has a highly virulent course with a low 5-year survival rate of 25%–50% (1). Trimodality treatment that includes preoperative chemotherapy, mastectomy, and radiation therapy is the therapeutic mainstay and has been shown to improve prognosis (2–4). Proper diagnosis and tumor staging is critical to designing the best treatment approach for patients with IBC and requires a multidisciplinary approach that includes imaging (5).

Abbreviations: BI-RADS = Breast Imaging Reporting and Data System, ER = estrogen receptor, FDG = fluorine-18 fluorodeoxyglucose, HER2 = human epidermal growth factor receptor 2, IBC = inflammatory breast cancer, LABC = locally advanced breast cancer, PR = progesterone receptor

RadioGraphics 2013; 33:2003–2017 • Published online 10.1148/rg.337135503 • Content Codes: **BR** **OI**

¹From the Division of Breast Imaging, Department of Radiology, Brigham and Women's Hospital and Harvard Medical School, 75 Francis St, RA Bldg, RA-014, Boston, MA 02115 (E.D.Y., R.L.B., D.G.S., C.S.G.); and Department of Imaging (H.A.J., A.D.V.d.A.), Department of Radiation Oncology (J.R.B.), Department of Surgery (F.N.), Department of Breast Oncology (B.O.), and Inflammatory Breast Cancer Program (E.D.Y., H.A.J., J.R.B., F.N., J.H.B., B.O.), Dana-Farber Cancer Institute, Boston, Mass. Recipient of a Certificate of Merit award for an education exhibit at the 2012 RSNA Annual Meeting. Received February 5, 2013; revision requested March 8 and received April 1; accepted May 3. For this SA-CME activity, C.S.G. has disclosed financial relationships (see p 2016); the other authors, editor, and reviewers have no relevant relationships to disclose.

Address correspondence to E.D.Y. (e-mail: eyeh@partners.org).

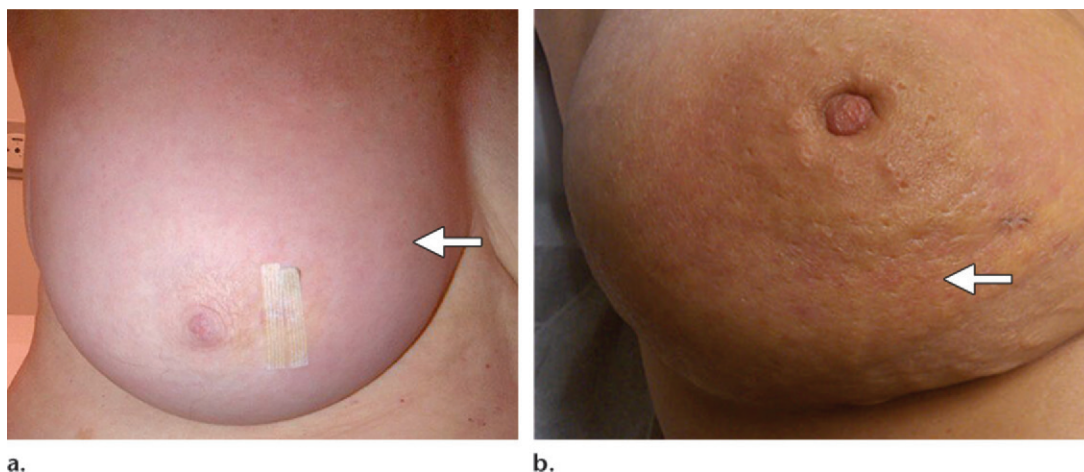


Figure 1. Clinical features of IBC. **(a)** Photograph of the right breast in a 72-year-old woman shows diffuse erythema (arrow) and edema. Breast and skin biopsies demonstrated invasive breast cancer and adenocarcinoma in the dermal lymphatics. **(b)** Photograph of the right breast in a 49-year-old woman shows breast erythema and peau d'orange (arrow). Breast and skin punch biopsies demonstrated invasive ductal carcinoma and invasive carcinoma in the deep and superficial dermis.

This article discusses the clinical presentation of patients with IBC, the major differential diagnoses, and the critical role of imaging in treatment of patients with IBC. Imaging is used to help diagnose IBC, direct biopsy, stage and restage disease, plan chemotherapy, assess therapeutic response, plan surgery and radiation therapy, and detect recurrence.

The Dana-Farber Cancer Institute has established the Inflammatory Breast Cancer Program to emphasize and optimize multidisciplinary care of patients with IBC. The treatment team includes medical, surgical, and radiation oncologists; radiologists; pathologists; oncology nurses; pharmacists; social workers; and nutritionists.

Clinical Presentation

Patients with IBC characteristically present with rapid onset of symptoms that have developed within 3 months (5). Breast erythema and edema, often with no palpable mass, typically may involve one-third or more of the breast (Fig 1a). Another commonly seen clinical finding is *peau d'orange*, a French term meaning “skin of an orange” that describes the pitted, dimpling skin caused by tumor emboli that obstruct the dermal lymphatics (Fig 1b) (6,7). The breast often is enlarged, warm, and tender, symptoms that mimic inflammation, but there is no true inflammatory component to IBC.

At presentation, 20%–40% of patients will have distant metastases, often to the lungs, liver, bone, or brain, a finding that reflects the very aggressive nature of IBC (8).

Differential Diagnosis

The major differential diagnosis for IBC is breast infection, such as mastitis, with or without an abscess. Mastitis often manifests as cutaneous breast erythema, edema with skin thickening, and fever. If a focal lump or skin fluctuance is seen, ultrasonography (US) may be performed to determine whether there is an accompanying abscess. If an abscess is seen at US, prompt percutaneous drainage under clinical or US guidance is necessary to decrease the bacterial load and facilitate recovery with antibiotic treatment, either oral or intravenous depending on the severity of the infection. The most common cause of infectious mastitis is bacterial infection such as *Staphylococcus aureus*, *Staphylococcus epidermidis*, or *Streptococcus*. Other rare causes include anaerobic infection or granulomatous disease such as tuberculosis. If abscess drainage is performed, the aspirate should be sent for Gram stain and culture (aerobic and anaerobic) so that antibiotic treatment can be tailored to the specific organism.

If there is no response or an incomplete response to antibiotic treatment within 1–2 weeks, malignancy such as IBC should be considered. **Both tissue diagnosis of malignancy and clinical evidence of inflammatory disease are required to confirm the diagnosis of IBC.** Figure 2 is an example of a patient with high clinical suspicion for IBC who underwent multiple biopsies that were negative for malignancy. She was diagnosed with a left breast abscess that resolved after prolonged antibiotic therapy.

The differential diagnosis also may include non-IBC locally advanced breast cancer (LABC).

Teaching Point

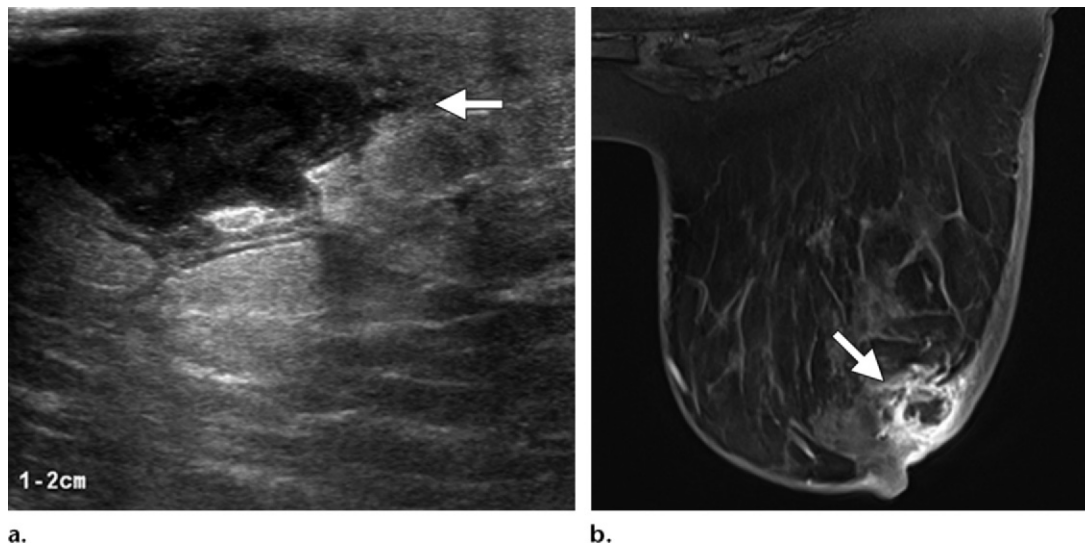


Figure 2. Breast abscess in a 50-year-old woman with erythema and peau d'orange in the left breast and high clinical suspicion for IBC. **(a)** Longitudinal US image of the subareolar region shows skin thickening, edema, and a 2.8-cm hypoechoic mass at the 4-o'clock position (arrow). **(b)** Axial dynamic postcontrast magnetic resonance (MR) image shows skin thickening, edema, and a 2.8-cm rim-enhancing mass (arrow). Enlarged lymph nodes also were seen. Two US-guided core biopsies and a skin punch biopsy were negative for malignancy. Because of high clinical suspicion for IBC, the patient underwent surgical biopsy that demonstrated benign breast parenchyma with chronic inflammation, fat necrosis, and fibrosis, findings consistent with breast abscess. Gram stain, culture, and acid-fast bacillus stain were negative. The abscess completely resolved after 2 months of antibiotic therapy.

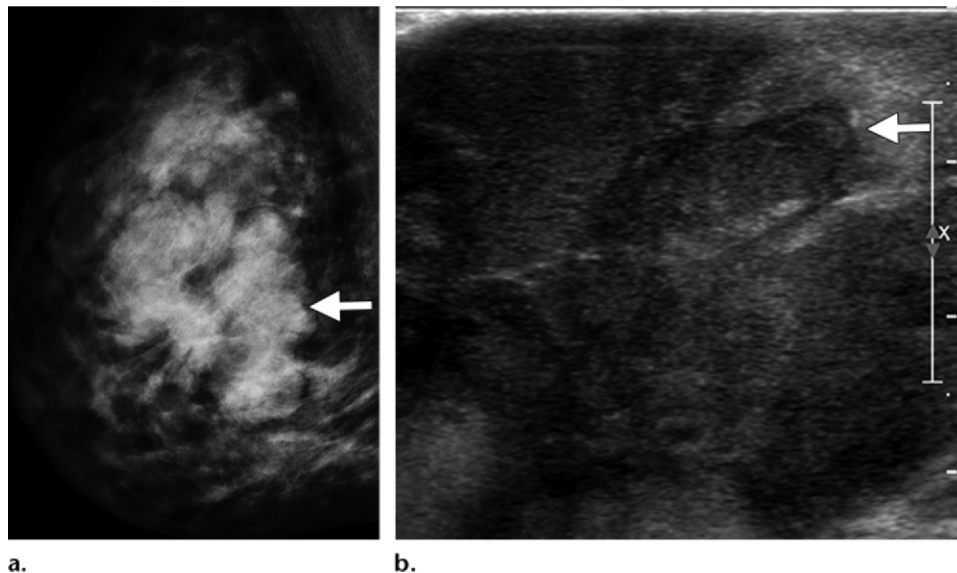


Figure 3. LABC in the right breast in a 35-year-old woman who had noted a lump in the same breast 2 years previously. The mass subsequently enlarged and began protruding through the skin. **(a)** Mediolateral oblique mammogram shows a 7-cm mass (arrow) in the upper inner breast. **(b)** Longitudinal US image shows a 7 × 4-cm mass at the 2-o'clock position (arrow). US-guided core biopsy demonstrated high-grade invasive ductal carcinoma. The patient underwent neoadjuvant chemotherapy and subsequent mastectomy.

Teaching Point

The key feature that differentiates IBC from non-IBC LABC is the onset of symptoms. Symptoms of IBC develop within 3 months or less, whereas symptoms of non-IBC LABC typically develop over a more protracted period. Figure 3

is an example of a patient with non-IBC LABC whose symptoms developed for 2 years before presentation.

Characteristics of Primary IBC and LABC

Characteristic	IBC	LABC
Clinical presentation	Rapid onset of signs and symptoms within 3 months Erythema and edema (peau d'orange) Younger age at diagnosis (average age, 58 y) Grows and spreads quickly 20%–40% risk of distant metastases at diagnosis	Longer onset of symptoms No erythema or edema Older age at diagnosis (average age, 66 y) Slower progression 10% risk of distant metastases at diagnosis
Molecular characteristics	More proliferative intrinsic subtypes (40% HER2 positive, up to 50% triple negative) >60% mutated p53 tumor suppressor gene Two gene alterations: overexpression of RhoC and loss of WISP3, leading to increased tumor invasion and metastases Increased angiogenesis High VEGF, the most potent stimulator of tumor angiogenesis e-cadherin and dysfunctional MUC-1 are overexpressed, which accounts for emboli formation and increased metastases	More favorable subtypes (more ER positive and HER2 negative subtypes) 30% mutated p53 tumor suppressor gene
Prognosis	2-year breast cancer–specific survival rate = 84%	2-year breast cancer–specific survival rate = 91%

Note.—ER = estrogen receptor, HER2 = human epidermal growth factor receptor 2, VEGF = vascular endothelial growth factor.

Differentiating Primary IBC from LABC

Primary IBC has a different clinical manifestation, different molecular characteristics, and a different prognosis than LABC (Table). IBC typically has a rapid onset of classic symptoms, manifests in a younger patient population (average age at diagnosis, 58 years), grows and spreads quickly, and is associated with a 20%–40% rate of distant metastases at presentation (1). In contrast, non-IBC LABC has a longer course of onset, manifests in an older patient population (average age at diagnosis, 66 years), progresses more slowly, and has a 10% rate of distant metastases at presentation. When non-IBC LABC enlarges or is located more superficially within the breast, it may involve the skin and cause secondary erythema and skin induration, symptoms that mimic the classic characteristics of IBC. Skin biopsy results often cannot differentiate the two forms of breast cancer. Dermal lymphatic invasion also can occur in other stages of breast cancer.

The molecular characteristics of IBC differ from those of LABC. IBC is associated with the

more proliferative intrinsic molecular subtypes of breast cancer, with 40% of tumors HER2 positive and up to 50% of tumors triple negative (ER negative, progesterone receptor [PR] negative, and HER2 negative) (9). In contrast, non-IBC LABC often is associated with more favorable molecular subtypes, such as ER positive and HER2 negative tumors. IBC has more than 60% mutated p53 tumor suppressor gene, while LABC has 30% mutated p53 gene (10). In IBC, two genes are concordantly altered: there is overexpression of RhoC and loss of WISP3, leading to increased tumor invasion and metastases (11). Increased angiogenesis is seen in IBC and correlates with a high level of vascular endothelial growth factor, which is the most potent stimulator of tumor angiogenesis (12–16). E-cadherin and dysfunctional MUC-1 are overexpressed in IBC and contribute to formation of tumor emboli and increased metastases (17).

Patients with IBC have a poorer prognosis than those with non-IBC LABC. The 2-year breast cancer–specific survival rate is 84% for patients with IBC compared with 91% for those with LABC (18).

Because of the differences between IBC and non-IBC LABC and to improve prognosis for patients with IBC, increased emphasis has been

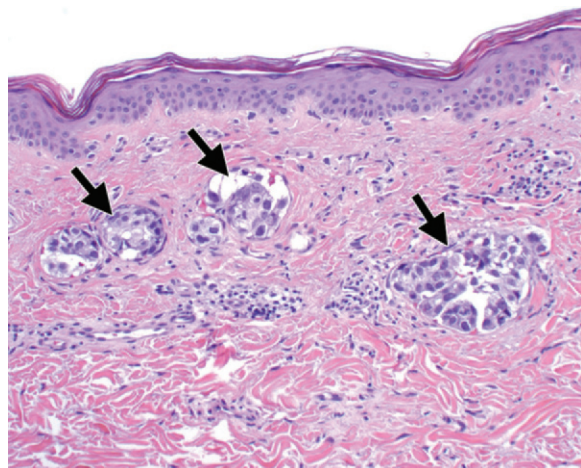


Figure 4. Pathologic correlate of clinical findings of breast erythema and edema in a patient with IBC. Photomicrograph (original magnification, $\times 40$; hematoxylin-eosin stain) of a specimen from skin punch biopsy shows tumor emboli (arrows) in the dermal lymphatics. (Courtesy of Dr Susan Lester.)

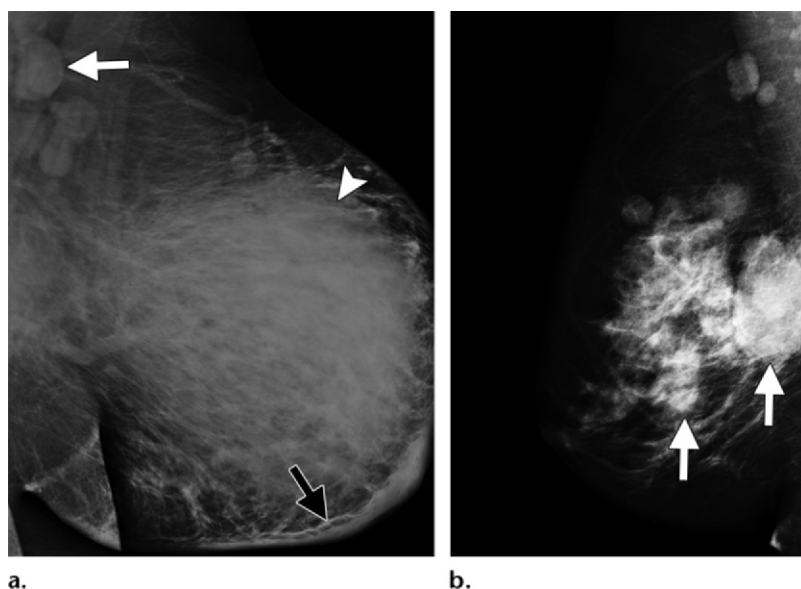


Figure 5. Mammographic appearance of IBC. **(a)** Mediolateral oblique mammogram of the left breast in a 37-year-old woman shows diffuse breast enlargement, diffuse increased density (arrowhead), skin thickening (black arrow), and enlarged axillary lymph nodes (white arrow). US-guided core biopsy demonstrated poorly differentiated invasive ductal carcinoma. **(b)** Mediolateral oblique mammogram of the right breast in a 49-year-old woman shows multiple large masses (arrows), a finding less commonly seen in IBC. US-guided core biopsy demonstrated poorly differentiated invasive ductal carcinoma.

placed on developing molecularly targeted therapy specific for IBC.

Skin Punch Biopsy

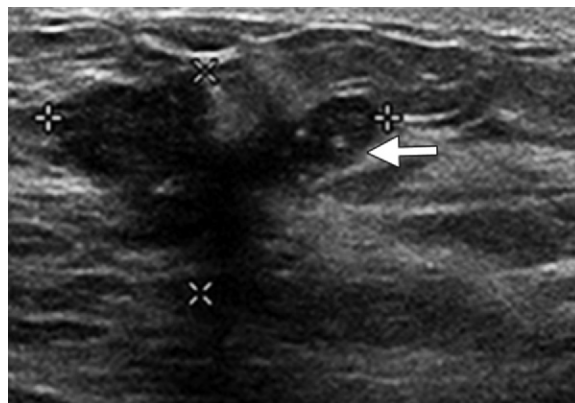
The pathologic hallmark of IBC is dermal lymphatic involvement (6,7). Tumor emboli in the papillary and reticular dermis of the skin are the direct cause of the clinical characteristics of inflammatory carcinoma. Carcinoma blocks the lymphatics and causes breast edema and erythema. Although these skin changes mimic inflammation, there is no true inflammation. Skin punch biopsy may be performed by a dermatologist or surgeon. The results are positive for malignancy in approximately 75% of patients, but skin punch biopsy is not required for diagnosis. Figure 4 provides an example of pathologic findings from skin punch biopsy in a patient with IBC.

Role of Imaging in Diagnosis of IBC

Typical Mammographic Appearance

The typical mammographic appearance of IBC includes diffuse enlargement of the breast, stromal coarsening, diffuse increased density, skin thickening, and enlarged lymph nodes (Fig 5a) (19,20). Mammographic findings are classified according to the American College of Radiology Breast Imaging Reporting and Data System (BI-RADS) lexicon (21). Less commonly seen mammographic features of IBC are multiple masses, pleomorphic calcifications, or architectural distortion (Fig 5b).

Figure 6. US findings used to differentiate and characterize a mass in the left breast in a 30-year-old woman with clinical suspicion for IBC. Transverse US image shows a 2.7-cm, irregular, hypoechoic mass with posterior shadowing at the 1:30 position (arrow). Pathologic analysis demonstrated poorly differentiated invasive ductal carcinoma.



US for Pretreatment Workup

US can be used in the initial diagnostic workup for patients with clinical suspicion for IBC. If a discrete lump, focal erythema, or edema is found at physical examination or a mass is seen at mammography, US can help differentiate a benign cystic mass from a solid mass and characterize a solid mass according to the BI-RADS lexicon (21). At US, mass margins are evaluated as smooth, irregular, or spiculated, and the size and extent of the mass are reported (Fig 6).

Most importantly, US can identify the biopsy target and guide percutaneous core biopsy. At US-guided core biopsy, a clip is routinely placed to mark the biopsy location. Although patients with IBC will undergo mastectomy as standard surgical treatment, our pathologists find clip placement helpful to localize the tumor when assessing postchemotherapy tumor response, a factor that impacts prognosis (22,23). Mammography is performed after clip placement to document clip location. Mammograms also provide a baseline to assess tumor response and are useful for surgical planning.

MR Imaging

MR imaging may be helpful for initial diagnosis of IBC and to document the extent of disease in the incident breast and occult disease in the contralateral breast. MR images also provide a baseline for comparison with subsequent follow-up images to assess treatment response.

Diagnosis of IBC using conventional imaging modalities such as mammography and US may be challenging because the characteristic disease features of diffuse increased density, stromal coarsening, and skin thickening resemble the inflammatory changes of mastitis.

Because tissue diagnosis of malignancy is required to confirm IBC, the most appropriate target for biopsy should be selected to avoid a false-negative result and subsequent delay in diagnosis. MR imaging is the most accurate imaging technique for detection of the primary breast lesion in patients with IBC (24,25). The primary breast lesion is detected at mammography in 68%–80% of cases, at US in 94%–95% of cases, and at MR imaging in 98%–100% of cases. **If a mass or biopsy target is not detected at conventional imaging, MR imaging can help identify a biopsy target to confirm the diagnosis of IBC** (Fig 7).

Common findings of IBC on contrast-enhanced MR images are extensive or segmental nonmasslike enhancement and diffuse skin thickening (Fig 8) (20,25–27). MR imaging findings are classified according to the BI-RADS lexicon (21). A mass with irregular or spiculated margins may manifest with adjacent satellites, multiple masses, or nonmasslike enhancement (24,25). Kinetics typically show initial rapid enhancement with washout or plateau curves (24). Because there usually is extensive tumor involvement of the breast, tumor size may be difficult to measure with any imaging modality.

MR imaging findings of extraparenchymal disease include pectoralis muscle enhancement or tethering and loss of the prepectoral fat plane, which indicate possible tumor involvement of muscle. Lymphadenopathy may be seen in the axillary, subpectoral, interpectoral (Rotter node), supraclavicular, or internal mammary nodes. Because IBC involves rapid spread of tumor throughout the breast, extensive tumor typically is seen in the affected breast at MR imaging, and mastectomy is the standard surgical treatment. The contralateral breast should be checked for suspicious masses or nonmasslike enhancement. Because of the high incidence of metastases at

Teaching Point

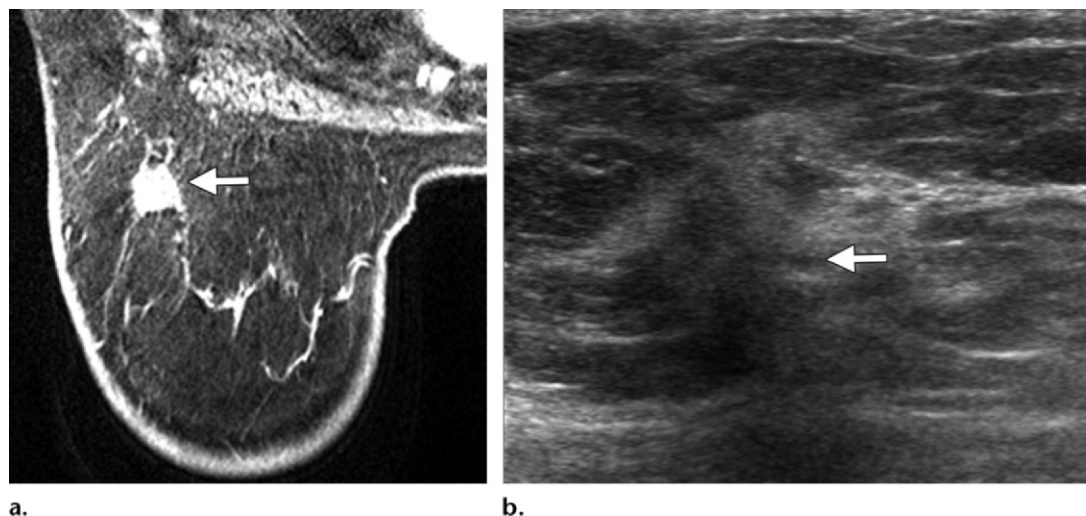


Figure 7. Mass found at MR imaging after mammography and US showed no discrete mass or biopsy target in a 72-year-old woman with edema and erythema in the right breast. **(a)** Axial postcontrast MR image shows a spiculated 1-cm mass (arrow) in the upper outer breast, a finding suspicious for malignancy. Washout kinetics are seen. **(b)** Targeted US image after MR imaging shows a 1-cm irregular mass (arrow) at the 10-o'clock position. US-guided core biopsy demonstrated invasive carcinoma.

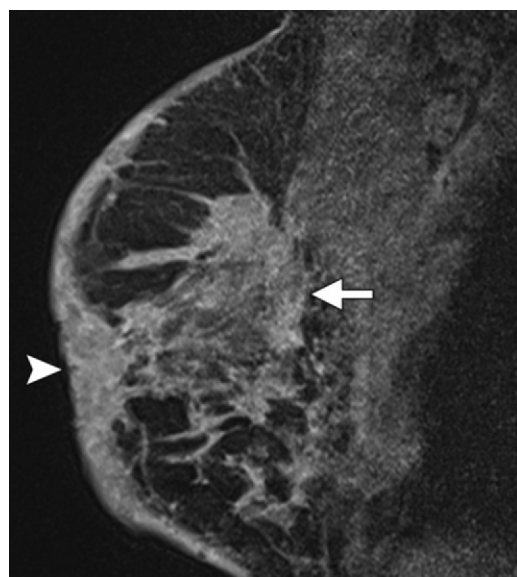


Figure 8. Common MR imaging appearance of IBC. Sagittal postcontrast MR image of the right breast in a 52-year-old woman newly diagnosed with IBC shows extensive nonmasslike enhancement (arrow), skin thickening, and nipple retraction (arrowhead).

edema and prepectoral or intramuscular pectoral edema; diffuse cutaneous or subcutaneous and prepectoral high signal intensity on T2-weighted images indicating edema may increase the specificity for IBC (27,28).

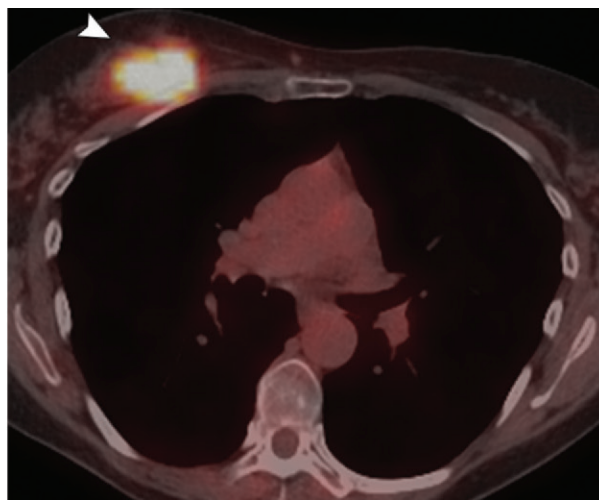
PET/CT with Fluorine-18 Fluorodeoxyglucose for Initial Staging

Because of the high likelihood of metastases at diagnosis, positron emission tomography (PET)/computed tomography (CT) with fluorine-18 (^{18}F) fluorodeoxyglucose (FDG) can be extremely beneficial in the initial evaluation and staging of IBC (29,30). FDG PET/CT can be used to detect the primary breast lesion; skin and ipsilateral axillary lymph node involvement; and additional regional lymph node involvement in the subpectoral, infraclavicular, and supraclavicular regions (24,31–34). Additionally, the internal mammary lymph nodes are detected at FDG PET/CT in approximately 25% of patients with IBC (33,34). Accurate definition of the extent of lymph node involvement aids in radiation therapy planning (35).

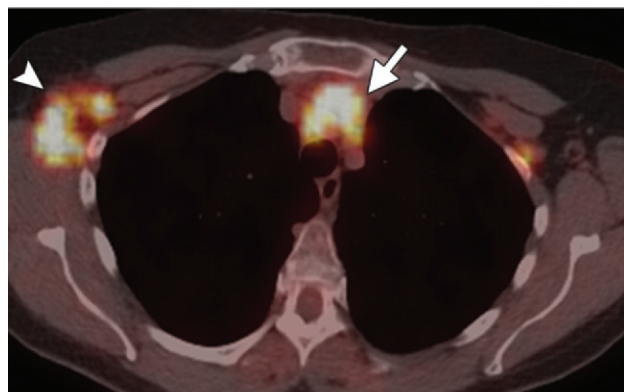
diagnosis, the MR imaging field should include the liver; lungs; bone; and distant lymph nodes in the neck, mediastinum, and abdomen. Distant abnormalities typically require directed imaging for confirmation and possible biopsy.

MR imaging findings of IBC differ from those of LABC as follows: nonmasslike enhancement (73% for IBC versus 40% for LABC), skin thickening (53% versus 27%), skin edema (87% versus 27%), and skin enhancement (33% versus 7%) (26). Additional imaging findings that occur more frequently with IBC than LABC include diffuse

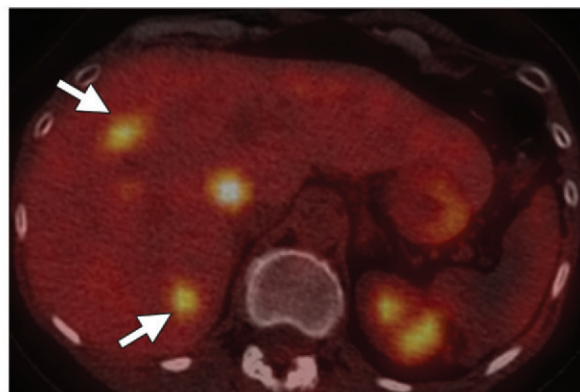
Figure 9. FDG PET/CT used to stage IBC and detect unexpected distant metastases. FDG PET/CT images in a 59-year-old woman show FDG uptake in the right breast (arrowhead in **a**), mediastinum (arrow in **b**), and axilla (arrowhead in **b**) and multiple hepatic metastases (arrows in **c**). FDG uptake also was seen in the neck.



a.



b.



c.

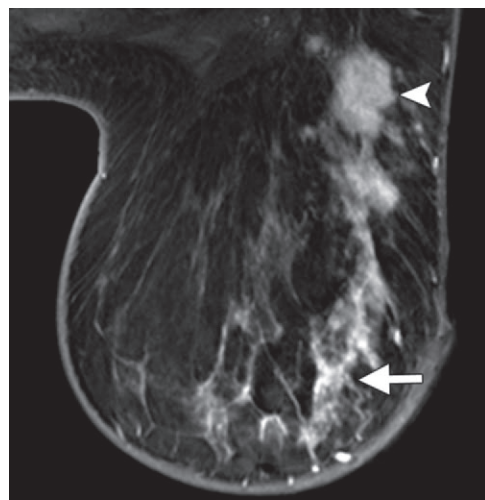
Another advantage of FDG PET/CT for initial staging of IBC is its accuracy in detecting unexpected distant metastases (Fig 9) (33,34). In a recent study of 35 patients with IBC, bone was the most common site of distant metastasis, and FDG PET/CT was more accurate than skeletal scintigraphy for detection (34). At FDG PET/CT, bone and soft tissue can be evaluated in a single imaging session.

Imaging Studies to Assess Treatment Response

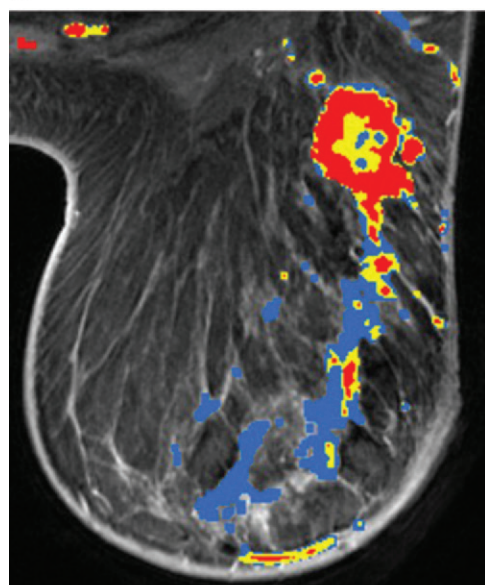
After diagnosis of IBC, research core biopsies may be performed at our institution at baseline, during treatment, and after treatment before surgery. Research core biopsies typically are US-guided core biopsies of the known malignancy. Samples are collected to study molecular markers and clinical correlation, including treatment response. Clinical, imaging, pathologic, molecular, and genetic correlations also may be performed.

Other conventional imaging studies that may be performed during treatment include follow-up mammography, US, and MR imaging. If a discrete mass or pleomorphic calcifications are seen at initial mammography, follow-up mammography may be used to assess treatment response. If a mass is identified at initial US, follow-up US may be used to assess changes in mass size as an indicator of treatment response.

MR imaging is the best imaging modality for assessment of local response to treatment because of the high sensitivity of MR imaging studies, the extensive initial disease burden, and the possibility of associated findings. In a study of 24 patients with IBC by Shin et al (36), MR imaging showed the best overall agreement between midtreatment response ($\kappa = 0.71$ for MR imaging, 0.37 for US, 0.27 for mammography, 0.23 for clinical examination) and final predicted response ($\kappa = 0.82$ for MR imaging, 0.62 for US, 0.42 for mammography, 0.44 for clinical examination) versus pathologic response. In a retrospective review of 24 patients with IBC, Chen et al (37) cautioned that MR imaging had

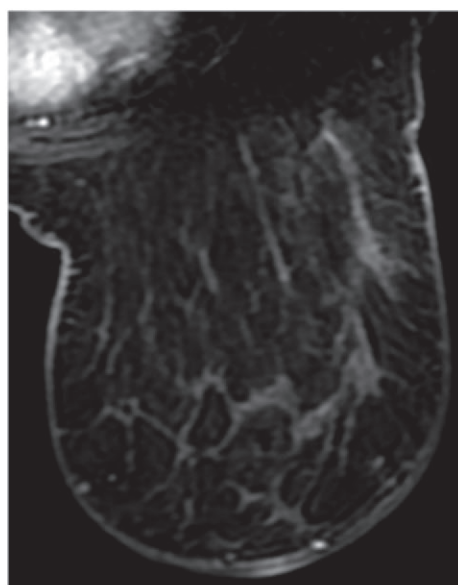


a.



b.

Figure 10. MR imaging used to evaluate treatment response in a 49-year-old woman with IBC in the left breast. **(a)** Pretreatment axial dynamic postcontrast MR image shows an irregular 1.9-cm mass (arrowhead) with adjacent extensive segmental nonmasslike enhancement (arrow) extending to the nipple. Associated skin thickening is seen. **(b)** Pretreatment angiographic color map shows washout (red) kinetics in the mass and nonmasslike enhancement with washout and plateau (blue) kinetics. **(c)** Axial dynamic postcontrast MR image after chemotherapy shows resolution of both the mass and nonmasslike enhancement. Complete pathologic response was seen at mastectomy.



c.

a high false-negative rate (five of 24 cases, 21%) for complete response compared with pathologic response, particularly for non-mass-type lesions, which accounted for four of the five false-negative cases.

When IBC responds to neoadjuvant chemotherapy, posttherapy MR images may show decreased size or resolution of the primary mass, satellites, and nonmasslike enhancement, often with a corresponding decrease in lymphadenopathy (Fig 10). Skin thickening may decrease or may persist because of damaged lymphatics. With stable or progressive disease, MR imaging will show no change in tumor size or an increase in tumor size, respectively. Treatment response can be assessed according to previously published methods and the Response Evaluation Criteria in Solid Tumors (RECIST) 1.1 criteria (36–39).

FDG PET/CT to Monitor Treatment Response

FDG PET/CT is helpful to assess treatment response, including local response and metastatic disease (Fig 11). A 50% decline in FDG uptake in the primary tumor is predictive of a good response to neoadjuvant chemotherapy (40). Less than a 50% decline or no decline in FDG uptake is characteristic of a nonresponding tumor. FDG PET/CT could, therefore, serve as a noninvasive quantitative biomarker for treatment efficacy. Studies have shown that FDG PET/CT used early in the course of therapy can provide early assessment of treatment response and help predict subsequent pathologic response (41).

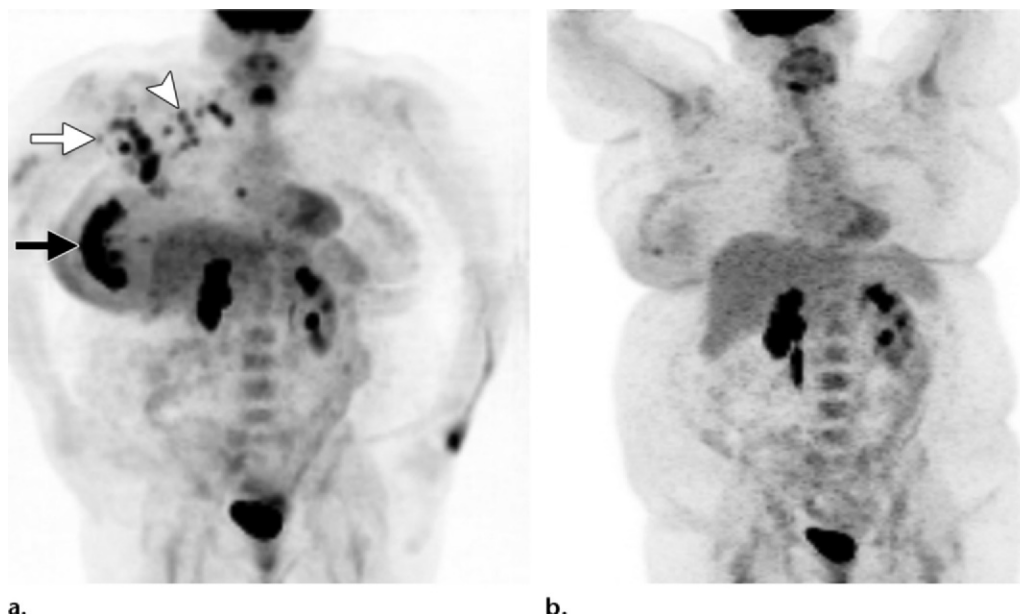


Figure 11. FDG PET/CT used to modify radiation fields and monitor treatment response in a 43-year-old woman with IBC. **(a)** Pretreatment FDG PET/CT image shows extensive FDG avidity, including a large multilobulated mass in the right breast (black arrow) with skin thickening and increased FDG uptake in the axilla (white arrow); subpectoral, supraclavicular (arrowhead), and internal mammary nodes; and back muscles (scapularis). The metastases were not seen at initial MR imaging. **(b)** Follow-up FDG PET/CT image after neoadjuvant chemotherapy shows significant interval decrease in the intensity and extent of FDG uptake in the right breast mass, nodes, and back muscles.

How Imaging Helps the Oncologist

Preoperative chemotherapy is the standard of care for patients with IBC. It controls systemic disease, optimizes treatment of local-regional disease, and renders inoperable IBC operable. Patients with a HER2-positive tumor receive preoperative trastuzumab therapy in addition to chemotherapy.

Imaging is used to stage IBC, differentiate between curable and incurable (stage IV) disease, and help the oncologist choose the appropriate chemotherapy agent. In the American Joint Commission on Cancer Staging staging system, IBC tumor size is classified as T4d, so IBC is at least stage IIIB at diagnosis (42). IBC also can be stage IIIB (T4, N0–N2, M0), stage IIIC (any T, N3, M0), or stage IV (any T, any N, M1) at diagnosis.

Posttreatment imaging is used to confirm and quantitate disease response and determine whether further chemotherapy is necessary and

whether surgery can proceed. If imaging shows poor treatment response or disease progression, the oncologist may opt to change chemotherapeutic agents. If no metastases are seen at posttreatment imaging, a contralateral mammogram is performed annually. If metastases are seen, ongoing imaging is performed to assess disease response.

How Imaging Helps the Surgeon

Modified radical mastectomy is the standard of care for patients with stage III IBC (43). Accurate prediction of residual tumor burden after preoperative chemotherapy is helpful for surgical planning. Clinical assessment of disease response (resolution of breast edema and erythema) determines the appropriate timing of mastectomy. Persistent skin changes (peau d'orange or erythema) suggest residual disease and a low likelihood of clean surgical margins or tension-free skin closure. However, persistent skin changes may result from damaged lymphatic drainage even with adequate treatment response. In this setting, imaging plays a part in determining therapeutic response.

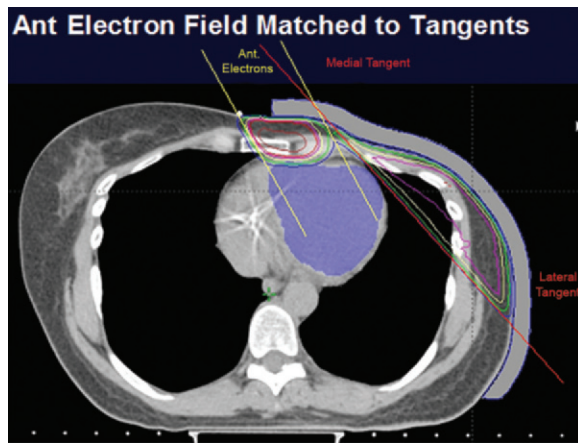


Figure 12. Postmastectomy radiation therapy portals in a patient with IBC. Axial CT image with color overlays shows radiation dose distribution when shallow tangential fields are matched to an anterior (*Ant*) angled electron field. This configuration allows heart sparing when the heart is in close proximity to the treatment area. Yellow lines = 95% of prescribed radiation dose.

Palliative surgery may be appropriate for patients with stage IV IBC who experience an excellent systemic and local regional response to initial chemotherapy. Surgeons rely on findings from systemic imaging over time when considering the timing of surgery for these patients. Overall, the role of definitive local therapy (surgery and postmastectomy radiation) in treatment of patients with any stage IV disease, including IBC, is controversial. Definitive local therapy or separate therapeutic components (surgery or radiation alone) may be reasonable options in cases with more favorable disease biology or better therapeutic targets, such as ER positive or HER2 positive tumors.

Immediate breast reconstruction after mastectomy is strongly discouraged. There is a sense of urgency to complete oncologic therapy for highly locally aggressive IBC and ensure that postmastectomy radiation occurs approximately 4–6 weeks after surgery, and immediate breast reconstruction may produce healing delays. Furthermore, because of extensive skin involvement at presentation, IBC precludes skin-sparing mastectomy and makes immediate reconstruction highly challenging. Patients with IBC may undergo delayed reconstruction, which usually involves autologous tissue, 6 months or more after postmastectomy radiation therapy. Implant-based reconstruction is discouraged for patients who have undergone chest wall radiation.

Simultaneous contralateral prophylactic mastectomy is strongly discouraged. It does not improve survival rates and may delay treatment of the primary cancer (IBC) if there are surgery-related complications of the contralateral mastectomy.

How Imaging Helps the Radiation Oncologist

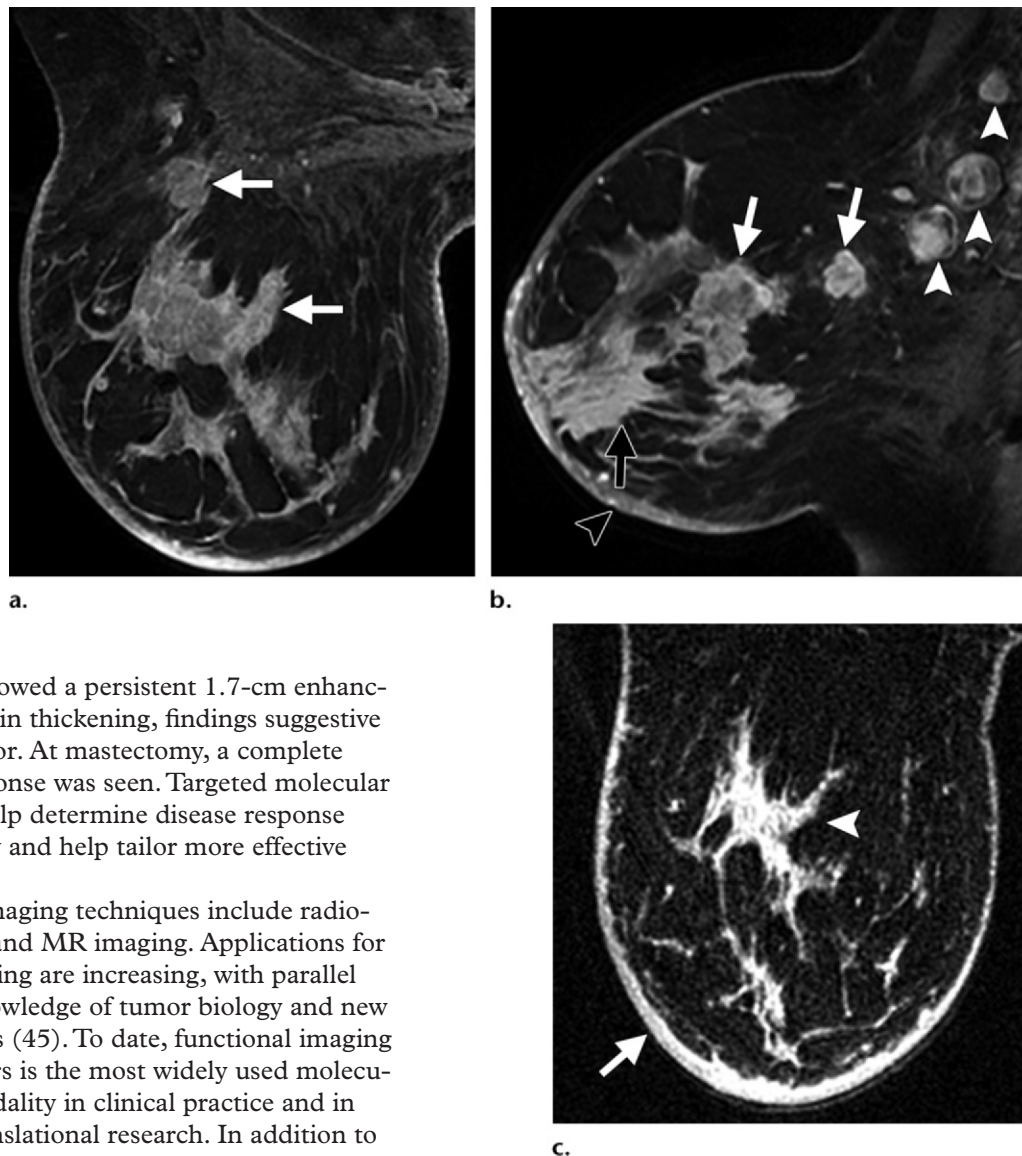
Imaging helps determine the extent and location of the primary tumor as well as involvement of nonpalpable regional lymph nodes and helps in tumor staging. If there is no metastatic disease, the standard of care is for all patients with IBC to undergo radiation therapy after mastectomy (44). Standard radiation fields include the chest wall and supraclavicular and infraclavicular regions and often the axillary and internal mammary lymph nodes.

Imaging findings may lead to modification of the radiation fields. For example, for the patient shown in Figure 11, FDG uptake in the internal mammary nodes and scapularis at PET/CT demonstrated metastases not initially seen at MR or other imaging because of large patient body habitus, difficulty of patient positioning, and poor fat suppression. The more extensive disease burden seen at FDG PET/CT warranted extension of the postsurgical radiation fields. Figure 12 provides an example of postmastectomy radiation portals in a patient with IBC. Some patients with metastatic IBC may benefit from local disease control (mastectomy or radiation therapy).

Role of Molecular Imaging

Because IBC may alter dermal lymphatics, patients often have persistent skin thickening or erythema at posttreatment clinical examination or anatomic imaging, even in the absence of disease. Figure 13 shows a patient with extensive disease seen at initial MR imaging. Posttreatment

Figure 13. MR imaging findings suggestive of posttreatment residual tumor in a 49-year-old woman with IBC. **(a)** Axial dynamic postcontrast MR image of the right breast before chemotherapy shows multiple enhancing masses (arrows). **(b)** Sagittal delayed postcontrast MR image before chemotherapy shows multiple enhancing masses (white arrows), nonmasslike enhancement (black arrow), skin thickening (black arrowhead), and multiple enlarged axillary lymph nodes (white arrowheads). **(c)** Axial dynamic postcontrast MR image after neoadjuvant chemotherapy shows significant improvement, with a residual 1.7-cm enhancing mass (arrowhead), residual skin thickening (arrow), and resolution of adenopathy (not shown). Complete pathologic response was seen at mastectomy.



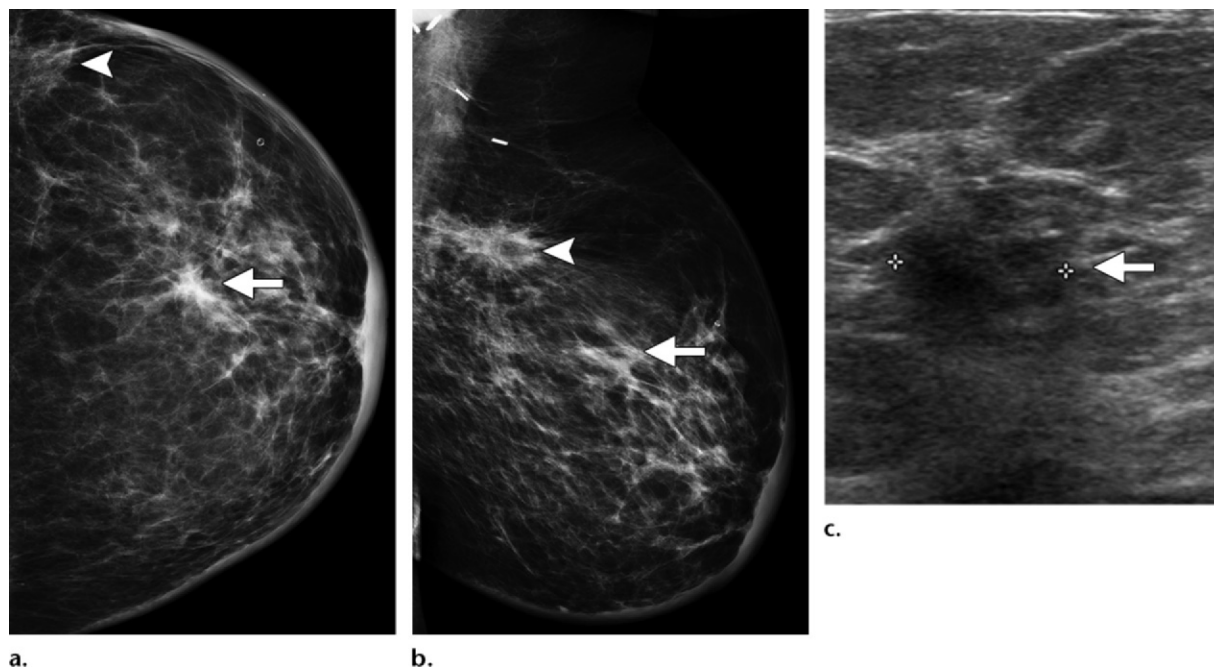
MR imaging showed a persistent 1.7-cm enhancing mass and skin thickening, findings suggestive of residual tumor. At mastectomy, a complete pathologic response was seen. Targeted molecular imaging may help determine disease response more accurately and help tailor more effective treatment.

Molecular imaging techniques include radio-tracer, optical, and MR imaging. Applications for molecular imaging are increasing, with parallel advances in knowledge of tumor biology and new drug discoveries (45). To date, functional imaging with radiotracers is the most widely used molecular imaging modality in clinical practice and in clinical and translational research. In addition to FDG, PET radiotracers and their biologically relevant targets in breast cancer include ^{18}F -sodium fluoride (NaF) to image osteoblastic activity, ^{18}F -fluoroestradiol (FES) to image the estrogen receptor, zirconium-89 (^{89}Zr)-trastuzumab to image the HER2/neu protein, ^{89}Zr -bevacizumab to image vascular endothelial growth factor, and

^{18}F -dihydrotestosterone (FDHT) to image the androgen receptor.

These tracers have potential use for imaging of IBC because they can help characterize tumors in vivo, quantitate the target, assess drug targeting, determine patient-specific drug dosing from in vivo tumor characteristics and patient-specific ki-

Figure 14. Inflammatory recurrence found at surveillance mammography in the left breast in a 52-year-old woman. The patient had undergone lumpectomy and radiation therapy 7 years previously for triple-negative node-positive cancer in the left breast. **(a, b)** Craniocaudal **(a)** and mediolateral oblique **(b)** mammograms show posttreatment changes (arrowhead) from prior lumpectomy and radiation therapy with new skin thickening and a new mass (arrow). Clips from previous surgery are seen in the axilla in **b**. **(c)** Longitudinal US image shows an irregular, hypoechoic, 1.1-cm mass (arrow) at the 1-o'clock position. US-guided core biopsy demonstrated high-grade, ER and PR negative, HER2/neu negative invasive ductal carcinoma. Skin punch biopsy was positive. Secondary IBC was diagnosed, and the patient underwent chemotherapy and mastectomy.



netics, and assess response to targeted therapies. Inclusion of molecular imaging in the management schema for IBC could lead to more optimal drug therapy for patients and new drug and regimen development.

Imaging for Recurrence, Restaging, and Metastases

Follow-up Imaging

Follow-up imaging after trimodality treatment of IBC includes annual mammography to detect new contralateral breast cancer. Systemic staging studies such as CT or PET scans of the chest, abdomen, and pelvis typically are performed only for stage IV disease or to evaluate specific symptoms.

Secondary IBC

Secondary IBC is an inflammatory recurrence of noninflammatory primary breast cancer; that is, a recurrence of breast cancer that manifests with classic IBC characteristics in the treated breast

of a patient with previous non-IBC breast cancer (Fig 14) (6,7). The natural history of secondary IBC is similar to that of primary IBC.

Prognosis and Significance

Patients who complete all three treatment modalities (neoadjuvant chemotherapy, modified radical mastectomy, and radiation therapy) have a significantly better outcome than patients who do not complete treatment (46). **If imaging is used to noninvasively predict treatment response early during the course of therapy, more optimal and tailored management strategies for patients with IBC can be implemented.** In patients with metastatic disease, treatment goals are to prolong life, optimize quality of life, and control local disease. The pathogenesis and highly virulent course of IBC underscore the need to understand its molecular mechanisms and focus on clinical trials that use novel targeting agents.

Teaching Point

Summary

Imaging is vital to diagnosis and treatment planning for patients with IBC. This article describes the imaging features of IBC at mammography, US, MR imaging, and FDG PET/CT. Radiologists should understand the role of various imaging modalities in diagnosis, assessment of treatment response, and surveillance. Radiologists play an integral role as part of the multidisciplinary team caring for patients with IBC.

Acknowledgment.—Special thanks to Nora McCarthy for her invaluable assistance with the image preparation.

Disclosure of Conflicts of Interest.—**C.S.G.:** *Related financial activities:* none. *Other financial activities:* program reviewer for American College of Radiology Mammography Accreditation; lecturer for National Diagnostic Imaging Symposium, Kaiser-Permanente, and New York Breast Imaging Society.

References

- Hance KW, Anderson WF, Devesa SS, Young HA, Levine PH. Trends in inflammatory breast carcinoma incidence and survival: the surveillance, epidemiology, and end results program at the National Cancer Institute. *J Natl Cancer Inst* 2005;97(13):966–975.
- Overmoyer BA. Inflammatory breast cancer: novel preoperative therapies. *Clin Breast Cancer* 2010;10(1):27–32.
- Robertson FM, Bondy M, Yang W, et al. Inflammatory breast cancer: the disease, the biology, the treatment. *CA Cancer J Clin* 2010;60(6):351–375.
- Ueno NT, Buzdar AU, Singletary SE, et al. Combined-modality treatment of inflammatory breast carcinoma: twenty years of experience at M.D. Anderson Cancer Center. *Cancer Chemother Pharmacol* 1997;40(4):321–329.
- Dawood S, Merajver SD, Viens P, et al. International expert panel on inflammatory breast cancer: consensus statement for standardized diagnosis and treatment. *Ann Oncol* 2011;22(3):515–523.
- Walshe JM, Swain SM. Clinical aspects of inflammatory breast cancer. *Breast Dis* 2005-2006;22:35–44.
- Yamauchi H, Woodward WA, Valero V, et al. Inflammatory breast cancer: what we know and what we need to learn. *Oncologist* 2012;17(7):891–899.
- Dawood S, Ueno NT, Valero V, et al. Identifying factors that impact survival among women with inflammatory breast cancer. *Ann Oncol* 2012;23(4):870–875.
- Bertucci F, Finetti P, Rougemont J, et al. Gene expression profiling identifies molecular subtypes of inflammatory breast cancer. *Cancer Res* 2005;65(6):2170–2178.
- Turpin E, Bièche I, Bertheau P, et al. Increased incidence of ERBB2 overexpression and TP53 mutation in inflammatory breast cancer. *Oncogene* 2002;21(49):7593–7597.
- van Golen KL, Davies S, Wu ZF, et al. A novel putative low-affinity insulin-like growth factor-binding protein, LIBC (lost in inflammatory breast cancer), and RhoC GTPase correlate with the inflammatory breast cancer phenotype. *Clin Cancer Res* 1999;5(9):2511–2519.
- Van der Auwera I, Van Laere SJ, Van den Eynden GG, et al. Increased angiogenesis and lymphangiogenesis in inflammatory versus noninflammatory breast cancer by real-time reverse transcriptase-PCR gene expression quantification. *Clin Cancer Res* 2004;10(23):7965–7971.
- Colpaert CG, Vermeulen PB, Benoy I, et al. Inflammatory breast cancer shows angiogenesis with high endothelial proliferation rate and strong E-cadherin expression. *Br J Cancer* 2003;88(5):718–725.
- Kleer CG, van Golen KL, Merajver SD. Molecular biology of breast cancer metastasis: inflammatory breast cancer—clinical syndrome and molecular determinants. *Breast Cancer Res* 2000;2(6):423–429.
- Bièche I, Lerebours F, Tozlu S, Espie M, Marty M, Lidereau R. Molecular profiling of inflammatory breast cancer: identification of a poor-prognosis gene expression signature. *Clin Cancer Res* 2004;10(20):6789–6795.
- Shirakawa K, Shibuya M, Heike Y, et al. Tumor-infiltrating endothelial cells and endothelial precursor cells in inflammatory breast cancer. *Int J Cancer* 2002;99(3):344–351.
- Alpaugh ML, Tomlinson JS, Kasraeian S, Barsky SH. Cooperative role of E-cadherin and sialyl-Lewis X/A-deficient MUC1 in the passive dissemination of tumor emboli in inflammatory breast carcinoma. *Oncogene* 2002;21(22):3631–3643.
- Dawood S, Ueno NT, Valero V, et al. Differences in survival among women with stage III inflammatory and noninflammatory locally advanced breast cancer appear early: a large population-based study. *Cancer* 2011;117(9):1819–1826.
- Tardivon AA, Viala J, Corvellec Rudelli A, Guinebretiere JM, Vanel D. Mammographic patterns of inflammatory breast carcinoma: a retrospective study of 92 cases. *Eur J Radiol* 1997;24(2):124–130.
- Chow CK. Imaging in inflammatory breast carcinoma. *Breast Dis* 2005-2006;22:45–54.

21. American College of Radiology. ACR Breast Imaging and Reporting Data System (BIRADS): breast imaging atlas. 4th ed. Reston, Va: American College of Radiology, 2003.
22. Untch M, Fasching PA, Konecny GE, et al. Pathologic complete response after neoadjuvant chemotherapy plus trastuzumab predicts favorable survival in human epidermal growth factor receptor 2-over-expressing breast cancer: results from the TECHNO trial of the AGO and GBG study groups. *J Clin Oncol* 2011;29(25):3351–3357.
23. Symmans WF, Peintinger F, Hatzis C, et al. Measurement of residual breast cancer burden to predict survival after neoadjuvant chemotherapy. *J Clin Oncol* 2007;25(28):4414–4422.
24. Yang WT, Le-Petross HT, Macapinlac H, et al. Inflammatory breast cancer: PET/CT, MRI, mammography, and sonography findings. *Breast Cancer Res Treat* 2008;109(3):417–426.
25. Le-Petross HT, Cristofanilli M, Carkaci S, et al. MRI features of inflammatory breast cancer. *AJR Am J Roentgenol* 2011;197(4):W769–W776.
26. Girardi V, Carbognin G, Camera L, et al. Inflammatory breast carcinoma and locally advanced breast carcinoma: characterisation with MR imaging. *Radiol Med (Torino)* 2011;116(1):71–83.
27. Renz DM, Baltzer PA, Böttcher J, et al. Inflammatory breast carcinoma in magnetic resonance imaging: a comparison with locally advanced breast cancer. *Acad Radiol* 2008;15(2):209–221.
28. Uematsu T. MRI findings of inflammatory breast cancer, locally advanced breast cancer, and acute mastitis: T2-weighted images can increase the specificity of inflammatory breast cancer. *Breast Cancer* 2012;19(4):289–294.
29. Niikura N, Costelloe CM, Madewell JE, et al. FDG-PET/CT compared with conventional imaging in the detection of distant metastases of primary breast cancer. *Oncologist* 2011;16(8):1111–1119.
30. NCCN clinical practice guidelines in oncology: breast cancer. Version 2. National Comprehensive Cancer Network Web site. http://www.nccn.org/professionals/physician_gls/f_guidelines.asp. Published 2011. Accessed January 31, 2011.
31. Alberini JL, Lerebours F, Wartski M, et al. 18F-fluorodeoxyglucose positron emission tomography/computed tomography (FDG-PET/CT) imaging in the staging and prognosis of inflammatory breast cancer. *Cancer* 2009;115(21):5038–5047.
32. Baslaim MM, Bakheet SM, Bakheet R, Ezzat A, El-Foudeh M, Tulbah A. 18-Fluorodeoxyglucose-positron emission tomography in inflammatory breast cancer. *World J Surg* 2003;27(10):1099–1104.
33. Carkaci S, Macapinlac HA, Cristofanilli M, et al. Retrospective study of 18F-FDG PET/CT in the diagnosis of inflammatory breast cancer: preliminary data. *J Nucl Med* 2009;50(2):231–238.
34. Groheux D, Giacchetti S, Delord M, et al. 18F-FDG PET/CT in staging patients with locally advanced or inflammatory breast cancer: comparison to conventional staging. *J Nucl Med* 2013;54(1):5–11.
35. Walker GV, Niikura N, Yang W, et al. Pretreatment staging positron emission tomography/computed tomography in patients with inflammatory breast cancer influences radiation treatment field designs. *Int J Radiat Oncol Biol Phys* 2012;83(5):1381–1386.
36. Shin HJ, Kim HH, Ahn JH, et al. Comparison of mammography, sonography, MRI and clinical examination in patients with locally advanced or inflammatory breast cancer who underwent neoadjuvant chemotherapy. *Br J Radiol* 2011;84(1003):612–620.
37. Chen JH, Mehta RS, Nalcioğlu O, Su MY. Inflammatory breast cancer after neoadjuvant chemotherapy: can magnetic resonance imaging precisely diagnose the final pathological response? *Ann Surg Oncol* 2008;15(12):3609–3613.
38. Chen JH, Feig B, Agrawal G, et al. MRI evaluation of pathologically complete response and residual tumors in breast cancer after neoadjuvant chemotherapy. *Cancer* 2008;112(1):17–26.
39. Eisenhauer EA, Therasse P, Bogaerts J, et al. New response evaluation criteria in solid tumours: revised RECIST guideline (version 1.1). *Eur J Cancer* 2009;45(2):228–247.
40. Berriolo-Riedinger A, Touzery C, Riedinger JM, et al. [18F]FDG-PET predicts complete pathological response of breast cancer to neoadjuvant chemotherapy. *Eur J Nucl Med Mol Imaging* 2007;34(12):1915–1924.
41. Kolesnikov-Gauthier H, Vanlemmens L, Baranzelli MC, et al. Predictive value of neoadjuvant chemotherapy failure in breast cancer using FDG-PET after the first course. *Breast Cancer Res Treat* 2012;131(2):517–525.
42. Edge SB, Byrd DR, Compton CC, Fritz AG, Greene FL, Trotti A, eds. *AJCC cancer staging manual*. 7th ed. New York, NY: Springer, 2010.
43. Kell MR, Morrow M. Surgical aspects of inflammatory breast cancer. *Breast Dis* 2005–2006;22:67–73.
44. Bristol IJ, Woodward WA, Strom EA, et al. Locoregional treatment outcomes after multimodality management of inflammatory breast cancer. *Int J Radiat Oncol Biol Phys* 2008;72(2):474–484.
45. Oude Munnink TH, Nagengast WB, Brouwers AH, et al. Molecular imaging of breast cancer. *Breast* 2009;18(suppl 3):S66–S73.
46. Perez CA, Fields JN, Fracasso PM, et al. Management of locally advanced carcinoma of the breast. II. Inflammatory carcinoma. *Cancer* 1994;74(1 suppl):466–476.

What Radiologists Need to Know about Diagnosis and Treatment of Inflammatory Breast Cancer: A Multidisciplinary Approach

Eren D. Yeh, MD • Heather A. Jacene, MD • Jennifer R. Bellon, MD • Faina Nakhlis, MD • Robyn L. Birdwell, MD • Dianne Georgian-Smith, MD • Catherine S. Giess, MD • Judi Hirshfield-Bartek, RN • Beth Overmoyer, MD • Annick D. Van den Abbeele, MD

RadioGraphics 2013; 33:2003–2017 • Published online 10.1148/rg.337135503 • Content Codes: BR OI

Page 2004

Both tissue diagnosis of malignancy and clinical evidence of inflammatory disease are required to confirm the diagnosis of IBC.

Page 2005

The key feature that differentiates IBC from non-IBC LABC is the onset of symptoms. Symptoms of IBC develop within 3 months or less, whereas symptoms of non-IBC LABC typically develop over a more protracted period.

Page 2008

If a mass or biopsy target is not detected at conventional imaging, MR imaging can help identify a biopsy target to confirm the diagnosis of IBC.

Page 2012

Imaging is used to stage IBC, differentiate between curable and incurable (stage IV) disease, and help the oncologist choose the appropriate chemotherapy agent.

Page 2015

If imaging is used to noninvasively predict treatment response early during the course of therapy, more optimal and tailored management strategies for patients with IBC can be implemented.